

Six-Month Outcomes of Goniotomy Performed with a Trapezoidal Dual Blade in Combination with Cataract Surgery

Alex D Meyer¹, Delcora Huggins², Imani Nwokeji³, Lorraine M Provencher^{1,2,4}

¹Cincinnati Eye Institute, Cincinnati, OH, USA; ²University of Cincinnati, College of Medicine, Cincinnati, OH, USA; ³City College of New York (CUNY), School of Medicine, New York, NY, USA; ⁴Vance Thompson Vision, Omaha, NE, USA

Correspondence: Lorraine M Provencher, Vance Thompson Vision, 4909 S 118th St, Omaha, NE, USA, 68137, Tel +1 402 506-9970, Fax +1 402 315-9753, Email lorraine.provencher@vancethompsonvision.com

Purpose: To assess the efficacy and safety of goniotomy using a uniquely shaped trapezoidal, serrated dual blade (TDB), designed to accommodate variability in patient anatomy, in reducing intraocular pressure (IOP) or anti-glaucoma medications (AGM) in adult glaucoma patients when combined with cataract surgery.

Patients and Methods: Retrospective consecutive case series of patients with glaucoma who underwent phacoemulsification with TDB-goniotomy were included. Preoperative, intraoperative, and postoperative data were collected over 6 months. The primary outcome measure was surgical success, defined as IOP reduction $\geq 20\%$ from baseline at 6 months, and/or reduction of at least 1 AGM. Postoperative adverse events were collected as a secondary outcome measure.

Results: Sixty-five eyes of 46 patients were included with data available on 53 eyes at 6 months. Primary open-angle (38%), primary angle-closure (37%), and mixed-mechanism glaucoma (11%) were the most common diagnoses. Most cases were severe (48%) or moderate (32%) stage. At the 6-month mark, surgical success was achieved in 92% of eyes by either or both criteria. Mean preoperative IOP decreased from 18.4 mmHg (SE 0.83) to 13.0 mmHg (SE 0.37) ($p < 0.001$) at postoperative month 6. Mean AGM decreased from 2.46 (SE 0.19) preoperatively to 1.45 (SE 0.17) ($p < 0.001$). The most common postoperative complication was an IOP spike at postoperative week 1 (11%). No serious adverse events occurred related to the goniotomy.

Conclusion: TDB-goniotomy in combination with cataract surgery safely and effectively lowered IOP and reduced AGM burden in adults with various types and severities of glaucoma over 6-months of follow-up.

Plain Language Summary: There are many tools available to perform goniotomy, a popular minimally invasive glaucoma surgery, but data is lacking on many of these devices. This study sought to determine the safety and efficacy of excisional goniotomy using a uniquely shaped trapezoidal dual blade (TDB) in combination with cataract surgery for adult glaucoma patients. At 6 months, the primary outcome measure of intraocular pressure (IOP) reduction $\geq 20\%$ from baseline and/or reduction of at least 1 anti-glaucoma medication was met by 92% of eyes. Six months postoperatively, there was a statistically significant decrease in mean IOP from 18.4 mmHg to 13.0 mmHg and mean antiglaucoma medications from 2.5 to 1.5. Therefore, TDB-goniotomy in combination with cataract surgery can safely decrease IOP and/or antiglaucoma medications in a mixed population of various glaucoma types and severities.

Keywords: minimally invasive glaucoma surgery, MIGS, goniotomy, glaucoma, phacoemulsification

Introduction

Glaucoma is a leading cause of irreversible blindness globally,¹ and despite innovation, treatment remains challenging. Barriers like poor adherence, medication side effects, and invasive surgical complications have driven the development of minimally invasive glaucoma surgeries (MIGS). Excisional goniotomy is a well-established MIGS that lowers

intraocular pressure (IOP) by excision of the trabecular meshwork (TM) and can be effectively combined with cataract surgery.^{2,3} An increasing number of goniotomy tools are available, but data on these tools are lacking. This study aimed to assess the safety and efficacy of cataract surgery combined with excisional goniotomy using a uniquely shaped, serrated, trapezoidal dual blade (TDB) (TrabEx, Microsurgical Technologies, Redmond, WA), designed to accommodate variability in patient anatomy.

Materials and Methods

A retrospective chart review of patients who underwent cataract surgery with TDB-goniotomy from 2019 to 2023 at the Cincinnati Eye Institute, Cincinnati, OH by L.P. (or a supervised fellow) was performed. A de-identified data set was analyzed to protect confidentiality of protected health information (PHI). The study followed the tenants of the Declaration of Helsinki and waiver of HIPAA authorization was granted from a centralized internal review board (WCG IRB). Written consent was obtained for all patients prior to surgery. Inclusion criteria were ≥ 18 years old with any form or severity of glaucoma, which was determined by the International Classification of Diseases and Related Health Problems, Ninth Revision (ICD-9) criteria (mild stage – optic nerve abnormalities consistent with glaucoma but no visual field abnormalities; moderate stage – optic nerve abnormalities consistent with glaucoma and glaucomatous visual field abnormalities in one hemifield but not within 5 degrees of fixation; severe stage – optic nerve abnormalities consistent with glaucoma and glaucomatous visual field abnormalities in both hemifields and/or within 5 degrees of fixation; indeterminate stage – patient incapable of visual field testing or unreliable/uninterpretable visual field testing). Both eyes were included if both met eligibility criteria. Exclusion criteria were recent (within 2 months) laser trabeculoplasty (LT), prior incisional glaucoma surgery, complicated cataract surgery, or additional IOP-lowering surgery performed at the time of goniotomy, excluding goniosynechialysis (GSL).

The primary outcome measure was surgical success at postoperative month 6 (POM6), defined as IOP reduction $\geq 20\%$ from baseline and/or reduction of ≥ 1 anti-glaucoma medication (AGM). This definition has been published in a similar retrospective goniotomy study and reflects the practice of using goniotomy for IOP and/or AGM reduction.² Secondary outcomes were mean IOP reduction, mean AGM reduction, secondary procedures, and adverse events [an IOP spike greater than 10 mmHg above baseline within the first week; layered, measurable anterior chamber blood/hyphema (microhyphema, ie circulating red blood cells, was not considered an adverse event); >2 lines decrease in visual acuity]. To analyze success in terms of individual IOP goals, the preoperative and POM6 IOP control status were recorded. Eyes were “controlled” if there was no AGM escalation and IOP was within the target range.

Procedure

The single-use TDB consists of two serrated blades that start as a tip and progressively diverge along the blade. The unique shape of this blade, compared to a parallel dual blade, is intended to maximally excise TM regardless of anatomical variation, minimizing leaflets that could collapse over collector channel ostia. The serrated edges may also allow for improved cutting compared to a non-serrated blade. Goniotomy was performed for 3-clock hours prior to cataract extraction by phacoemulsification. If peripheral anterior synechiae were present, GSL was performed using the heel of the blade. Postoperatively, patients received antimicrobial prophylaxis, an anti-inflammatory drop taper, and AGMs were stopped or reduced to a single agent.

Statistical Analysis

Data were analyzed using the Generalized Estimating Equation procedure, which estimates coefficients for the generalized linear model with possible unmeasured correlation between patients, where the base reference visit is preoperative IOP or preoperative medications. A post-hoc analysis of treatment response for patients with prior laser trabeculoplasty (LT), open-angle glaucomas vs closed-angle glaucomas (including mixed mechanism), and disease severity was performed. Statistical analysis was performed with Python software. Paired data analysis for IOP control state was conducted using a McNemar’s Chi-squared test.

Results

A total of 93 eyes that underwent phaco-goniotomy during the study period were identified, but 2 were excluded for concurrent endocyclophotocoagulation, 3 for prior glaucoma surgery, and 23 for utilization of a different goniotomy blade. Sixty-five eyes (46 patients) underwent phaco-TDB goniotomy and were therefore included in the analysis, with attrition to 53 eyes at POM6. Table 1 shows study demographics. Table 2 shows changes to IOP and AGM use over the follow-up period. Aside from mean IOP at postoperative week one, there was a significant reduction in IOP and AGMs at all timepoints compared to baseline (Figure 1). Mean IOP decreased from 18.4 mmHg (SE 0.83) at baseline to 13 mmHg (SE 0.37) ($p<0.001$) at POM6. Mean AGMs decreased from 2.46 (SE 0.19) at baseline to 1.45 (SE 0.17) ($p<0.001$) at POM6. Surgical success (IOP reduction $\geq 20\%$ from baseline and/or reduction of ≥ 1 AGM) was 92% (49 of 53 eyes) at POM6. Of these successful eyes, 31 (58%) had a $\geq 20\%$ reduction in IOP, 37 (70%) had a reduction in at least 1 AGM, and 19 (36%) had both. If all eyes lost to attrition were assumed surgical failures, surgical success was 75% (49 of 65 eyes).

Table 1 Study Demographics

Patient Gender, n (%)	
Female	27 (59)
Male	19 (41)
Age (years)	
Mean (Std. Dev.)	71.1 (8.41)
Median (IQ)	72 (68–76)
Race/Ethnicity, n (%)	
White	40 (87)
African American	4 (9)
Asian	1 (2)
Hispanic or Latino	1 (2)
Eyes/Laterality, n (%)	
Left	36 (55)
Right	29 (45)
Prior ALT or SLT, n (%)	
Yes	12 (18)
No	53 (82)
Glaucoma Type, n (%)	
POAG	25 (38)
PACG	24 (37)
MMG	7 (11)
NTG	5 (8)
PXFG	2 (3)
SIG	2 (3)

(Continued)

Table 1 (Continued).

Severity, n (%)	
Severe	31 (48)
Moderate	21 (32)
Indeterminate	8 (12)
Mild	4 (6)
OHTN	1 (2)

Abbreviations: Std. Dev, standard deviation; ALT, argon laser trabeculoplasty; SLT, selective laser trabeculoplasty; POAG, primary open-angle glaucoma; PACG, primary angle-closure glaucoma; MMG, mixed-mechanism glaucoma; NTG, normal tension glaucoma; PXFG, pseudoexfoliation glaucoma; SIG, steroid-induced glaucoma; OHTN, ocular hypertension.

Table 2 IOP and Glaucoma Medications Over Time

Parameter	Preop	Day 1	Week 1	Month 1	Month 3	Month 6
Eyes (n)	65	65	65	64	54	53
Mean IOP (mmHg) (SE)	18.4 (0.83)	13.4 (0.57)*	17.8 (1.09)	14.3 (0.50)*	13.2 (0.31)*	13.0 (0.37)*
Mean IOP Reduction (mmHg)	Reference	-4.9 (0.88)	-0.5 (1.2)	-3.9 (0.85)	-5.4 (0.90)	-5.2 (0.98)
IOP Change (%)	Reference	-20.1	4.4	-15.0	-21.0	-20.0
Mean No. AGM (SE)	2.46 (0.19)	0.57 (0.09)*	0.85 (0.11)*	1.23 (0.14)*	1.22 (0.15)*	1.45 (0.17)*
Mean AGM Reduction	Reference	-1.89 (0.18)	-1.62 (0.19)	-1.22 (0.19)	-1.30 (0.21)	-1.15 (0.21)

Note: *p < 0.001.

Abbreviations: SE, standard error; AGM, antiglaucoma medications.

Of the 53 eyes that had 6 months of follow-up, 17 (32%) were controlled preoperatively (defined as: no active AGM escalation and IOP within the target range). This increased to 48 (91%) at POM6 (p<0.001). Of the 17 eyes controlled preoperatively, 15 stayed controlled at POM6, and all 15 were on fewer AGMs. Of 36 eyes uncontrolled preoperatively, 33 changed to controlled at POM6, and 29 of these 33 were on the same or fewer AGMs.

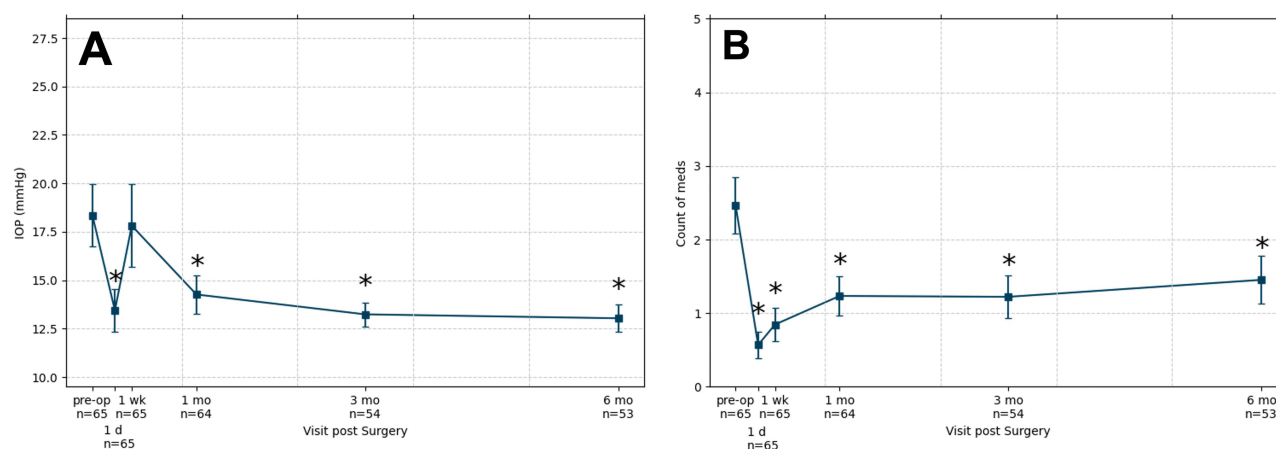


Figure 1 IOP and antiglaucoma medications over the follow up period. **(A)** Mean IOP over time. **(B)** Mean glaucoma medications over time. Bars = 95% confidence intervals, * = statistically significant compared to baseline, p<0.001.

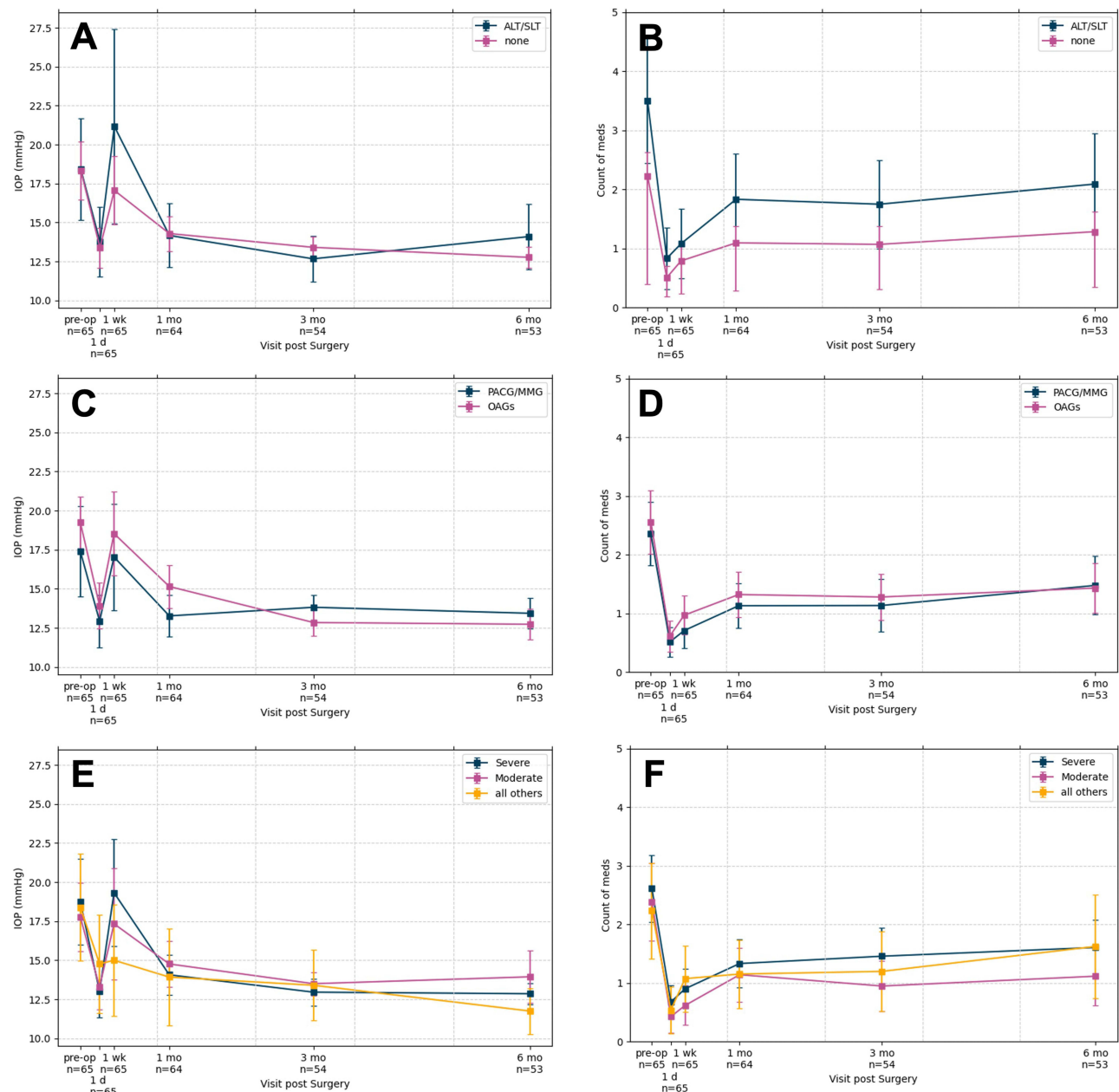


Figure 2 Results stratified: Prior LT, Open- versus Closed-angle Disease, and Severity. (A and B) Mean IOP and mean AGMs over time for patients with prior LT versus no prior LT. (C and D) Mean IOP and mean AGMs over time for patients with open-angle disease versus closed-angle disease (PACG + MMG). (E and F) Mean IOP and mean AGMs over time for patients with severe, moderate, or all other severities (mild, indeterminate, ocular hypertension). Bars = 95% confidence intervals.

Abbreviations: AGM, antiglaucoma medication; LT, laser trabeculoplasty; ALT, argon laser trabeculoplasty; SLT, selective laser trabeculoplasty; PACG, primary angle-closure glaucoma; MMG, mixed-mechanism glaucoma.

In a post-hoc analysis, eyes were stratified by prior LT, open- versus closed-angle disease, and severity. The number of eyes with prior LT was too small to determine a statistically significant difference, but there was a trend towards more postoperative AGMs in prior LT (Figure 2). There was no significant difference in IOP or AGMs based on angle-status or disease severity (Figure 2).

Adverse events included an IOP spike at postoperative week one in 7 eyes (10.8%), cyclodialysis cleft in 1 eye (1.5%), and loss of >2 lines of vision in 1 eye (1.5%) due to unrelated corneal pathology. Secondary intervention was required in 3 eyes: LT, gel microstent implantation, cyclodialysis cleft repair (via direct external transscleral cycloplexy). No eyes had a hyphema that was layering in the anterior chamber and therefore measurable.

To ensure data was not skewed by attrition, models were run with missing data, complete data only, and missing data imputed from the last value collected. There was no meaningful difference in the results between these models. Demographic and baseline data between the entry cohort and POM6 cohort were no different.

Discussion

Phaco-TDB goniotomy safely decreased IOP and AGMs in a population of various glaucoma types and severities over 6 months follow-up. The blade is intended to maximally excise TM, as anatomical variability exists between patients, within a single patient, and in open- versus closed-angle disease.^{4–6} A common critique of incisional goniotomy is the probability of residual leaflets and/or unwanted incision to the posterior wall of Schlemm canal. Hence, specialized blades with a blunt footplate and wider TM-facing excisional surface have been popularized, most notably the Kahook Dual Blade (KDB).

Extensive literature exists on phaco-KDB goniotomy, with mean IOP reductions of 11–34%, and mean AGM reductions of 11–79%.⁷ Our results were comparable with a mean IOP reduction of 20% and mean AGM reduction of 41%. In a phaco-KDB study by Sieck et al, using an identical definition of success, POM6 success rates were 74%.² Conservatively, if all of the eyes lost to attrition in our study are assumed to be surgical failures, success was 75%. Hence, the results reported herein seem, at minimum, comparable to phaco-KDB goniotomy.

Most MIGS studies include predominantly mild-moderate glaucoma patients, but this cohort was skewed towards severe disease, which is helpful for real-world application. Sieck et al and Salimi et al, with 26% and 37% severe glaucoma, respectively, reported no difference in response to phaco-KDB goniotomy based on severity.^{2,8} Our study also included a large proportion of angle-closure, but there was no significant difference in IOP or AGM response compared to eyes with open-angles. These results are unsurprising, as phaco-goniotomy (\pm GSL) for angle-closure disease has been shown to be efficacious.^{9,10}

Another study strength is the target-based analysis with a significant increase in eyes deemed controlled after phaco-TDB goniotomy and a large proportion on the same or fewer AGMs. Success based on individualized IOP targets reflects clinical practice and overcomes some of the limitations in defining success by IOP and AGM reduction alone.

Safety was favorable. The rate of IOP spikes (11%) was consistent with other studies (3%–33%).^{2,7,8,11} Hyphema, which is common after goniotomy,^{2,8,12,13} was not observed in this study. Less hyphema may be related to the sharp/cutting blade (vs shearing)¹⁴ or from reduced early postoperative blood reflux, as AGMs were stopped/reduced post-operatively. Additionally, our study only counted measurable layered hyphemas as an adverse event, as microhyphema is extremely common and typically clinically insignificant with MIGS.

The retrospective nature, lack of control group, and shorter follow-up were limitations. A large proportion of patients were white, limiting generalizability. Additionally, all eyes underwent combined phaco-TDB goniotomy. Phacoemulsification has well-established IOP lowering (12% at 6 months) and AGM reduction (0.57 medications),¹⁵ but the results reported herein exceed what is expected from phacoemulsification alone.

In conclusion, phaco-TDB goniotomy using a serrated trapezoidal dual blade (TrabEx) safely decreased IOP and AGM use over a 6-month follow-up period in a mixed population of various glaucoma types and severities and was effective at moving patients to their individual clinical target IOP range. Prospective and longer-term studies are warranted.

Acknowledgments

The authors thank Renate Gorham (Ektropia Solutions, LLC) for assistance with the statistical analysis.

Disclosure

Dr Lorraine Provencher reports grants, personal fees from Microsurgical Technologies, AbbVie, Alcon, New World Medical, Elios, RxSight, Glaukos, Vialase, and advisory from Radius, during the conduct of the study. The authors report no other conflicts of interest in this work.

References

1. Blindness GBD, Vision Impairment C, Briant PS, Vision Loss Expert Group of the Global Burden of Disease S. Causes of blindness and vision impairment in 2020 and trends over 30 years, and prevalence of avoidable blindness in relation to VISION 2020: the right to sight: an analysis for the global burden of disease study. *Lancet Glob Health*. 2021;9(2):e144–e160. doi:10.1016/S2214-109X(20)30489-7
2. Sieck EG, Epstein RS, Kennedy JB, et al. Outcomes of kahook dual blade goniotomy with and without phacoemulsification cataract extraction. *Ophthalmol Glaucoma*. 2018;1(1):75–81. doi:10.1016/j.ogla.2018.06.006
3. Wakil SM, Birnbaum F, Vu DM, McBurney-Lin S, ElMallah MK, Tseng H. Efficacy and safety of a single-use dual blade goniotomy: 18-month results. *J Cataract Refract Surg*. 2020;46(10):1408–1415. doi:10.1097/j.jcrs.0000000000000263
4. Choi W, Lee MW, Kang HG, et al. Comparison of the trabecular meshwork length between open and closed angle with evaluation of the scleral spur location. *Sci Rep*. 2019;9(1):6857. doi:10.1038/s41598-019-43315-2
5. Tun TA, Baskaran M, Zheng C, et al. Assessment of trabecular meshwork width using swept source optical coherence tomography. *Graefes Arch Clin Exp Ophthalmol*. 2013;251(6):1587–1592. doi:10.1007/s00417-013-2285-8
6. Huang AS, Francis BA, Weinreb RN. Structural and functional imaging of aqueous humour outflow: a review. *Clin Exp Ophthalmol*. 2018;46(2):158–168. doi:10.1111/ceo.13064
7. Dorairaj S, Radcliffe NM, Grover DS, Brubaker JW, Williamson BK. A review of excisional goniotomy performed with the kahook dual blade for glaucoma management. *J Curr Glaucoma Pract*. 2022;16(1):59–64. doi:10.5005/jp-journals-10078-1352
8. Salimi A, Kasner O, Schendel S, et al. Outcomes and risk factors for kahook dual blade excisional goniotomy with concomitant phacoemulsification: a multicentre Canadian study. *Can J Ophthalmol*. 2023. doi:10.1016/j.jcjo.2023.08.004
9. Dorairaj S, Tam MD, Balasubramani GK. Two-year clinical outcomes of combined phacoemulsification, goniosynechialysis, and excisional goniotomy for angle-closure glaucoma. *Asia Pac J Ophthalmol*. 2020;10(2):183–187. doi:10.1097/APO.0000000000000321
10. Sener H, Gulmez Sevim D, Evereklioglu C, et al. Efficacy and safety of different types of intraocular pressure-lowering surgeries in patients with primary angle closure (PAC) or PAC glaucoma: systematic review and network meta-analysis of randomized clinical trials. *Semin Ophthalmol*. 2023;1–10. doi:10.1080/08820538.2023.2223292
11. Greenwood MD, Seibold LK, Radcliffe NM, et al. Goniotomy with a single-use dual blade: short-term results. *J Cataract Refract Surg*. 2017;43(9):1197–1201. doi:10.1016/j.jcrs.2017.06.046
12. Dorairaj SK, Kahook MY, Williamson BK, Seibold LK, ElMallah MK, Singh IP. A multicenter retrospective comparison of goniotomy versus trabecular bypass device implantation in glaucoma patients undergoing cataract extraction. *Clin Ophthalmol*. 2018;12:791–797. doi:10.2147/OPTH.S158403
13. Aoki R, Hirooka K, Goda E, et al. Comparison of surgical outcomes between microhook ab interno trabeculotomy and goniotomy with the kahook dual blade in combination with phacoemulsification: a retrospective, comparative case series. *Adv Ther*. 2021;38(1):329–336. doi:10.1007/s12325-020-01543-3
14. Ammar DA, Seibold LK, Kahook MY. Preclinical investigation of goniotomy using four different techniques. *Clin Ophthalmol*. 2020;14:3519–3525. doi:10.2147/OPTH.S281811
15. Armstrong JJ, Wasiuta T, Kiatos E, Malvankar-Mehta M, Hutnik CML. The effects of phacoemulsification on intraocular pressure and topical medication use in patients with glaucoma: a systematic review and meta-analysis of 3-year data. *J Glaucoma*. 2017;26(6):511–522. doi:10.1097/IJG.0000000000000643

Clinical Ophthalmology

Dovepress

Publish your work in this journal

Clinical Ophthalmology is an international, peer-reviewed journal covering all subspecialties within ophthalmology. Key topics include: Optometry; Visual science; Pharmacology and drug therapy in eye diseases; Basic Sciences; Primary and Secondary eye care; Patient Safety and Quality of Care Improvements. This journal is indexed on PubMed Central and CAS, and is the official journal of The Society of Clinical Ophthalmology (SCO). The manuscript management system is completely online and includes a very quick and fair peer-review system, which is all easy to use. Visit <http://www.dovepress.com/testimonials.php> to read real quotes from published authors.

Submit your manuscript here: <https://www.dovepress.com/clinical-ophthalmology-journal>