

# A Case Report of Invasive *Klebsiella pneumoniae* Liver Abscess Syndrome Treated with Ceftazidime-Avibactam in Combination with Meropenem

Mengying Yang, Baogui Wang

Department of Infectious Disease, Fuyang People's Hospital Affiliated to Anhui Medical University, Fuyang, Anhui, 236000, People's Republic of China

Correspondence: Baogui Wang, Email wangbaogui99@163.com

**Introduction:** The emergence of carbapenem-resistant hypervirulent *Klebsiella pneumoniae* (CR-hvKP) presents a formidable challenge to public health and clinical medicine. This dual phenotype of hypervirulence and multi-drug resistance often complicates treatment options, leaving patients with limited antimicrobial regimens. Consequently, adverse clinical outcomes and high mortality rates are common. Ceftazidime-avibactam (CAZ-AVI) is recognized globally as a critical option for treating infections caused by resistant gram-negative bacteria.

**Case Report:** We present a case of invasive *Klebsiella pneumoniae* liver abscess syndrome caused by a CR-hvKP infection. The patient exhibited a bloodstream infection, lung and liver abscesses, and suppurative meningitis, eventually developing a brain abscess. Treatment with a combination of meropenem and CAZ-AVI led to a favorable clinical outcome.

**Conclusion:** This case report indicates that combining CAZ-AVI with an antimicrobial agent that is in vitro non-susceptible (carbapenems in this case) is safe and effective for treating severe, multi-site infections caused by CR-hvKP, including central nervous system infections. This case serves as a clinical reference for managing similar patients in practice.

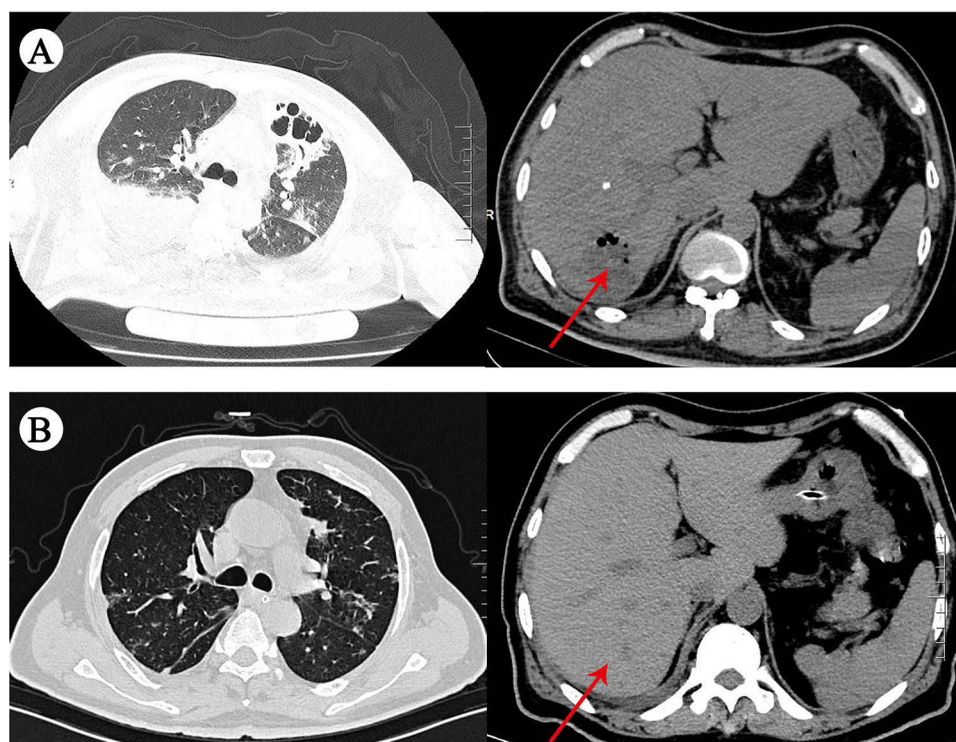
**Keywords:** ceftazidime-avibactam, drug resistance, *Klebsiella pneumoniae*, next-generation sequencing

## Introduction

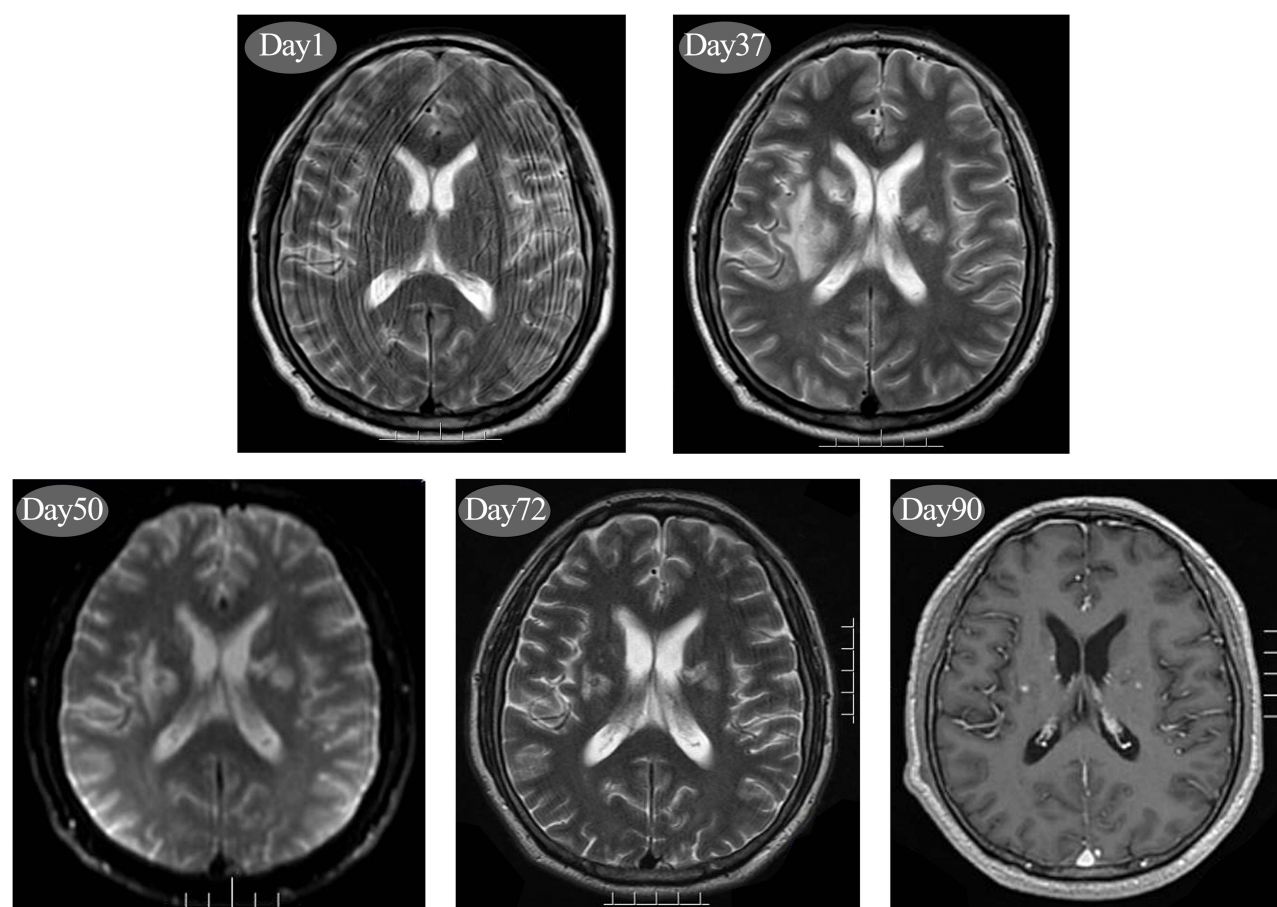
Carbapenem-resistant hypervirulent *Klebsiella pneumoniae* (CR-hvKP) infections present a significant challenge for clinicians due to the limited availability of effective therapeutic drugs, often resulting in adverse outcomes and high mortality rates. The Centers for Disease Control and Prevention in the United States have identified CR-hvKP as an urgent threat.<sup>1</sup> China is considered the main endemic region for CR-hvKP, reporting the highest number of cases globally. In this report, we describe a case of invasive *Klebsiella pneumoniae* liver abscess syndrome caused by a CR-hvKP infection. The patient exhibited a bloodstream infection, liver and lung abscesses, and purulent meningitis, eventually developing a brain abscess. Following treatment with a combination of meropenem and ceftazidime-avibactam (CAZ-AVI), the patient achieved a favorable clinical outcome.

## Case Report

A 49-year-old male with a history of diabetes was admitted to the intensive care unit due to abdominal pain and a fever lasting one week, followed by a coma that persisted for 10 hours. Computed tomography (CT) scans revealed infectious lesions in both lungs and a low-density lesion in the right lobe of the liver (Figure 1). Brain magnetic resonance imaging (MRI) showed patchy long T1 and T2 signals in the bilateral basal ganglia, corpus callosum semioval region, genu, and splenium of the corpus callosum, with high signals on diffusion-weighted imaging (Figure 2). Blood tests indicated a white blood cell count of  $27.20 \times 10^9/L$ , procalcitonin of 31.52 ng/mL, and C-reactive protein of 351.00 mg/L. Blood



**Figure 1** Comparative changes in pulmonary infection (A) and liver abscess lesions (B) before and after treatment. The arrows in Figure 1 represent the changes of liver abscess lesions before and after treatment.



**Figure 2** Changes in intracranial lesions on cranial MRI at various time points during the disease (days 1, 37, 50, 72, and 90, respectively). MRI, magnetic resonance imaging.

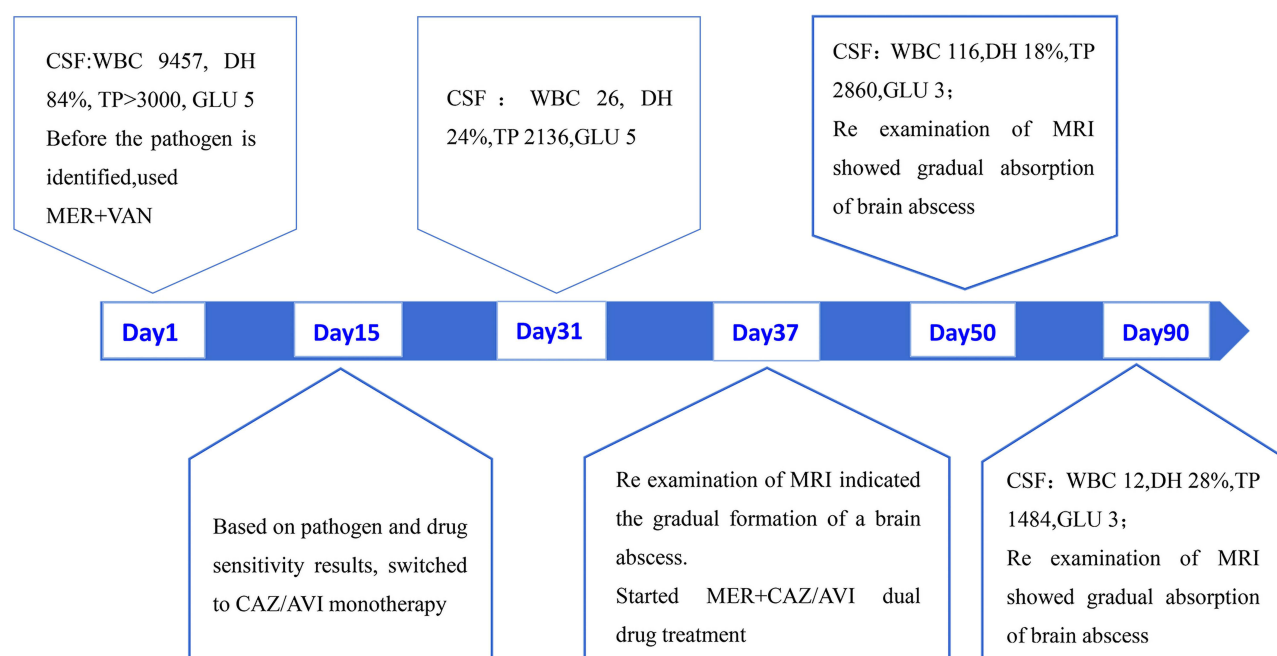
cultures identified sensitive *Klebsiella pneumoniae* (extended-spectrum  $\beta$ -lactamase-negative). Cerebrospinal fluid (CSF) analysis revealed glucose levels of 5.0 mmol/L, white blood cells of  $9457.00 \times 10^6/L$ , 84% polymorphonuclear cells, and protein levels exceeding 3000.0 mg/L. The CSF bacterial culture was negative. CSF metagenomics next-generation sequencing (mNGS) detected *Klebsiella pneumoniae* with 6638 sequence reads and virulence genes, including *iutA* (936 reads), *iucA* (586 reads), *iucD* (443 reads), *iroB* (242 reads), *iucC* (159 reads), *iucB* (148 reads), *ompA* (98 reads), *rmpA2* (21 reads), and *rmpA* (17 reads). Resistance genes identified included *SHV-217* (22 reads), indicating resistance to carbapenems, cephalosporins, and penicillins. The liver abscess pus culture was negative. Bronchoalveolar lavage fluid targeted NGS (tNGS) identified *Klebsiella pneumoniae* with 62,239 sequence reads. The resistance gene detection revealed the presence of the carbapenemase gene *blaKPC*, and the KPC type of this case is carbapenemase gene - Class A carbapenemase gene. *Klebsiella pneumoniae* carbapenemases (KPCs) are  $\beta$ -lactamases commonly produced by *blaKPC* gene-harboring bacteria of the Enterobacteriaceae family, including *Klebsiella pneumoniae*, *Escherichia coli* and *Enterobacter* spp and that are sporadically found in non-fermenting bacteria.<sup>2</sup> This gene encodes a class A serine  $\beta$ -lactamase (class A SBL), which hydrolyzes the  $\beta$ -lactam ring of antibiotics, conferring resistance to most  $\beta$ -lactams, including carbapenems. The bronchoalveolar lavage fluid bacterial culture confirmed multi-drug-resistant *Klebsiella pneumoniae*, resistant to third-generation cephalosporins and carbapenems but sensitive to CAZ-AVI and amikacin. And the genetic analysis showed that the strain isolated of bronchoalveolar lavage fluid belonged to sequence type 11 (ST11) and serotype K2, ST11-K2. The patient was diagnosed with CR-hvKP infection, manifesting as invasive *Klebsiella pneumoniae* liver abscess syndrome.

Before obtaining pathogen and drug sensitivity results, we initially administered intravenous meropenem combined with vancomycin. After receiving definitive pathogen and drug sensitivity results, we switched to intravenous CAZ-AVI (2.5 g/dose, three times daily) monotherapy on day 15 of the disease course. Following this treatment, the temperature of the patient gradually stabilized, his consciousness cleared, and the ventilator was removed. The patient was then transferred from the ICU to a general ward for continued care. Follow-up CT scans showed significant absorption of the pulmonary infection and liver abscess lesions (Figure 1). Repeat CSF analysis revealed glucose levels of 5.00 mmol/L, white blood cells of  $26.00 \times 10^6/L$ , 24% polymorphonuclear cells, and a negative CSF bacterial culture. Repeat CSF mNGS detected *Klebsiella pneumoniae* with only two sequence reads. After treatment, the patient experienced no fever, headache, abdominal pain, cough, or other symptoms, showing both clinical and radiographic improvement. CAZ-AVI monotherapy was continued. However, due to unsatisfactory control of intracranial infection lesions on brain MRI (Figure 2) and the gradual formation of brain abscesses, on day 37 of the disease course, we switched the treatment to a combination of intravenous meropenem (2.0 g/dose, three times daily) and CAZ-AVI (2.5 g/dose, three times daily). The total treatment duration for this patient is 90 days. Repeat CSF indicators showed improvement compared to previous results, and follow-up brain MRI indicated absorption and reduction of brain abscesses (Figure 2). Currently, the general condition of the patient is good, and he is undergoing regular follow-up in our department. The changes in the CSF of the patient and the treatment course are depicted in Figure 3.

## Discussion

The acquisition of carbapenem resistance genes by hypervirulent *Klebsiella pneumoniae* has led to the emergence of CR-hvKP, presenting a significant challenge to clinical anti-infective treatment. This dual phenotype of hypervirulence and multi-drug resistance often complicates therapy, leaving patients with limited antimicrobial regimens and leading to unfavorable clinical outcomes and high mortality rates. Early detection of pathogenicity and drug resistance is crucial for selecting appropriate antimicrobial agents and improving the prognosis of the patient. China is recognized as the primary endemic region for CR-hvKP, reporting the highest number of cases globally. Epidemiological surveys of carbapenem-resistant Enterobacteriaceae in China have shown that the predominant enzyme genotype carried by *Klebsiella pneumoniae* is KPC-2, accounting for 84% of cases, followed by NDM-1, which accounts for 10%. Additionally, various subtypes of enzyme genotypes, such as KPC-12 and NDM-5, have been isolated in China.<sup>3</sup>

CAZ-AVI is a combination of the third-generation cephalosporin ceftazidime and the novel non- $\beta$ -lactam  $\beta$ -lactamase inhibitor avibactam. Avibactam can inhibit class A, C, and some class D enzymes, providing CAZ-AVI with antimicrobial activity against most Enterobacteriaceae and high sensitivity to carbapenem-resistant Enterobacteriaceae carrying



**Figure 3** Illustration of changes in the CSF, cranial MRI findings, and treatment course of the patient.

**Abbreviations:** CSF, cerebrospinal fluid; WBC, white blood cells; DH, multiple nuclear cells; TP, protein; GLU, glucose; MER, Meropenem; VAN, Vancomycin; CAZ/AVI, ceftazidime/avibactam.

the *KPC-2* genotype.<sup>4,5</sup> Multiple international guidelines consistently recommend CAZ-AVI as a first-line treatment for resistant gram-negative bacterial infections.<sup>6,7</sup> A meta-analysis of the efficacy and safety of CAZ-AVI in treating carbapenem-resistant *Enterobacteriaceae* bloodstream infections, including data up to 2021, showed that the 30-day mortality rate in the CAZ-AVI group was significantly lower than in other regimens and polymyxin-based regimens.<sup>8</sup> Notably, although in vitro antimicrobial susceptibility results indicated resistance to carbapenems, we chose CAZ-AVI combined with meropenem because the patient developed multiple brain abscesses during the illness. Meropenem is a classic drug for treating central nervous system (CNS) infections due to its good blood-brain barrier permeability. Currently, data on the clinical efficacy of CAZ-AVI in treating CNS infections is limited. However, the largest study to date on CAZ-AVI-based combination therapy for CNS infections caused by CR-hvKP has confirmed its effectiveness.<sup>9</sup> Previous retrospective cohort studies have also shown that CAZ-AVI combined with in vitro non-sensitive antimicrobial drugs (such as carbapenems, fosfomycin, and tetracyclines) significantly reduces mortality risk in critically ill patients with CR-hvKP infections.<sup>10</sup> This case report suggests that CAZ-AVI combined with in vitro non-sensitive antimicrobial drugs (carbapenems in this case) is safe and effective for treating severe multi-site infections caused by CR-hvKP, including CNS infections. It provides a clinical reference for the treatment of similar patients.

## Consent to Participate

The patient has given both verbal and written consent to the examination.

## Patient Consent for Publication

Written informed consent was obtained from the patient for publication of this case report and the images.

## Data Sharing Statement

All data generated or analyzed during this study are included in this published article.



## Ethical Approval

No specific ethics committee approval was required for this study.

## Author Contributions

All authors made a significant contribution to the work reported, whether that is in the conception, study design, execution, acquisition of data, analysis and interpretation, or in all these areas; took part in drafting, revising or critically reviewing the article; gave final approval of the version to be published; have agreed on the journal to which the article has been submitted; and agree to be accountable for all aspects of the work.

## Funding

There is no funding to report.

## Disclosure

We declare no competing interests.

## References

1. CDC. Antibiotic Resistance Threats 2013. Available from: [https://www.cdc.gov/drugresistance/biggest\\_threats.html](https://www.cdc.gov/drugresistance/biggest_threats.html). Accessed September 23, 2024.
2. Munoz-Price LS, Poirel L, Bonomo RA, et al. Clinical epidemiology of the global expansion of *Klebsiella pneumoniae* carbapenemases. *Lancet Infect Dis*. 2013;13(9):785–796. doi:10.1016/S1473-3099(13)70190-7
3. Zhang Y, Wang Q, Yin Y, et al. Epidemiology of carbapenem-resistant Enterobacteriaceae infections: report from the China CRE network. *Antimicrob Agents Chemother*. 2018;62(2). doi:10.1128/aac.01882-17
4. Palica K, Voráčová M, Skagseth S, et al. Metallo- $\beta$ -lactamase inhibitor phosphonamidate monoesters. *ACS Omega*. 2022;7(5):4550–4562. doi:10.1021/acsomega.1c06527
5. Papp-Wallace KM. The latest advances in  $\beta$ -lactam/ $\beta$ -lactamase inhibitor combinations for the treatment of gram-negative bacterial infections. *Expert Opin Pharmacother*. 2019;20(17):2169–2184. doi:10.1080/14656566.2019.1660772
6. Mazuski JE, Tessier JM, May AK, et al. The surgical infection society revised guidelines on the management of intra-abdominal infection. *Surg Infect*. 2017;18(1):1–76. doi:10.1089/sur.2016.261
7. Hawkey PM. The 2017 Garrod lecture: genes, guts and globalization. *J Antimicrob Chemother*. 2018;73(10):2589–2600. doi:10.1093/jac/dky277
8. Chen Y, Huang HB, Peng JM, et al. Efficacy and safety of ceftazidime-avibactam for the treatment of carbapenem-resistant enterobacterales bloodstream infection: a systematic review and meta-analysis. *Microbiol Spectr*. 2022;10(2):e0260321. doi:10.1128/spectrum.02603-21
9. Zhao X, Li S, Zhang Y, et al. Ceftazidime-avibactam-based combination therapy for hospital-acquired central nervous system infections caused by carbapenem-resistant *Klebsiella pneumoniae*. *Int J Antimicrob Agents*. 2023;61(5):106777. doi:10.1016/j.ijantimicag.2023.106777
10. Zheng G, Zhang J, Wang B, et al. Ceftazidime-avibactam in combination with in vitro non-susceptible antimicrobials versus ceftazidime-avibactam in monotherapy in critically ill patients with carbapenem-resistant *Klebsiella pneumoniae* infection: a retrospective cohort study. *Infect Dis Ther*. 2021;10(3):1699–1713. doi:10.1007/s40121-021-00479-7

Infection and Drug Resistance

Dovepress

### Publish your work in this journal

Infection and Drug Resistance is an international, peer-reviewed open-access journal that focuses on the optimal treatment of infection (bacterial, fungal and viral) and the development and institution of preventive strategies to minimize the development and spread of resistance. The journal is specifically concerned with the epidemiology of antibiotic resistance and the mechanisms of resistance development and diffusion in both hospitals and the community. The manuscript management system is completely online and includes a very quick and fair peer-review system, which is all easy to use. Visit <http://www.dovepress.com/testimonials.php> to read real quotes from published authors.

Submit your manuscript here: <https://www.dovepress.com/infection-and-drug-resistance-journal>