

A Coronary-Friendly Device Mitigating Risk of Coronary Obstruction in Transcatheter Aortic Valve Replacement

Yuntao Lu^{1,2,*}, Minyan Yin^{3,4,*}, Ye Yang^{1,2,*}, Wenshuo Wang^{1,2}, Lili Dong⁵, Xue Yang^{3,4}, Chunsheng Wang^{1,2}, Xiaolin Wang^{3,4}, Jinmiao Chen^{1,2}, Lai Wei^{1,2}

¹Department of Cardiovascular Surgery, Zhongshan Hospital, Fudan University, Shanghai, People's Republic of China; ²Shanghai Engineering Research Center of Heart Valve, Shanghai, People's Republic of China; ³Shanghai Institute of Medical Imaging, Shanghai, People's Republic of China; ⁴Department of Radiology, Zhongshan Hospital, Fudan University, Shanghai, People's Republic of China; ⁵Department of Echocardiography, Zhongshan Hospital, Fudan University, Shanghai, People's Republic of China

*These authors contributed equally to this work

Correspondence: Lai Wei; Jinmiao Chen, Department of Cardiovascular Surgery, Zhongshan Hospital, Fudan University, Shanghai, 200032, People's Republic of China, Tel +86 021 64041990, Email wei.lai@zs-hospital.sh.cn; chen.jinmiao@zs-hospital.sh.cn

Purpose: Transcatheter aortic valve replacement (TAVR) induced coronary artery obstruction (CAO) is a rare but devastating complication. Current preventive strategies need additional procedures and may be associated with adverse events. This study aimed to evaluate the early safety and efficacy of stand-alone TAVR using the J-Valve (Jianshi JieCheng Medical Technology Co. Ltd, Shanghai, China) in patients at potential high risk for CAO.

Patients and Methods: CAO was defined as coronary ostia obstruction requiring intervention. Patients at potential high risk for CAO were identified retrospectively from 673 consecutive patients who underwent TAVR from January 2015 to July 2021 at Zhongshan Hospital, Fudan University. Procedural results and early outcomes were evaluated according to Valve Academic Research Consortium-3 definitions.

Results: A total of 20 consecutive patients (age 72 ± 9 years; 85% female;) were included. The Society of Thoracic Surgeons-Predicted Risk of Mortality was 5% (interquartile range, 4 to 10%). All patients (100%) had at least 2 classical risk factors for CAO by pre-procedural computed tomography analysis, and 90% patients had native aortic valve diseases. TAVR was successful in 95% of cases, with only 1 patient requiring second device implantation. Early safety at 30 days was achieved in all cases without death. All patients were free from CAO, stroke or emergency reintervention. Post-procedural mean aortic valve gradient was 7 (interquartile range, 4, 12) mmHg, and none/trace or mild aortic regurgitation was present in all patients.

Conclusion: Stand-alone TAVR using the J-Valve may mitigate the risk of TAVR-induced CAO.

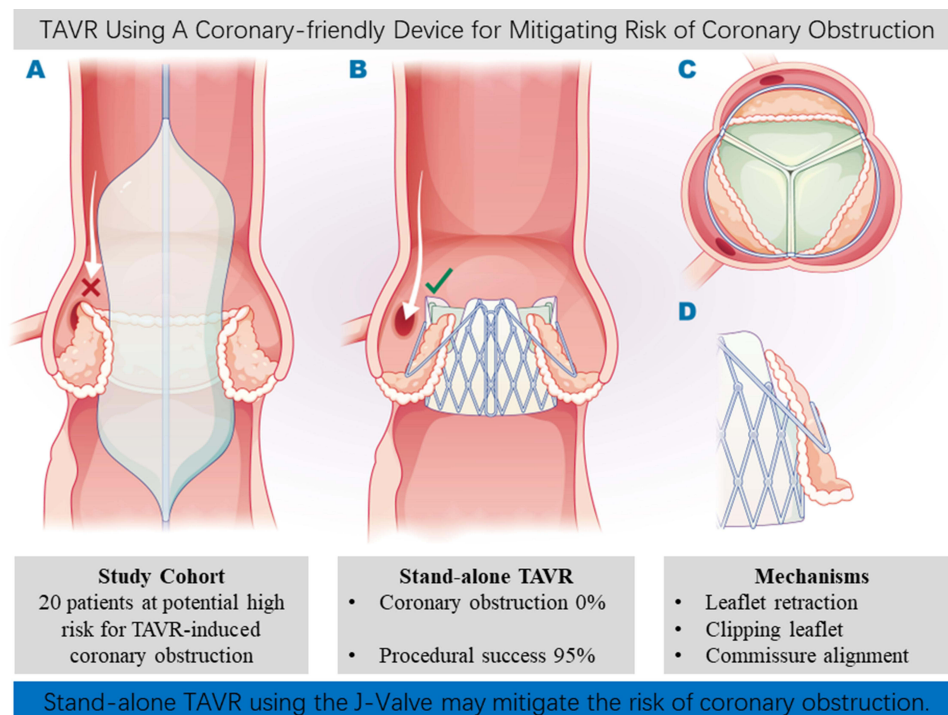
Keywords: TAVR, coronary artery obstruction, aortic regurgitation, aortic stenosis, structural heart disease

Introduction

Coronary artery obstruction (CAO) in transcatheter aortic valve replacement (TAVR) or transcatheter aortic valve-in-valve implantation (TAVIV) is caused by the displacement of the diseased leaflet (native valve or bioprostheses) toward the coronary ostia and/or sinotubular junction (STJ) by the implanted transcatheter heart valve (THV). It is a rare complication (incidence < 1% in TAVR, \approx 3% in TAVIV); however, it is likely to be underestimated, as many patients are excluded from TAVR due to potential CAO risk.¹⁻³ TAVR-induced CAO is devastating because the 30-day mortality rate is 52.9%.³ Risk factors for CAO during TAVR include but not limited to female, low-lying coronary ostia, narrow sinus of Valsalva, bioprostheses with externally mounted leaflets and stentless surgical valve.^{1,3}

Surgical aortic valve replacement is the standard treatment for patients at high risk of TAVR-induced CAO. Additional interventions may be useful, including coronary protection with pre-emptive wiring and stenting (regular

Graphical Abstract



stent and chimney technique)^{4,5} and bioprosthetic or native aortic scallop intentional laceration to prevent iatrogenic coronary artery obstruction (BASILICA).^{6,7} Although both techniques have the potential to prevent CAO in selected patients, they are also associated with the risk of serious complications, such as stent failure and stroke.⁸

J-Valve (Jianshi JieCheng Medical Technology Co, Ltd, Shanghai, China) is a self-expanding, low-profile transapical heart valve. Previous studies have reported the feasibility of the J-Valve for treatment in aortic regurgitation and/or stenosis, and the mid-term outcomes were promising.^{9–11} J-Valve was reported to use as a new option for patients at high risk for CAO in a valve-in-valve procedure.¹² A previous ex vivo study demonstrated that the J-Valve could retract and secure surgical heart valve leaflets, which could reduce the risk of CAO in a laboratory setting.¹³ However, there are limited data on the use of this THV to treat patients at high risk for CAO. This study aimed to evaluate the early safety and efficacy of TAVR using the J-Valve in treating patients at potential high risk for TAVR-induced CAO.

Methods

Study Population

This retrospective cohort study included 673 consecutive patients who underwent TAVR for severe symptomatic native aortic diseases or bioprosthetic dysfunction at our center from January 2015 to July 2021. All cases were reviewed manually to determine eligibility. The referred cardiologists were contacted whenever additional information was required. Before August 2017, all patients were evaluated by a multidisciplinary heart team as having high surgical risk scores and/or severe comorbidities that precluded surgical aortic valve replacement. However, due to updated guideline,¹⁴ the assessment criteria after August 2017 were adjusted to include patients with at least intermediate surgical risk scores and/or severe comorbidities.

Prediction of TAVR-induced CAO remains difficult with relatively low specificity. In this study, patients at potential high risk for CAO were identified according to previous study,⁸ based on a comprehensive analysis of aortic root anatomy (including but not limited to coronary ostium height, sinus width, STJ height and diameter, leaflets length and

thickness, virtual transcatheter heart valve to coronary distance (VTC), virtual transcatheter heart valve to STJ (bioprosthetic valve only) and calcification and bioprosthetic features.

Patients were excluded for reasons including bicuspid aortic valve, quadricuspid aortic valve, functional coronary bypass grafts, poor imaging quality, and the use of other TAVR devices. The final cohort included two parts: 1) patients who developed coronary obstruction after the device implantation; 2) patients who were identified as high risk for CAO by preprocedural multislice computed tomography (MSCT) analysis. The patient selection process is shown in Figure 1. The Ethics Committee of the Zhongshan Hospital, Fudan University approved this study (B2021-658, October 6, 2021) with waiver of informed consent due to the nature of retrospective research where the data being analyzed is completely anonymized. This study complies with the Declaration of Helsinki. Patient data confidentiality was rigorously upheld throughout the study.

Imaging

Transthoracic echocardiograms were performed at baseline and 30 days after implantation. Intraoperative transesophageal echocardiograms were performed. All patients underwent contrast-enhanced electro-cardiogram-gated MSCT scans at baseline. Two radiologists (X.Y. and M.Y.) analyzed the images following recent guideline using the dedicated 4-dimensional CT software, 3mensio Structural Heart version 10.2 (Pie Medical Imaging, Maastricht, The Netherlands).¹⁵ Postoperative three-dimensional reconstruction was using Vitrea software version 6.5.3 (Vital Images Incorporation, Minnetonka, Minnesota, USA). The VTC was measured using the Vancouver method.¹⁶ It is worth noting that this study identified patients at high risk for CAO using mainstream TAVR devices. Therefore, Sapien 3 (Edwards Lifesciences Inc., Irvine, CA, USA) was simulated rather than J-Valve by implanting a virtual valve cylinder and measuring the distance to the coronary ostia along the short and long axes. The diameter of the virtual valve cylinder was according to the user's manual of Sapien 3 (20, 23, 26 and 29 mm) or the Valve-in-Valve app by Vinayak Bapat.¹⁷

Definitions

CAO was defined as coronary ostia obstruction requiring intervention, as evidenced by hemodynamics, echocardiography, angiography, electrocardiogram and cardiac biomarkers. All clinical events were defined according to the Valve Academic Research Consortium-3 (VARC-3) criteria.¹⁸ The efficacy endpoint was procedure success, measured at the exit from the operating room, which required all the following: successful TAVR device implantation, absence of procedural mortality, absence of CAO, and freedom from second TAVR device implantation, emergency cardiac surgery

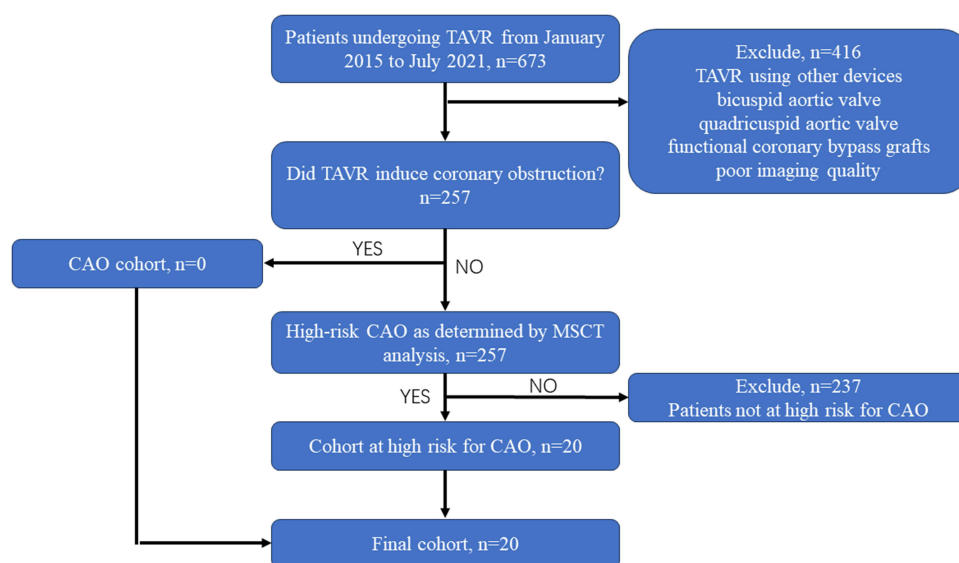


Figure 1 Flowchart of patient selection process.

Abbreviations: TAVR, transcatheter aortic valve replacement; CAO, coronary artery obstruction.

or reintervention related to the TAVR procedure. The early safety endpoint was freedom from major adverse clinical events according to VARC-3 criteria at 30 days, which is a composite of all-cause mortality, CAO, all stroke, life-threatening bleeding, acute kidney injury (stage 3 or 4), major vascular complications, and valve-related dysfunction requiring repeat procedure. Other clinical endpoints, including major cardiac structural complications, implantation of a new permanent pacemaker, cardiac readmission and echocardiographic hemodynamics parameters at 30-days, were also evaluated.

Device and TAVR

The J-Valve is a self-expanding transcatheter heart valve with a unique 2-piece structure consisting of 3 “U-shape” clasps and a crown-like frame connected to three stitches (Figure 2). The 3 clasps can be individually positioned in 3 aortic sinuses to fix the aortic valve leaflets and align the commissures of the device with commissures of the aortic valve. The bioprosthetic valve is a porcine valve supported by a self-expanding nitinol structure of different sizes: external diameters of 21, 23, 25, 27, and 29 mm. The 27F delivery catheter was crimped with valves measuring 21, 23, and 25 mm, while the 33F catheter was crimped with valves measuring 27 and 29 mm. The transcatheter TAVR technique using the J-Valve (Figure 3) has been described previously.^{10,11} Aortography was performed after device implantation to evaluate the intraoperative CAO, paravalvular leakage, and malposition.

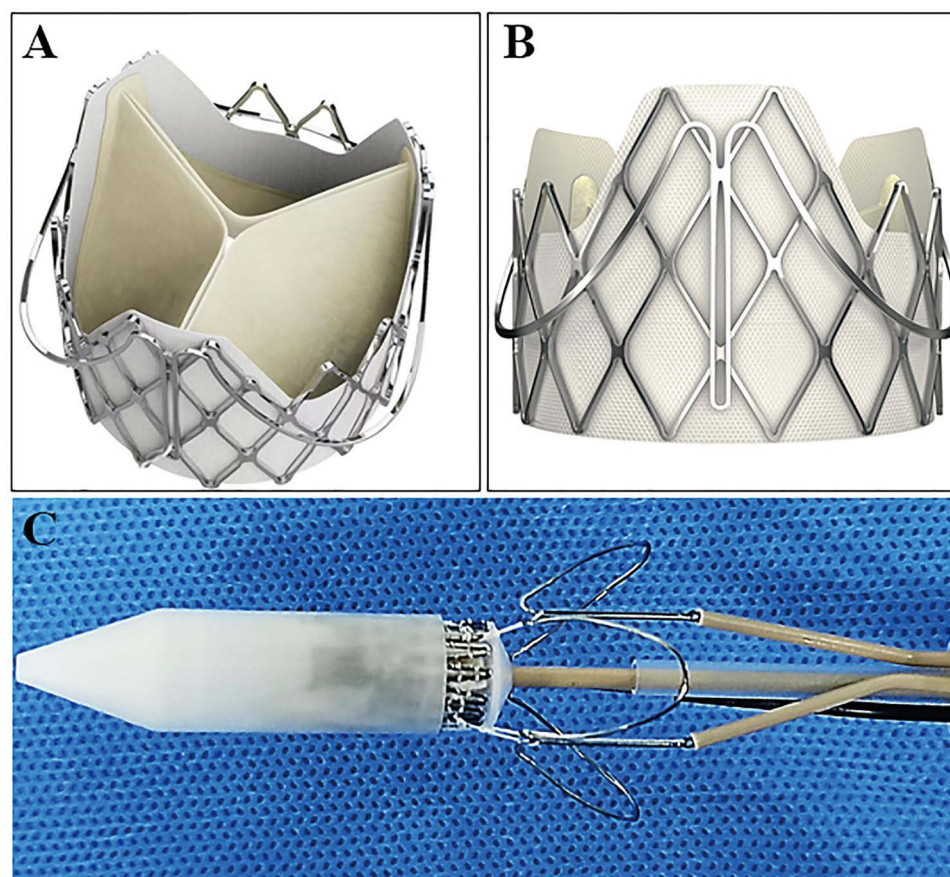


Figure 2 The J-Valve (Jianshi JieCheng Medical Technology Co. Ltd, Shanghai, China) prosthesis. (A) The prosthesis consists of a frame and 3 “U-shaped” clasps. (B) The crown-like frame. (C) Connection between the frame and the clasps.

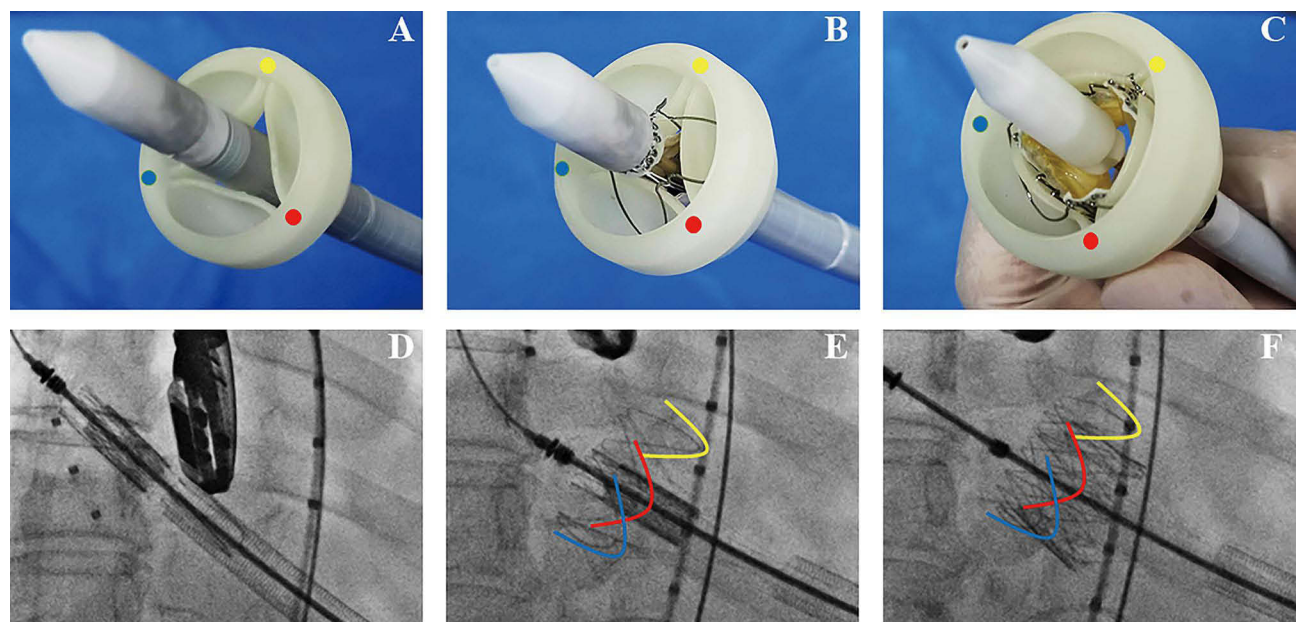


Figure 3 Process of the J-Valve deployment. The Prosthesis deployment process was demonstrated ex vivo within an aortic valve model (A–C) and in vivo with fluoroscopy (D–F). The Prosthesis deployment process was demonstrated ex vivo within an aortic valve model (A–C) and in vivo with fluoroscopy (D–F). (A) The prosthesis was inserted above the aortic annulus. (B) The claspers were deployed and reached each aortic sinus. (C) The prosthesis was released, aligning the three struts with each aortic commissure. (D) The prosthesis was inserted above the aortic annulus under fluoroscopy. (E) The claspers were deployed, reaching each aortic sinus under fluoroscopy. (F) The prosthesis was released, and the three struts were aligned with each aortic commissure under fluoroscopy. Red, yellow, and blue dots respectively indicated each aortic commissure. Red, yellow, and blue dots respectively indicated each aortic commissure.

Statistics

Categorical variables were expressed as numbers and percentages. Continuous variables were expressed as the mean (standard deviation). Non-normally distributed parameters were presented using medians (interquartile ranges). Statistical analysis was conducted using SPSS software (version 20.0; SPSS, Inc., Chicago, IL, USA).

Results

Baseline Clinical Characteristics

A total of 20 consecutive patients (age 72 ± 9 years; 85% female) at potential high risk for CAO who underwent TAVR using the J-Valve were included. The Society of Thoracic Surgeons-Predicted Risk of Mortality was 5% (interquartile range, 4 to 10%). The cohort was typically elderly, with 95% in NYHA classification III or IV at admission, and 25% had a prior stroke. The etiology of the aortic valve was mostly degenerative (70%), rheumatic (15%), bioprosthetic degeneration (10%), and inflammatory aortitis (5%). One patient had a stentless bioprosthesis of Freestyle Solo (Sorin Biomedica, S.p.A., Saluggia, Italy), and another had a bioprosthesis with externally mounted leaflets of Trifecta (St Jude Medical Inc., St Paul, MN, USA). The baseline characteristics of the 20 patients are illustrated in Table 1.

Echocardiograph and MSCT Imaging

Baseline pre-TAVR echocardiographic and MSCT data were available for all patients. (Table 2) Pure aortic regurgitation was reported in 20% of patients. The mean aortic gradient pressure was 36 mmHg (range, 5 to 79 mmHg). Concomitant moderate mitral regurgitation was present in 40% of patients.

Aortic or bioprosthetic leaflets were above the coronary ostium in all patients. In patients with bioprosthetic dysfunction, the bioprosthetic leaflets did not reach the STJ. Therefore, the distance from the THV to STJ was not evaluated. At least two of three classical CT risk predictors for CAO were present in all cases: coronary height < 10 mm, sinus of Valsalva diameter < 30 mm, and VTC < 4 mm.^{1,3} Coronary height < 10 mm was present in 65% of patients,

Table 1 Baseline Characteristics

Variable	N=20
Age, years	72±9
Female	17 (85)
Body mass index, Kg/m ²	21.6 (17.5, 24.0)
NYHA class III or IV	19 (95)
STS, %	5 (410)
Hypertension	16 (80)
Diabetes mellitus	5 (25)
Stroke	4 (20)
Chronic lung disease	4 (20)
Dialysis	1 (5)
Coronary artery disease	3 (15)
Atrial fibrillation	5 (25)
Prior cardiac surgery	4 (20)
Porcelain aorta	1 (5)
Pulmonary edema	1 (5)
Aortic valve etiology	
Degenerative	14 (70)
Rheumatic	3 (15)
Bioprosthetic failure	2 (10)
Inflammatory aortitis	1 (5)
Surgical valve type	
Trifecta	1 (5)
Freedom solo	1 (5)

Note: Value are n (%) or median (interquartile range).

Abbreviations: NYHA, New York Heart Association; STS, Society of Thoracic Surgeons-Predicted Risk of Mortality.

Table 2 Pre-Procedural Imaging Assessment

Pre-procedural Imaging Assessment	N=20
Echocardiography	
Left ventricular ejection fraction, %	60 (27, 69)
Left ventricular end-systolic dimension, mm	32 (24, 53)
Peak aortic valve gradient, mm Hg	67 (15, 121)
Mean aortic valve gradient, mm Hg	36 (5, 79)

(Continued)

Table 2 (Continued).

Pre-procedural Imaging Assessment	N=20
Pure aortic regurgitation	4 (20)
Mitral regurgitation grade \geq moderate	8 (40)
Multislice computed tomography	
Native valve annulus	N=18
Non-calcification aortic valve	5 (25)
Area, mm ²	390 (291, 526)
Perimeter, mm	72.5 (61.3, 83.7)
Risk prediction of native valve and SHV	N=20
Leaflets above coronary ostium	20 (100)
Leaflets above STJ	0 (0)
Coronary height, mm	9.5 (4.6, 12.0)
Coronary height < 10mm	13 (65)
Sinus width, mm	28.1 (22.2, 29.7)
Sinus width < 30mm	20 (100)
VTC, mm	2.7 (1.3, 5.3)
VTC<4 mm	17 (85)
VTC<3 mm	11 (55)

Note: Values are n (%) or median (interquartile range).

Abbreviations: SHV, surgical heart valve; STJ, sinotubular junction; VTC, virtual transcatheter heart valve to coronary distance.

sinus of Valsalva diameter < 30 mm in 100%, VTC distance of < 4 mm in 85%, and a VTC distance of < 3 mm in 55%. Representative cases at potential high risk for CAO are shown in [Figure 4](#).

Procedural Details and Outcomes

The procedural details are revealed in [Table 3](#). Transapical TAVR was performed in all patients. Balloon pre-dilatation was performed in aortic stenosis cases, while post-dilatation was performed in aortic stenosis and valve-in-valve cases. Bioprosthetic frame fracture was not performed in the degenerated Trifecta for an acceptable valve gradient after implantation. Cerebral embolic protection was not used in any patient.

The procedural and 30-day outcomes are presented in [Table 4](#). The procedural success was 95%. In one case, a second THV implantation was performed for moderate paravalvular leakage caused by high implantation of the first device, and the paravalvular leakage was reduced to trace. No cases encountered CAO and required emergency reintervention. There were no patient deaths during the 30-day follow-up. There were no severe transapical complications requiring transfusion or reintervention. One patient was implanted with a permanent pacemaker due to a third-degree atrioventricular block.

At the 30-day follow-up, echocardiography revealed that all bioprostheses function satisfactorily in all patients. The mean aortic valve gradient was 7 (interquartile range, 4, 12) mmHg. No patients had a mean aortic gradient >20 mmHg, and paravalvular leakage or regurgitation severity was less than moderate in all patients. [Figure 5](#) shows stand-alone TAVR using the J-Valve mitigated the risk of CAO and provided an easy coronary access in a representative case.

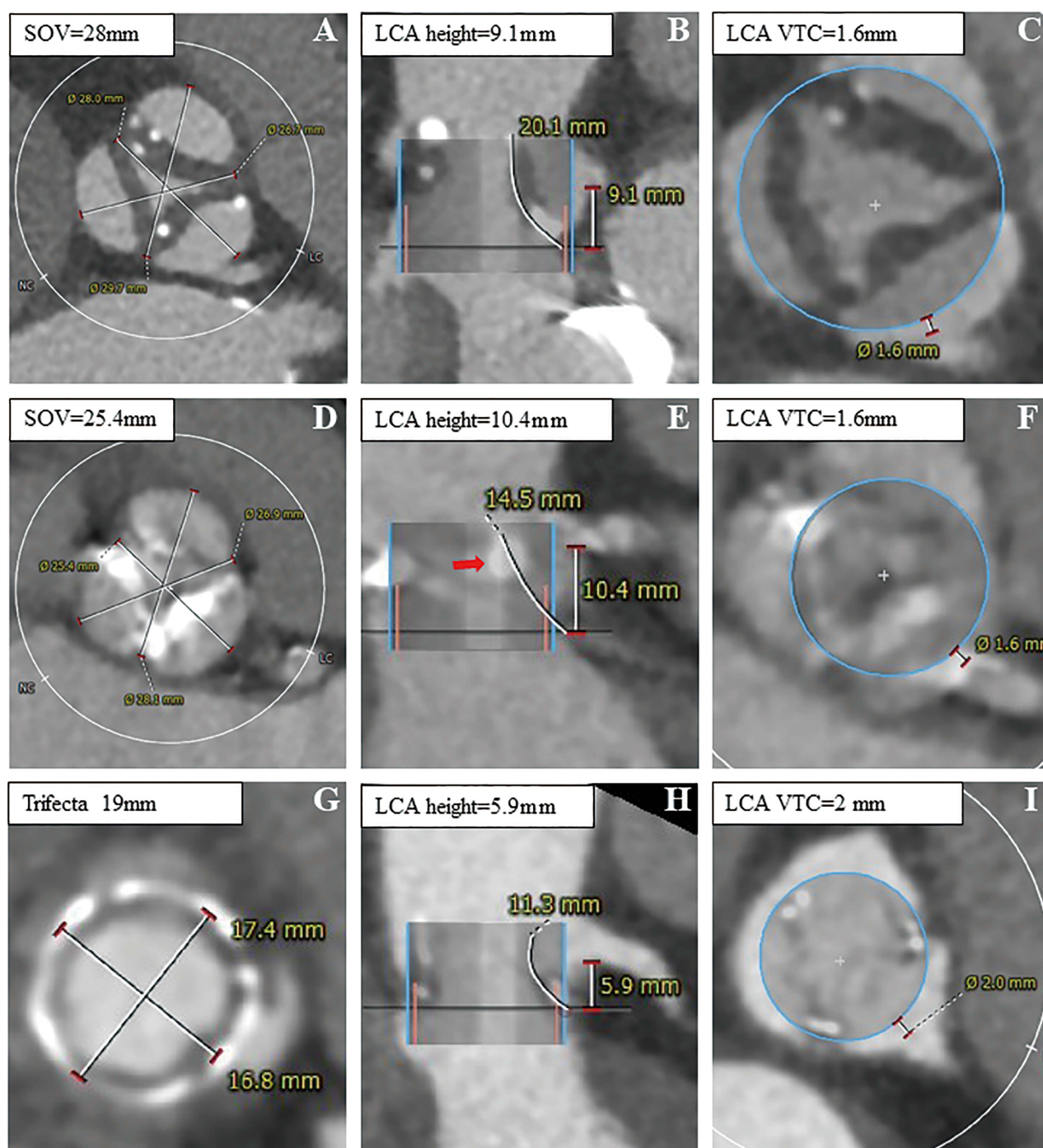


Figure 4 Representative cases at potential high risk for transcatheter aortic valve replacement induced coronary artery obstruction. (A–C) A case at high risk for TAVR-induced CAO, with LCA sinus width =28mm, LCA height = 9.1 mm, LCA VTC = 1.6 mm and thick leaflets. (D–F) A case at high risk for TAVR-induced CAO, with LCA sinus width 25.4mm, LCA height = 10.4 mm, LCA VTC=1.6 mm and a leaflet calcific mass (red arrow). (G–I) A case at high risk for TAVR-induced CAO, with a 19 mm Trifecta prosthesis and LCA VTC = 2.0 mm.

Abbreviations: TAVR, transcatheter aortic valve replacement; CAO, coronary artery obstruction; LCA, left coronary artery; VTC, virtual transcatheter heart valve to coronary distance.

Table 3 Procedural Data

Characteristics	N=20
Transapical access	20 (100)
Cerebral protection device	0 (0)
THV nominal size	
21 mm	5 (25)
23 mm	10 (50)
25 mm	5 (25)
Balloon pre-dilatation	15 (75)
Balloon post-dilatation	16 (80)
Bioprosthetic valve fracture	0 (0)
Fluoroscopy time, min	10 (6, 27)
Contrast volume, mL	60 (40, 140)

Note: Values are n (%) or median (interquartile range).

Abbreviation: THV, transcatheter heart valve.

Table 4 Procedural and 30-Day Outcomes

	N=20
Procedural outcomes	
Immediate survival	20 (100)
Freedom from Second TAVR device implantation	19 (95)
Freedom from coronary artery obstruction	20 (100)
Freedom from emergency reintervention	20 (100)
Procedure success (all of above)	19 (95)
30-day outcomes	
All death	0 (0)
Cardiac death	0 (0)
Coronary artery obstruction	0 (0)
Myocardial infarction	0 (0)
Stroke	0 (0)
Life-threatening bleeding	0 (0)
Major vascular complications	0 (0)
Valve-related reintervention	0 (0)
AKI stage 3 or 4	0 (0)
Early safety (freedom of all of above)	20 (100)

(Continued)

Table 4 (Continued).

Major cardiac structural complication	0 (0)
New permanent pacemaker implantation	1 (5)
Cardiac readmission	1 (5)
PVL > mild	0 (0)
Mean gradient, mmHg	7 (4, 12)
Mean gradient >20 mm Hg	0 (0)

Note: Values are n (%) or median (interquartile range).

Abbreviations: TAVR, transcatheter aortic valve replacement; AKI, acute kidney injury; PVL, paravalvular leakage.

Discussion

This study aimed to determine the feasibility and early safety of TAVR using the J-Valve in patients who could experience coronary obstruction with stand-alone TAVR using mainstream devices. In this study, all patients at potential high risk for CAO were free from CAO 30 days after device implantation, which is comparable to that reported in BALISICA studies of 0–5%.^{8,19} After 30 days, both the mortality rate and the stroke rate were 0%, comparable to contemporary outcomes from the Society of Thoracic Surgeons/American College of Cardiology Transcatheter Valve Therapy Registry for the entire cohort undergoing TAVR.²⁰

Coronary protection with pre-emptive wiring and stenting (regular stent and chimney technique) is a viable option for preventing TAVR-associated CAO.^{21,22} This method is widely practiced and routinely available when CAO is suspected. Previous studies suggest that snorkel stenting to prevent CAO during TAVR is feasible, safe, and has a low rate of complications.^{21–23} At midterm follow-up, stent failure and sinus of Valsalva thrombosis are reported to be 0.9–3.3% and 2.1%,^{21–23} respectively. Stent failure and thrombosis of the sinus of Valsalva may result in delayed CAO. Prolonged dual antiplatelet therapy could be beneficial in reducing the risk of thrombosis. The long-term outcomes of patients with stenting across the coronary ostia remain unknown.

BASILICA is another promising approach to protecting coronary arteries during TAVR procedures. BASILICA has been associated with encouraging short-term results, but it remains a relatively complex procedure requiring unique skill sets and expertise. It has advantages over chimney stenting, including eliminating the need for long-term specific dual-antiplatelet regimens or concerns for late stent failure and risks associated with reaccessing the coronary arteries. However, BASILICA may be associated with high stroke rates,⁸ and may not be feasible in excessively calcified leaflets and is unsuitable for coronary obstruction caused by TAVR commissure.^{8,24}

The uniquely designed J-Valve has three “U-shaped” claspers and a crown-like frame. Following the deployment of the J-Valve, the claspers will seize the leaflets of native valve or surgical heart valves and attach them to the frame of the THV (clip mechanism), thereby reducing the risk of CAO. Additionally, the claspers may also push the aortic sinuses away from aortic leaflets (Figure 6). It has been determined that the clip mechanism is the primary mechanism for reducing the risk of CAO when using the J-Valve, JenaValve (JenaValve, Munich, Germany), and Engager valve (Medtronic, Minneapolis, Minnesota, USA).^{12,25,26} The clip mechanism may also reduce the risk of CAO resulting from calcific leaflet masses and torn leaflets that can be displaced into coronary ostia. In addition, due to the crown-like and low-profile frame, the leaflets will also be retracted (retraction mechanism). The retraction mechanism can further reduce the risk of CAO caused by leaflets displacement, particularly in valve-in-valve procedures.¹³ The “self-positioning” design of the J-Valve aligns the struts with the commissures of the native aortic valve or bioprosthesis (alignment mechanism). Therefore, the alignment mechanism will mitigate the risk of CAO caused by TAVR rotational alignment. These mechanisms (Figure 6) may also offer advantages for coronary reaccess after TAVR. The potential advantages and disadvantages of TAVR using the J-Valve in treating patients with high risk for CAO are summarized in Table 5.

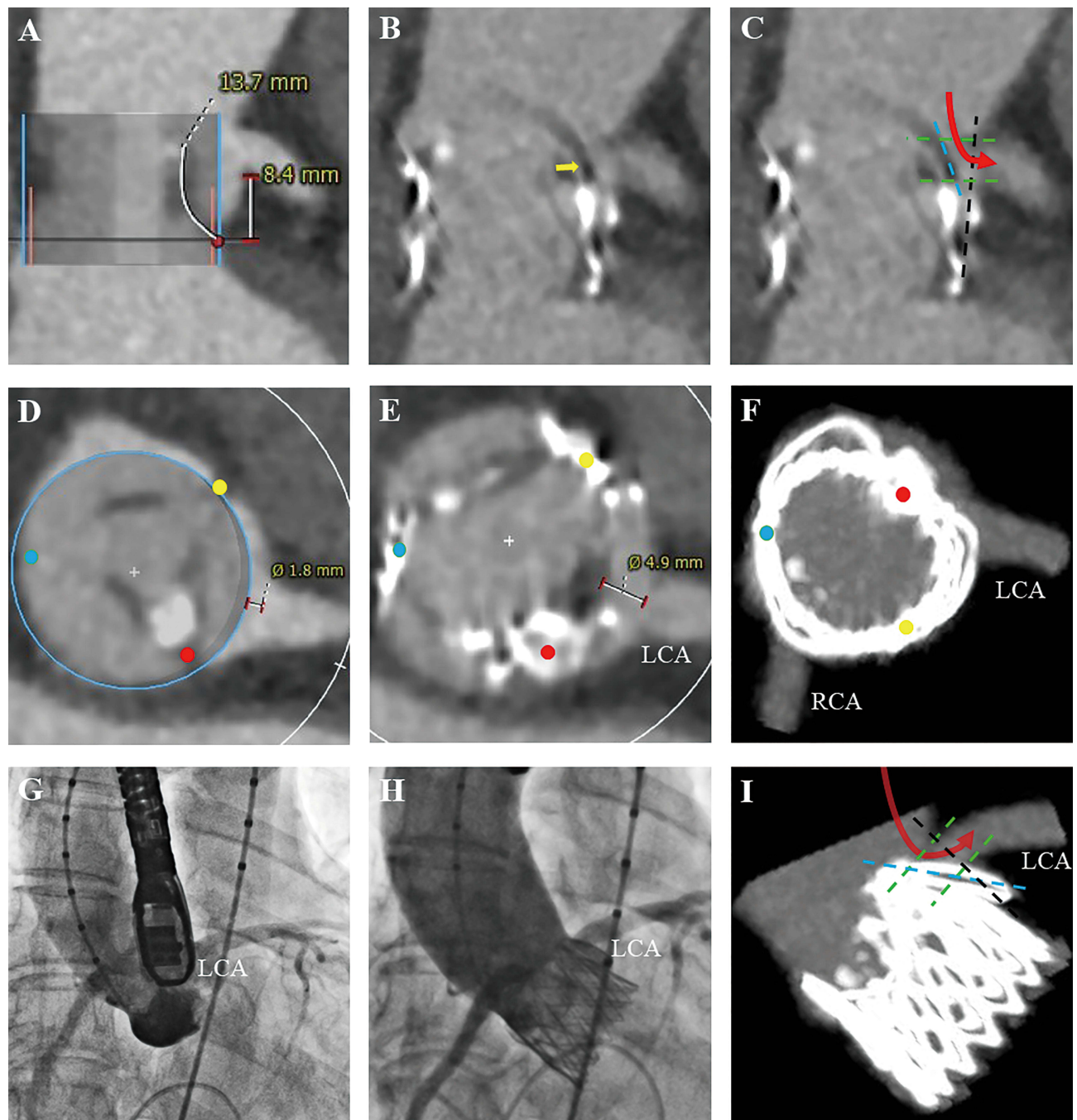


Figure 5 The prosthesis mitigated the risk of coronary ostial obstruction in a representative case. **(A)** Preoperative MSCT showed high risk of coronary ostial obstruction, LCA height = 8.4 mm. **(B and C)** Postoperative MSCT showed a retracted leaflet of the aortic valve (yellow arrow) and an easy coronary access (red arrow). **(D)** Preoperative MSCT indicated LCA VTC = 1.8 mm. **(E, F)** Postoperative MSCT showed commissure alignment between aortic valve commissure and struts of THV (red, yellow, and blue dots indicated each aortic commissure), and the distance from the retracted leaflet to LCA increased to 4.9mm. **(G and H)** Preoperative and postoperative aortography showed avoidance of acute life-threatening ostial coronary artery obstruction after TAVR. **(I)** MSCT 3D reconstruction of the aortic root after THV implantation showed commissure alignment provided an easy coronary access (red arrow).

Abbreviations: MSCT, multislice computed tomography; LCA, left coronary artery; VTC, virtual transcatheter heart valve to coronary distance; THV, transcatheter heart valve; TAVR, transcatheter aortic valve replacement.

The J-Valve has been validated for aortic stenosis and/or regurgitation treatment.^{10,11} Compared to current techniques for CAO, TAVR using J-Valve can avoid the need for additional interventions, resulting in less fluoroscopy time and contrast dose, and reducing the risk of stroke and stent thrombosis. However, transapical access is more invasive, requiring general anesthesia and mini-thoracotomy, which restricts the use of J-Valve for coronary artery protection.

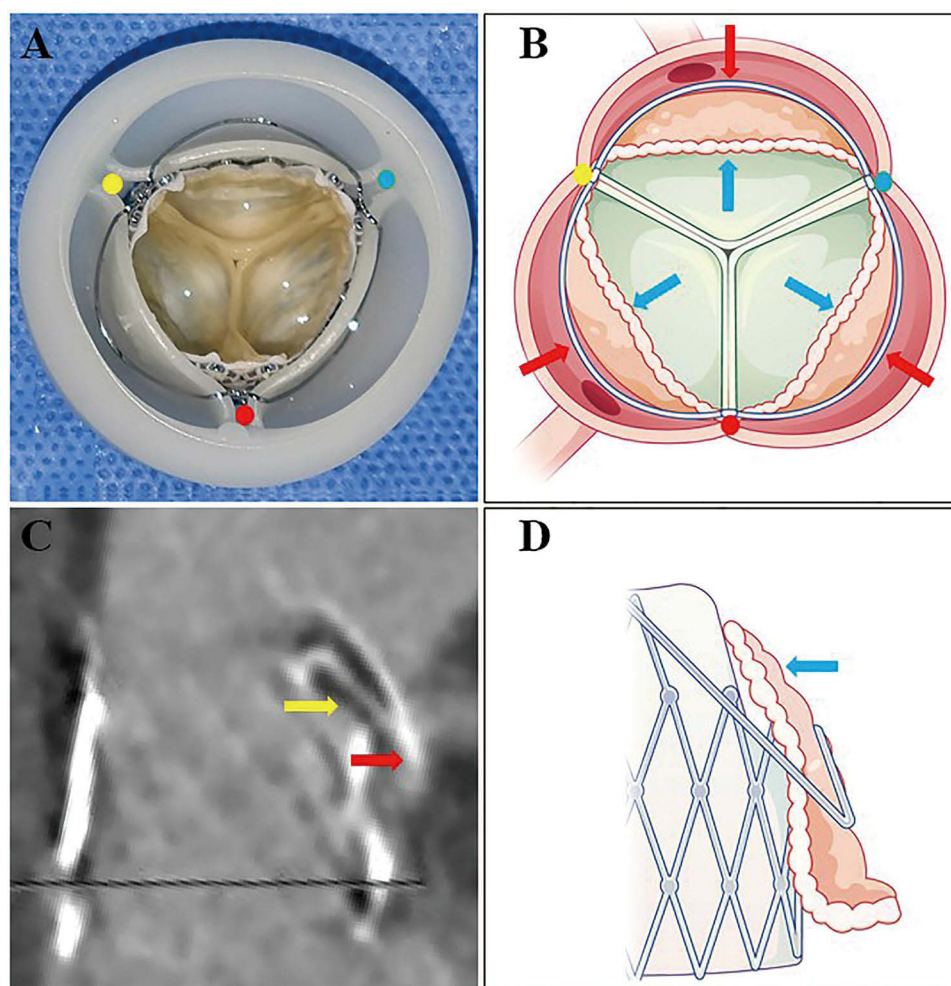


Figure 6 Mechanisms for coronary protection of the J-Valve prosthesis. **(A)** The prosthesis deployment ex vivo within an aortic valve model showed the mechanism of commissure alignment. **(B)** Schematic drawing of the prosthesis deployment showed the aortic leaflets were retracted (blue arrow) and 3 claspers pushed aortic wall away (red arrow). **(C)** Postoperative multislice computed tomography showed the aortic leaflet (yellow arrow) was retracted, and the clasper clipped the leaflet and pushed the aortic wall away (red arrow). **(D)** Schematic drawing of the prosthesis deployment showed the aortic leaflet was retracted (blue arrow) due to crown-like frame and clipped by its clasper.

Transfemoral J-Valve (Jianshi JieCheng Medical Technology Co, Ltd, Shanghai, China) is under clinical trial (NCT05580952) and will be available soon. In our daily treatment for patients with TAVR indications, transfemoral TAVR devices will be the first choice for aortic calcification diseases and bioprosthetic degeneration. However, if

Table 5 Advantages and Disadvantages of the J-Valve for Coronary Protection

Advantages	Disadvantages
Available for patients who are predicted to have a low risk of CAO	Transapical access is more invasive than transfemoral access
Stand-alone TAVR, avoidance of additional interventions.	May not be suitable for tediously long leaflets which can hinder the claspers into sinuses.
Available for pure aortic regurgitation	Not suitable for eccentric coronary ostia
May facilitate future coronary access	Not suitable for excessively low coronary ostia

Abbreviations: CAO, coronary artery obstruction; TAVR, transcatheter aortic valve replacement.

a multidisciplinary heart team determines that a patient is at high risk for CAO, J-Valve may be considered a coronary protection strategy.

By stratifying patients at risk for CAO, patients may derive the most benefit from these treatments and avoid unnecessary procedures with additional risks. However, the current prediction model derived from a small number of CTs of coronary obstruction cases is not absolute,^{15,16} as those predicted to have a low risk of CAO during TAVR may still develop CAO. Before establishing an optimal CAO prediction model, THVs designed for coronary protection may be a viable option. Notably, the current indications for TAVR are expanding to include patients with low surgical risk and young age; CAO as a potentially fatal complication and future coronary access should be carefully considered. The promising outcomes and potential mechanisms of J-Valve for CAO may shed light on the development of more recent iterations of TAVR devices.

Limitation

This study has several limitations, including bias from its retrospective design and a small sample size. Additionally, the data were not collected by an independent institution nor analyzed by core laboratories. The issues of small sample size and selection bias primarily stem from the low incidence of CAO and the retrospective nature of our study. To mitigate this, we implemented strict inclusion criteria and standardized review methods to reduce bias and enhance the credibility of our data. The absence of a control group is due to our clinical practice's preference for using the J-Valve in treating high-risk patients, who are inherently rare, leading to the study's design as a single-arm. Moreover, the current CAO prediction model, particularly for native valves, is imprecise; 86.7% of our study's participants had native valve diseases, suggesting that these patients might also be free from CAO using other mainstream devices. Not all patients underwent postoperative MSCT scans, suggesting the possibility that some might have developed partial coronary obstruction that did not require intervention and was undetectable via angiography, electrocardiogram, or clinical evidence. For this reason, we defined coronary obstruction that requires intervention as CAO.

Conclusion

Our data show that stand-alone TAVR using the J-Valve prosthesis prevents unnecessary procedures and is associated with promising early outcomes in treating patients at potential high risk for CAO. Clipping and retracting leaflets and aligning the commissures may be the main mechanisms for reducing the risk of CAO. These mechanisms could also protect future coronary access following TAVR or TAVIV.

Data Sharing Statement

The data generated for this study are available from the corresponding author upon reasonable request.

Funding

This work was sponsored by the National Natural Science Foundation of China (No.82200526).

Disclosure

The abstract of this paper was presented at the ISMICS 2023 Annual Meeting as a poster presentation with interim findings. All authors report no conflicts of interest in this work.

References

1. Ribeiro HB, Webb JG, Makkar RR, et al. Predictive factors, management, and clinical outcomes of coronary obstruction following transcatheter aortic valve implantation: insights from a large multicenter registry. *J Am Coll Cardiol*. 2013;62(17):1552–1562. doi:10.1016/j.jacc.2013.07.040
2. Arai T, Lefevre T, Hovasse T, et al. Incidence and predictors of coronary obstruction following transcatheter aortic valve implantation in the real world. *Catheter Cardiovasc Interv*. 2017;90(7):1192–1197. doi:10.1002/ccd.26982
3. Ribeiro HB, Rodes-Cabau J, Blanke P, et al. Incidence, predictors, and clinical outcomes of coronary obstruction following transcatheter aortic valve replacement for degenerative bioprosthetic surgical valves: insights from the VIVID registry. *Eur Heart J*. 2018;39(8):687–695. doi:10.1093/eurheartj/ehx455
4. Abramowitz Y, Chakravarty T, Jilaihawi H, et al. Clinical impact of coronary protection during transcatheter aortic valve implantation: first reported series of patients. *EuroIntervention*. 2015;11(5):572–581. doi:10.4244/EIJV11I5A112

5. Spaziano M, Akodad M, Hovasse T, Lefevre T, Bouvier E, Chevalier B. Simultaneous TAVR and left main “chimney” stenting in a patient with low left main height. *JACC: Cardiovasc Interv.* **2017**;10(20):e185–e187. doi:10.1016/j.jcin.2017.06.047
6. Khan JM, Dvir D, Greenbaum AB, et al. Transcatheter laceration of aortic leaflets to prevent coronary obstruction during transcatheter aortic valve replacement: concept to first-in-human. *JACC: Cardiovasc Interv.* **2018**;11(7):677–689. doi:10.1016/j.jcin.2018.01.247
7. Arevalos V, Spione F, Vela P, et al. Coronary obstruction following transcatheter aortic valve replacement. Risk evaluation and preventive strategies. *Rec-Intervent Cardiol.* **2023**;2023:1.
8. Khan JM, Greenbaum AB, Babaliaros VC, et al. The BASILICA trial: prospective multicenter investigation of intentional leaflet laceration to prevent TAVR coronary obstruction. *JACC: Cardiovasc Interv.* **2019**;12(13):1240–1252. doi:10.1016/j.jcin.2019.03.035
9. Shi J, Wei L, Chen Y, et al. Transcatheter aortic valve implantation with J-Valve: 2-year outcomes from a multicenter study. *Ann Thorac Surg.* **2021**;111(5):1530–1536. doi:10.1016/j.athoracsur.2020.06.139
10. Liu H, Yang Y, Wang W, et al. Transapical transcatheter aortic valve replacement for aortic regurgitation with a second-generation heart valve. *J Thorac Cardiovasc Surg.* **2018**;156(1):106–116. doi:10.1016/j.jtcvs.2017.12.150
11. Zhu L, Guo Y, Wang W, et al. Transapical transcatheter aortic valve replacement with a novel transcatheter aortic valve replacement system in high-risk patients with severe aortic valve diseases. *J Thorac Cardiovasc Surg.* **2018**;155(2):588–597. doi:10.1016/j.jtcvs.2017.09.015
12. Ye J, Lee AJ, Blanke P, Webb J. The first transapical transcatheter aortic valve-in-valve implantation using the J-valve system into a failed bioprosthesis aortic prosthesis in a patient with high risk of coronary obstruction. *Catheter Cardiovasc Interv.* **2018**;92(6):1209–1214. doi:10.1002/ccd.27604
13. Hensey M, Sellers S, Sathananthan J, et al. Bioprosthetic valve leaflet displacement during valve-in-valve intervention: an ex vivo bench study. *JACC: Cardiovasc Interv.* **2020**;13(6):667–678. doi:10.1016/j.jcin.2019.10.021
14. Nishimura RA, Otto CM, Bonow RO, et al. 2017 AHA/ACC Focused Update of the 2014 AHA/ACC guideline for the management of patients with valvular heart disease: a report of the American college of cardiology/American heart association task force on clinical practice guidelines. *J Am Coll Cardiol.* **2017**;70(2):252–289. doi:10.1016/j.jacc.2017.03.011
15. Blanke P, Weir-McCall JR, Achenbach S, et al. Computed Tomography Imaging in the Context of Transcatheter Aortic Valve Implantation (TAVI)/Transcatheter Aortic Valve Replacement (TAVR): an expert consensus document of the society of cardiovascular computed tomography. *JACC Cardiovasc Imaging.* **2019**;12(1):1–24. doi:10.1016/j.jcmg.2018.12.003
16. Blanke P, Soon J, Dvir D, et al. Computed tomography assessment for transcatheter aortic valve in valve implantation: the Vancouver approach to predict anatomical risk for coronary obstruction and other considerations. *J Cardiovasc Comput Tomogr.* **2016**;10(6):491–499. doi:10.1016/j.jcct.2016.09.004
17. Bapat V. Valve-in-valve apps: why and how they were developed and how to use them. *EuroIntervention.* **2014**;10:U44–U51. doi:10.4244/EIJV10SUA7
18. Genereux P, Piazza N, Alu MC, et al. Valve academic research consortium 3: updated endpoint definitions for aortic valve clinical research. *J Am Coll Cardiol.* **2021**;77(21):2717–2746. doi:10.1016/j.jacc.2021.02.038
19. Khan JM, Babaliaros VC, Greenbaum AB, et al. Preventing coronary obstruction during transcatheter aortic valve replacement: results from the multicenter international BASILICA registry. *JACC: Cardiovasc Interv.* **2021**;14(9):941–948. doi:10.1016/j.jcin.2021.02.035
20. Carroll JD, Mack MJ, Vemulapalli S, et al. STS-ACC TVT registry of transcatheter aortic valve replacement. *Ann Thorac Surg.* **2021**;111(2):701–722. doi:10.1016/j.athoracsur.2020.09.002
21. Mercanti F, Rosseel L, Neylon A, et al. Chimney stenting for coronary occlusion during TAVR: insights from the chimney registry. *JACC: Cardiovasc Interv.* **2020**;13(6):751–761. doi:10.1016/j.jcin.2020.01.227
22. Mangieri A, Gallo F, Popolo RA, et al. Outcome of coronary ostial stenting to prevent coronary obstruction during transcatheter aortic valve replacement. *Circ Cardiovasc Interv.* **2020**;13(6):e009017. doi:10.1161/CIRCINTERVENTIONS.120.009017
23. Palmerini T, Chakravarty T, Saia F, et al. Coronary protection to prevent coronary obstruction during TAVR: a multicenter international registry. *JACC: Cardiovasc Interv.* **2020**;13(6):739–747. doi:10.1016/j.jcin.2019.11.024
24. Lederman RJ, Babaliaros VC, Rogers T, et al. Preventing coronary obstruction during transcatheter aortic valve replacement: from computed tomography to BASILICA. *JACC: Cardiovasc Interv.* **2019**;12(13):1197–1216. doi:10.1016/j.jcin.2019.04.052
25. Conradi L, Kloth B, Seiffert M, et al. The challenge of valve-in-valve procedures in degenerated Mitroflow bioprostheses and the advantage of using the JenaValve transcatheter heart valve. *EuroIntervention.* **2014**;10(8):990–994. doi:10.4244/EIJV10I8A167
26. Camboni D, Holzamer A, Florchinger B, et al. Single institution experience with transcatheter valve-in-valve implantation emphasizing strategies for coronary protection. *Ann Thorac Surg.* **2015**;99(5):1532–1538. doi:10.1016/j.athoracsur.2014.11.047

Clinical Interventions in Aging

Dovepress

Publish your work in this journal

Clinical Interventions in Aging is an international, peer-reviewed journal focusing on evidence-based reports on the value or lack thereof of treatments intended to prevent or delay the onset of maladaptive correlates of aging in human beings. This journal is indexed on PubMed Central, MedLine, CAS, Scopus and the Elsevier Bibliographic databases. The manuscript management system is completely online and includes a very quick and fair peer-review system, which is all easy to use. Visit <http://www.dovepress.com/testimonials.php> to read real quotes from published authors.

Submit your manuscript here: <https://www.dovepress.com/clinical-interventions-in-aging-journal>