

# Dexmedetomidine and Dexamethasone as Adjuvants to the Local Anesthetic Mixture in Rhomboid Intercostal and Sub-Serratus Block for Video-Assisted Thoracoscopic Surgery: A Randomized, Double-Blind, Controlled Trial

Quan-fang Liu<sup>1</sup>, Cui-na Shi<sup>1</sup>, Jian-hua Tong<sup>1</sup>, Kun-peng Li<sup>1</sup>, Jian-jun Yang<sup>1</sup>, Mu-huo Ji<sup>1</sup>, Qing-ren Liu<sup>1</sup>

<sup>1</sup>Department of Anesthesiology, The Second Affiliated Hospital of Nanjing Medical University, Nanjing, People's Republic of China; <sup>2</sup>Department of Anesthesiology, Pain and Perioperative Medicine, The First Affiliated Hospital of Zhengzhou University, Zhengzhou, People's Republic of China;

<sup>3</sup>Department of Anesthesiology, Xishan People's Hospital of Wuxi City, Wuxi, People's Republic of China

Correspondence: Qing-ren Liu, Department of Anesthesiology, Xishan People's Hospital of Wuxi City, Wuxi, People's Republic of China, Email liuqr5250@163.com; Mu-huo Ji, Department of Anesthesiology, The Second Affiliated Hospital, Nanjing Medical University, Nanjing, People's Republic of China, Email jimuhuo2009@sina.com

**Background:** The utilization of adjuvants such as dexamethasone and dexmedetomidine in combination with local anesthetics has proven effective in extending analgesia duration. We aimed to investigate the potential efficacy of combining dexmedetomidine and dexamethasone in rhomboid intercostal and sub-serratus (RISS) block for prolonging postoperative analgesia in patients undergoing video-assisted thoracoscopic surgery (VATS).

**Methods:** We did this randomized, double-blind, controlled trial in two tertiary-care hospitals. A total of eighty-eight patients undergoing VATS under general anesthesia were enrolled in this study. They were randomly assigned into four groups: ropivacaine (R) group, ropivacaine + dexmedetomidine (RM) group, ropivacaine + dexamethasone (RS) group, or ropivacaine + dexmedetomidine + dexamethasone (RSM) group. The primary outcome measure was the duration of analgesia. Secondary outcomes included Numeric Rating Scale (NRS) scores, cumulative oxycodone consumption, and adverse effects.

**Results:** The RSM group exhibited a significantly prolonged duration of analgesia at 1073.5 min (932.0–1283.3) compared to the R group with a duration of 154.5 min (80.5–199.3) and the RS group with a duration of 282.0 min (195.3–350.0,  $P < 0.001$ ). The cumulative oxycodone consumption during the 0–12 hours and 0–24-hours period was significantly reduced in the RSM group compared to the R group ( $P < 0.05$ ). There was also a lower incidence of nausea at 48 hours postoperatively in the RSM group compared to the RM group. However, there were no significant differences between the four groups regarding NRS pain scores.

**Conclusion:** The combination of ropivacaine, dexmedetomidine, and dexamethasone in RISS block significantly prolongs the duration of postoperative analgesia following VATS.

**Keywords:** nerve block, pain, postoperative, anesthesia, video-assisted thoracoscopic surgery

## Introduction

Currently, video-assisted thoracoscopic surgery (VATS) has reached maturity and widespread acceptance, with continuous refinement and enhancement of surgical techniques.<sup>1</sup> However, the occurrence of severe postoperative pain in patients significantly hampers rapid recovery and leads to prolonged hospitalization.<sup>2</sup> The utilization of thoracic epidural analgesia (TEA) or paravertebral block (PVB) for analgesia during surgery poses challenges due to its inherent difficulties, associated risks, contraindications, as well as potential complications such as hypotension and bradycardia. Therefore, alternative methods with less side effects need to be explored.

The rhomboid intercostal and sub-serratus (RISS) block represents a novel technique for providing thoracic and upper abdominal analgesia through the fascial plane, which can provide analgesia of T3-T8 dermatomes.<sup>3</sup> However, there is a paucity of research on this particular block, necessitating further randomized controlled studies to substantiate its efficacy. RISS block is a two-injection block of both the rhomboid intercostal and sub-serratus space, it can adequately address post-thoracic surgery analgesic requirements. There was a variation in the dermatomal coverage ranging from T3 to T12.<sup>4</sup> Recent studies have demonstrated that the RISS block can effectively alleviate postoperative pain in VATS,<sup>5</sup> open chest surgery,<sup>6</sup> lung transplantation surgery,<sup>7</sup> and multiple rib fractures fixation surgery.<sup>8</sup> Moreover, in thoracoscopic surgery specifically, the analgesic efficacy of the RISS block surpasses that of an isolated serratus anterior plane block.<sup>9</sup> However, due to the relatively short duration of local anesthetic analgesia, it often fails to provide prolonged postoperative pain relief in most cases.

In regional nerve blocks, the incorporation of specific anesthetic adjuvants such as dexmedetomidine and dexamethasone has demonstrated efficacy in extending the duration of local anesthetic analgesia.<sup>10,11</sup> It has been suggested that the combination of dexmedetomidine and dexamethasone for intercostal nerve block not only extends the duration of initial analgesia after thoracoscopic surgery but also effectively mitigates postoperative pain and reduces analgesic consumption compared to their individual administration.<sup>12</sup>

Dexamethasone is a glucocorticoid with anti-inflammatory, anti-allergic, and immunosuppressive properties. It extends the duration of local anesthetics through complex mechanisms that are not fully understood. Adding glucocorticoids to local anesthetics can reduce the production and release of inflammatory mediators. Dexamethasone also affects nerve activity by binding to glucocorticoid receptors, leading to peripheral vasoconstriction, which slows the uptake of anesthetics and prolongs their effects.<sup>13,14</sup> Dexmedetomidine is a selective  $\alpha$ -2 adrenergic receptor agonist with sedative and analgesic effects. It prolongs the action of local anesthetics by causing peripheral vasoconstriction and inhibiting pain signals.<sup>15</sup> It achieves this by activating specific nerve pathways and reducing the release of neurotransmitters like substance P.<sup>16,17</sup> The combination of dexamethasone and dexmedetomidine may extend the duration of anesthesia more effectively than either drug alone, but the exact mechanisms are complex and need further study. More research, especially randomized controlled trials, is needed to confirm the effectiveness of using both agents with RISS blocks.

Therefore, we conducted a prospective, randomized, double-blind, controlled trial to investigate whether the combination of dexmedetomidine and dexamethasone in RISS blockade can provide effective postoperative analgesia for VATS. We hypothesized that the coadministration of ropivacaine with both perineural dexamethasone and dexmedetomidine could potentially augment the duration of RISS block.

## Methods

### Study Design

We did this randomized, double-blind, controlled trial at the Second Affiliated Hospital of Nanjing Medical University and Xishan People's Hospital of Wuxi City. The study was prospectively registered on ClinicalTrials.gov (Identifier: ChiCTR2200063391) and conducted in accordance with the Declaration of Helsinki. The date of our clinical trial's prospective registration was September 1st, 2022, and the date of first patient enrollment was September 1st, 2022.

### Participants

After obtaining written informed consent, patients classified as American Society of Anesthesiologists (ASA) physical status I–III, aged between 18 and 80 years, scheduled to undergo VATS between September 1st, 2022 and February 28th, 2023, and who underwent preoperative ultrasound-guided RISS blockade were considered eligible to participate in this prospective, randomized, double-blind clinical trial.

The main exclusion criteria included severe cardiovascular or respiratory diseases, sinus bradycardia, heart conduction blockage, a history of chronic analgesic use, prolonged opioid or corticosteroid administration, psychiatric disorders in the medical history, drug allergies relevant to the study drugs used herein or refusal to provide consent for participation. Individuals with an estimated intraoperative blood loss exceeding 500 mL were subsequently excluded

from the study. Those who required conversion to open thoracic surgery or secondary interventions due to postoperative hemorrhage or developed severe postoperative infections were also excluded from the study.

## Randomization and Blinding

Participants were randomly allocated into one of four groups in a 1:1:1:1 ratio. The randomization process was executed using an online central randomization system, with stratification based on study sites ([www.randomization.com](http://www.randomization.com)). Each participating center enrolled 44 patients, and the allocation information was subsequently disseminated to each site for implementation.

1. R group: received 40 mL of 0.375% ropivacaine;
2. RM group: received 40 mL of 0.375% ropivacaine combined with dexmedetomidine at a dose of 1 µg/kg;
3. RS group: received 40 mL of 0.375% ropivacaine combined with dexamethasone at a dose of 8 mg;
4. RSM group: received 40 mL of 0.375% ropivacaine combined with dexmedetomidine at a dose of 1 µg/kg plus dexamethasone at a dose of 8 mg.

The volume administered for each study drug was set at precisely 40 mL. This code was stored in sealed, opaque envelopes and with the research coordinator. The envelopes were then given to an operating room nurse, who had no further participation in the study and was responsible for the preparation of the medicament according to the code within the envelope. The patient, anesthesiologist, surgeon, acute pain nurses, and outcome assessors were blinded to group allocation.

## Anesthetic Technique

After admission, routine monitoring including invasive arterial blood pressure, 5-lead electrocardiography, heart rate, respiratory rate, and pulse oxygen saturation was conducted. Anesthesia induction was performed with intravenous administration of sufentanil at a dose of 0.2–0.4 µg/kg, propofol at a dose of 1.5–2.5 mg/kg, and rocuronium at a dose of 0.5–0.6 mg/kg, followed by fiberoptic bronchoscope-guided tracheal intubation. Anesthesia machine-controlled ventilation was initiated with the tidal volume set at 6–8 mL/kg and the respiratory rate set at 12 beats per minute. Rhomboid intercostal blockades were performed after positioning in the rhomboid intercostal plane as well as in the low anterior chest wall plane for blockade purposes. The specific operational procedure for the RISS blockade was as follows: position a linear ultrasound probe in the sagittal plane at the T5-6 level, medially to the scapula, to identify the rhomboid, serratus anterior, and intercostal muscles. Introduce a 21-gauge needle in a cephalocaudal direction between the planes of rhomboid and intercostal muscles and administer 20 mL of 0.375% ropivacaine (or adjunctive local anesthetic) at this site. Subsequently, shift the ultrasound probe caudally and laterally to identify the tissue plane between the serratus anterior and external intercostal muscles at the T8-9 level for the serratus plane block. Progressively advance the needle from its initial position and inject 20 mL of 0.375% ropivacaine (or adjunctive local anesthetic). All blocks are performed by a consistent anesthesiologist at each research center who has received specialized training. General anesthesia maintenance consisted of inhalation of sevoflurane ranging from 2.0% to 3.0% (equivalent to approximately 0.7–1.0 MAC) along with an intravenous infusion of remifentanyl ranging from doses between 0.05 µg/kg/min up to maximum doses reaching around 0.2 µg/kg/min during the intraoperative period. Maintain heart rates within the range of fifty to eighty beats per minute without exceeding changes in blood pressure values beyond twenty percent compared to baseline values. If the heart rate drops below 50 beats per minute, intravenous atropine 0.5 mg is administered; if blood pressure drops below 80% of baseline, intravenous ephedrine or phenylephrine is administered. Cisatracurium 5 mg is administered every hour for muscle relaxation maintenance, and 15 min before the end of the surgery, intravenous sufentanil 0.1 µg/kg is administered. After completion of the surgery, patients are transferred to the PACU where neostigmine and atropine are used for antagonism, and tracheal tubes are removed when patients regain consciousness and full muscle strength.

## Analgesic Technique

In the PACU, when patients complain of pain, intravenous oxycodone 2 mg is immediately administered with repeated doses of intravenous oxycodone 2 mg at 5 minutes intervals if necessary until the patient's NRS score is < 4 followed, then initiate the administration of analgesia via the pump. The PCA pump is configured with oxycodone 50 mg +

palonosetron 0.15 mg/100 mL, without a background infusion. It delivers a PCA bolus dose of 4 mL with a lockout time of 5 minutes and a maximum hourly limit of 16 mL. If the NRS score remains  $> 3$  after three PCAs in the ward, intravenous NSAIDs such as parecoxib or ketorolac are administered for rescue analgesia.

## Outcome Measures

The duration of analgesia was defined as the time to the first request for analgesics, measured in minutes, and designated as the primary outcome. The secondary outcomes assessed in the study included cumulative oxycodone consumption, postoperative pain intensity, time to first ambulation, length of hospital stay, and incidence of adverse events. The cumulative oxycodone consumption was recorded postoperatively at 0–12 hours, 12–24 hours, 0–24 hours, 24–48 hours, and 0–48 hours. Resting and coughing numerical rating scale (NRS) scores were assessed at postoperative 1 hour, 3 hours, 6 hours, 12 hours, 24 hours, and 48 hours. Adverse reactions such as hypotension, nausea, vomiting, dizziness, drowsiness, and pruritus were recorded within the initial period of up to 48 hours following surgery.

## Sample Size

The sample size was calculated based on the duration of analgesia using PASS V11.0 for Windows software (PASS, NCS, USA). A study of intercostal nerve block analgesia in thoracoscopic surgery showed that the mean and standard deviation of analgesia duration in ropivacaine group, ropivacaine combined with dexamethasone group, ropivacaine combined with dexmedetomidine group, and ropivacaine combined with dexamethasone and dexmedetomidine group were  $440.0 \pm 109.6$  min,  $611.5 \pm 133.0$  min,  $602.5 \pm 108.5$  min, and  $824.2 \pm 105.1$  min, respectively.<sup>12</sup> Using a one-way analysis of variance for four groups, 16 patients per group would be required in accordance with a significance level of 0.05 and a power of 0.8. In consideration of the possible dropout rate of up to 25%, we included 22 patients per group.

## Statistical Analysis

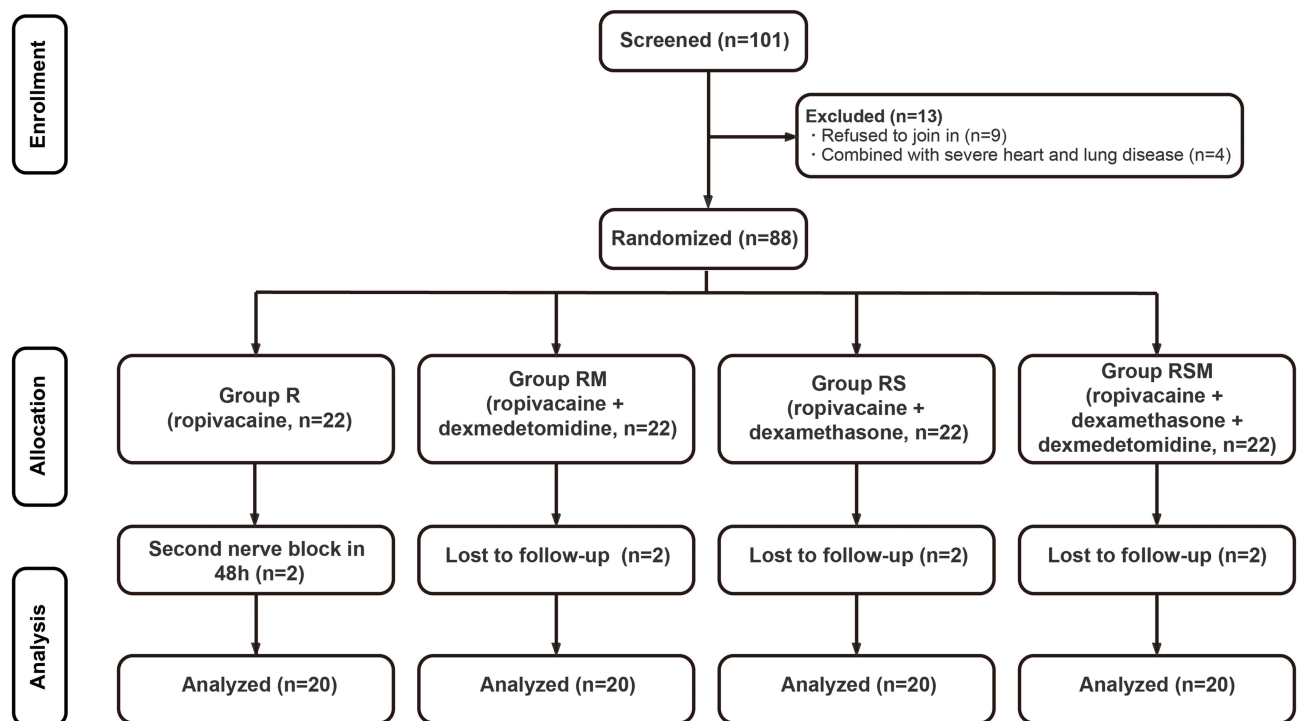
Continuous data were tested for normality using the Shapiro–Wilk test. Homogeneity of variances was tested by Levene's test. Normally distributed data were presented as mean  $\pm$  SD and compared among the four groups using ANOVA followed by the Bonferroni post hoc test. If the distribution was not normal as in the case of the duration of analgesia, remifentanyl consumption, time to first ambulation, length of hospital stay, and other data, the median and first (Q25) and third quartiles (Q75) are reported and Kruskal–Wallis test was used to compare groups. Subsequent comparison of groups within each Kruskal–Wallis test were Bonferroni-corrected. Repeated measures ANOVA with Bonferroni correction was used for NRS score and. Categorical data were presented as frequencies (%) and analyzed using the chi-square test or Fisher's exact test.  $P < 0.05$  value was considered to be statistically significant. Statistical analysis was conducted using SPSS V.26.0 for Windows and GraphPad Prism 9.5 (GraphPad Software, La Jolla, USA).

## Results

Figure 1 presents the Consolidated Standards of Reporting Trials flowchart for this study. A total of 101 patients participated in the study from September 1st, 2022 to February 28th, 2023. Thirteen patients were excluded due to failure to meet inclusion criteria or refusal to participate, while eight patients were excluded for non-compliance with the study protocol (two patients requested repeated nerve block within 48 hours postoperatively; six patients were lost to follow-up). Ultimately, a total of 80 randomized patients completed the study protocol.

Except for gender, no statistically significant differences were observed in patient characteristics among the groups. The proportion of female patients was higher in the RSM group compared to the R, RM, and RS groups (Table 1). Intraoperative variables such as duration of anesthesia, duration of surgery, and intraoperative blood loss also exhibited no significant variations across the groups (Table 1).

The median (interquartile range) duration of analgesia in the RSM group [1073.5 min (932.0–1283.3)] was significantly longer than that in the R group [154.5 min (80.5–199.3),  $P < 0.001$ ] and the RS group [282.0 min (195.3–350.0),  $P < 0.001$ ]. The RM group exhibited a significantly longer duration of analgesia [600.0 min (351.0–1105.8)] compared to the R group [154.5 min (80.5–199.3),  $P < 0.001$ ]. No statistically significant differences were observed in analgesia duration between the RS group and either the R or RM groups. Similarly, no significant differences



**Figure 1** Consolidated Standards of Reporting Trials flowchart of the study.

were found between the RSM and RM groups ( $P > 0.05$ ) (Table 2, [Supplementary Table 1](#)). No significant differences were observed in the remifentanyl consumption, time to first ambulation, or length of hospital stay among the four groups ( $P > 0.05$ ) (Table 2).

The cumulative oxycodone consumption in the RSM group during 0–12 hours postoperatively [0 mg (0–0)] was significantly lower than that in the R group [6 mg (4–8),  $P < 0.001$ ], and the cumulative oxycodone consumption in the RM group [2 mg (0–4)] was also significantly lower than that in the R group [6 mg (4–8),  $P < 0.001$ ]. The cumulative oxycodone consumption in the RSM group during 0–24 hours postoperatively [2 mg (2–8)] was significantly lower than that in the R group [8 mg (6–14),  $P < 0.05$ ], and the cumulative oxycodone consumption in the RM group [6 mg (2–10)]

**Table 1** Demographic Characteristics and Perioperative Variables

	R (n=20)	RM (n=20)	RS (n=20)	RSM (n=20)	P
Sex					0.039
Female	16 (80%)	15 (75%)	12 (60%)	8 (40%)	
Male	4 (20%)	5 (25%)	8 (40%)	12 (60%)	
Age, years	65.2 (12.2)	60.3 (11.5)	60.5 (11.8)	63.6 (7.5)	0.431
BMI, kg/m <sup>2</sup>	23.8 (4.8)	24.5 (5.5)	23.5 (2.9)	24.3 (3.0)	0.705
ASA score					0.056
I	1 (5%)	0 (0%)	0 (0%)	0 (0%)	
II	13 (65%)	20 (100%)	19 (95%)	15 (75%)	
III	6 (30%)	0 (0%)	1 (5%)	5 (25%)	
History of tobacco use					0.190
Never	7 (35%)	4 (20%)	1 (5%)	4 (20%)	
Former	1 (5%)	1 (5%)	4 (20%)	7 (35%)	
Current	12 (60%)	15 (75%)	15 (75%)	9 (45%)	

(Continued)

**Table 1** (Continued).

	R (n=20)	RM (n=20)	RS (n=20)	RSM (n=20)	P
History of alcohol use					0.057
Never	7 (35%)	4 (20%)	2 (10%)	7 (35%)	
Former	1 (5%)	1 (5%)	5 (25%)	7 (35%)	
Current	12 (60%)	15 (75%)	13 (65%)	6 (30%)	
Hypertension					0.290
Yes	8 (40%)	8 (40%)	8 (40%)	8 (40%)	
No	12 (60%)	12 (60%)	12 (60%)	12 (60%)	
Diabetes					0.094
Yes	5 (25%)	2 (10%)	0 (0%)	2 (10%)	
No	15 (75%)	18 (90%)	20 (100%)	18 (90%)	
Coronary heart disease					0.249
Yes	2 (10%)	1 (5%)	2 (10%)	5 (25%)	
No	18 (90%)	19 (95%)	18 (90%)	15 (75%)	
COPD					0.774
Yes	2 (10%)	2 (10%)	1 (5%)	2 (10%)	
No	18 (90%)	18 (90%)	19 (95%)	18 (90%)	
Chronic pain					0.926
Yes	2 (10%)	1 (5%)	2 (10%)	2 (10%)	
No	18 (90%)	19 (95%)	18 (90%)	18 (90%)	
Duration of anesthesia, min	163.9 (47.5)	152.6 (39.5)	172.2 (47.8)	166.4 (57.0)	0.760
Duration of surgery, min	121.4 (44.6)	108.0 (32.5)	127.3 (46.6)	126.4 (53.1)	0.680
Intraoperative blood loss, mL	50.0 (20.0–50.0)	50.0 (20.0–50.0)	50.0 (20.0–87.5)	50.0 (20.0–50.0)	0.994

**Notes:** Data are presented as mean (SD), median (IQR) or number (percentage).

**Abbreviations:** ASA, American Society of Anesthesiologists; BMI, body mass index; NRS, Numeric Rating Scale; COPD, Chronic obstructive pulmonary disease; R, ropivacaine; RM, ropivacaine+dexmedetomidine; RS, ropivacaine+dexamethasone; RSM, ropivacaine+dexamethasone+dexmedetomidine.

**Table 2** Primary and Secondary Outcomes

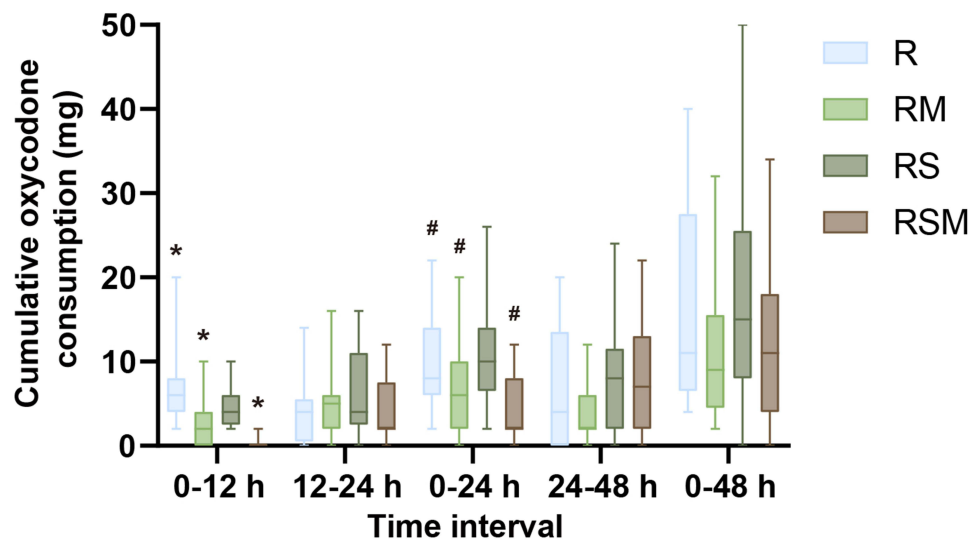
	R (n=20)	RM (n=20)	RS (n=20)	RSM (n=20)	P
Duration of analgesia, min	154.5 (80.5–199.3)	600.0 (351.0–1105.8)	282.0 (195.3–350.0)	1073.5 (932.0–1283.3)	< 0.001
Remifentanyl consumption, mg	0.8 (0.3–1.1)	0.6 (0.3–0.9)	0.8 (0.3–1.0)	0.8 (0.6–1.1)	0.242
Time to first ambulation, hour	46.5 (43.4–52.3)	42.0 (26.6–46.4)	43.6 (27.0–46.9)	42.7 (24.4–51.1)	0.057
Length of hospital stay, day	10.1 (9.0–13.8)	11.0 (9.0–13.8)	11.0 (9.0–13.0)	12.0 (9.3–14.8)	0.720

**Notes:** Data are presented as median (IQR).

**Abbreviations:** R, ropivacaine; RM, ropivacaine+dexmedetomidine; RS, ropivacaine+dexamethasone; RSM, ropivacaine+dexamethasone+dexmedetomidine.

was also significantly lower than that in the R group [8 mg (6–14),  $P < 0.05$ ]. There were no statistically significant differences in the cumulative oxycodone consumption between groups at other time points postoperatively ( $P > 0.05$ ) (Figure 2). Pain scores for resting and coughing at postoperative 1 hours, 3 hours, 6 hours, 12 hours, 24 hours, and 48 hours for patients having VATS ( $P = 0.765$ ,  $P = 0.522$ ,  $P = 0.207$ ,  $P = 0.397$ ,  $P = 0.577$ ,  $P = 0.119$ , respectively) (Figure 3) were similar in the four groups. The number of patients experiencing adverse effects is presented in Table 3. The incidence of nausea within 48 hours postoperatively in the RSM group (15%) was lower than that in the RM group (60%,  $P < 0.05$ ). No significant differences were observed in the incidences of hypotension, vomiting, dizziness, drowsiness, or pruritus among the four groups ( $P > 0.05$ ). No rescue analgesia measures were implemented in any of the patient cohorts.





**Figure 2** The cumulative oxycodone consumption at intervals of 0–12 hours, 12–24 hours, 0–24 hours, and 24–48 hours following the surgical procedure. During 0–12 hours postoperatively, \* $P < 0.001$ , group R compared with groups RM and RSM. During 0–24 hours postoperatively, # $P < 0.05$ , group R compared with groups RM and RSM.

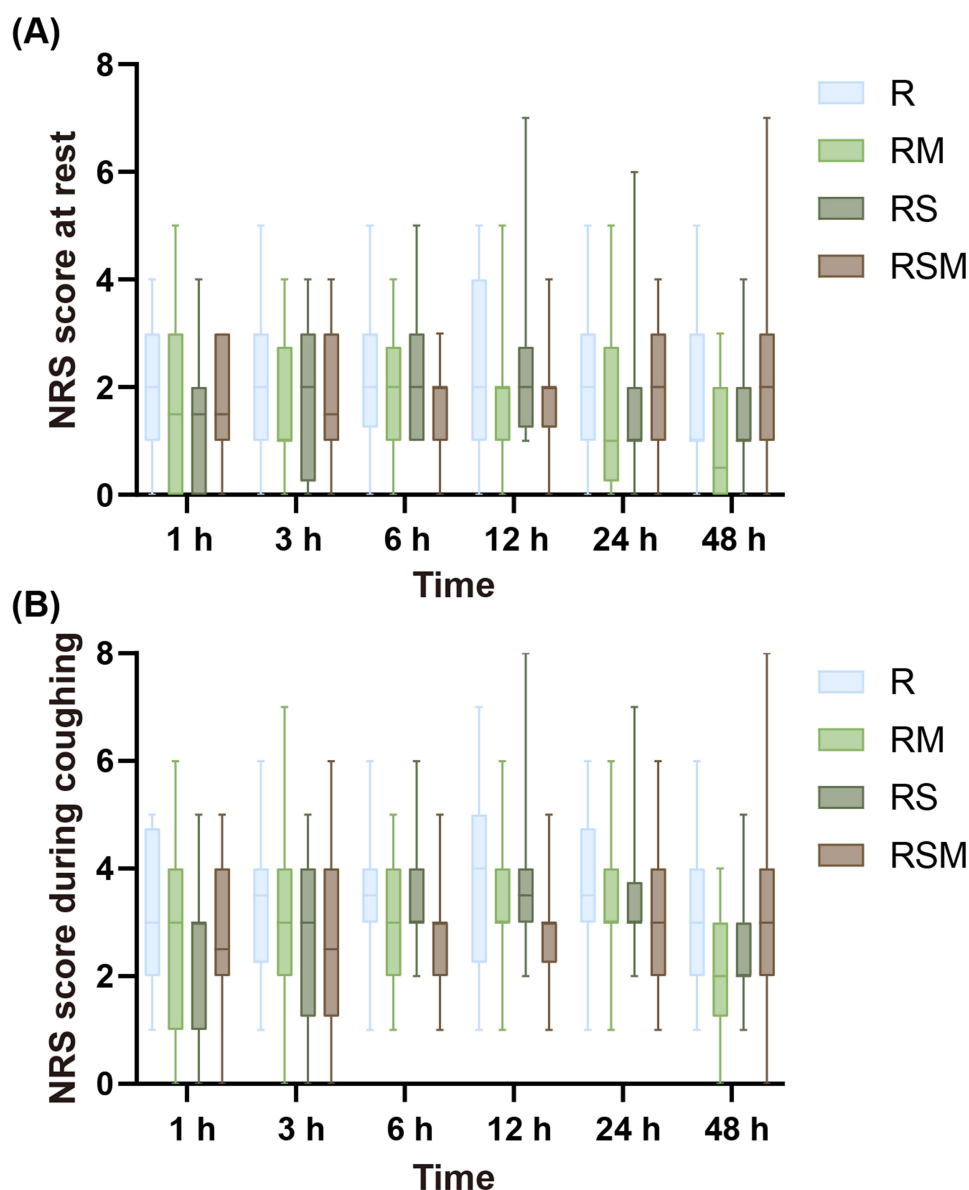
**Abbreviations:** R, ropivacaine; RM, ropivacaine+dexmedetomidine; RS, ropivacaine+dexamethasone; RSM, ropivacaine+dexmedetomidine+dexamethasone.

## Discussion

In this study, we demonstrated that the combination of ropivacaine with dexamethasone and dexmedetomidine as adjuvants in the RISS block for VATS exhibited superior efficacy compared to either ropivacaine combined with dexamethasone alone or ropivacaine alone. Furthermore, this combination significantly prolonged the duration of analgesia, reduced postoperative oxycodone consumption, and decreased the incidence of nausea within 48 hours after surgery.

The occurrence of acute postoperative pain following VATS is not uncommon and can be attributed to multiple muscle incisions, rib manipulation, and chest tube irritation of the pleura. A retrospective study involving 1164 adult patients undergoing VATS reported a 15.7% incidence of moderate to severe postoperative pain within 48 hours.<sup>18</sup> Another prospective clinical trial revealed no statistically significant disparity in pain scores during the initial 12-month period following surgery between VATS and open thoracotomy.<sup>19</sup> RISS block proves comparatively simpler from a technical standpoint, which includes patient positioning precision along with landmark identification (scapular border) while facilitating optimal dispersion of local anesthetic amidst interfascial planes involving rhomboid major or serratus anterior muscles juxtaposed against external intercostal muscle.<sup>4</sup>

In upper limb surgery, the utilization of ultrasound-guided infraclavicular brachial plexus block with a combination of dexmedetomidine and dexamethasone has demonstrated significant prolongation of both sensory and motor blocks, as well as extension of the duration of analgesia.<sup>20</sup> Moreover, recent studies have shown that the combination of dexmedetomidine and dexamethasone for intercostal nerve block can further prolong the duration of analgesia after VATS.<sup>12</sup> Our study also revealed that the application of ultrasound-guided RISS block with dexmedetomidine and dexamethasone substantially extends the duration of analgesia in patients undergoing VATS. Compared to the R group, the RSM group exhibited an almost six-fold increase in the duration of analgesia, while the RM group alone showed an approximately three-fold increase. Yang J et al have demonstrated that the combination of ropivacaine and dexamethasone in a Thoracic Paravertebral Nerve Block, along with an Erector Spinae Plane Block for VATS, can significantly prolong the duration of postoperative analgesia.<sup>21</sup> Although not statistically significant compared to the R group, there was still a trend toward prolonged duration of analgesia observed in the RS group alone. Moreover, although the difference between the RSM group and the RM group alone did not reach statistical significance, there was still a tendency in favor of prolonging the duration of the first analgesia observed in the RSM group. These observations



**Figure 3** Pain at rest and when coughing postoperatively. (A) NRS scores at rest at 1, 3, 6, 12, 24, and 48 hours postoperatively. (B) NRS scores during coughing at 1, 3, 6, 12, 24, and 48 hours postoperatively.

**Abbreviations:** NRS, numeric rating scale; R, ropivacaine; RM, ropivacaine+dexmedetomidine; RS, ropivacaine+dexamethasone; RSM, ropivacaine+dexmedetomidine+dexamethasone.

may be attributed to limitations associated with a relatively small sample size. Therefore, further studies with larger sample sizes are warranted for validation.

The duration of analgesia in the RA group did not show significant differences compared to that in the RM group. These findings contradict those reported by Kataria et al, who demonstrated that a combination of 8 mg dexamethasone + 20 mL 0.5% ropivacaine is more effective than using 0.5 µg/kg dexmedetomidine + 20 mL 0.5% ropivacaine for ultrasound-guided interscalene block after shoulder arthroscopy.<sup>22</sup> A meta-analysis comparing dexamethasone and dexmedetomidine for supraclavicular brachial plexus block also revealed that perineural administration of dexamethasone resulted in a significantly prolonged duration of analgesia compared to dexmedetomidine, with an additional 2.5 hours, while maintaining comparable risks of extended motor blockade, hypotension, or sedation.<sup>23</sup> This observation may be attributed to variations in adjuvant dosages across experimental settings and the stimulation of the thoracic duct. Perineural administration of dexamethasone does not necessarily augment the analgesic effects with increasing



**Table 3** Adverse Effects

	R (n=20)	RM (n=20)	RS (n=20)	RSM (n=20)	P
Hypotension	0 (0%)	1 (5%)	2 (10%)	2 (10%)	0.504
Nausea	7 (35%)	12 (60%)	6 (30%)	3 (15%)	0.026
Vomiting	4 (20%)	8 (40%)	3 (15%)	3 (15%)	0.181
Dizziness	7 (35%)	8 (40%)	4 (20%)	5 (25%)	0.497
Drowsiness	7 (35%)	7 (35%)	7 (35%)	5 (25%)	0.877
Pruritus	2 (10%)	1 (5%)	1 (5%)	1 (5%)	0.887

**Notes:** Data are presented as number (percentage).

**Abbreviations:** R, ropivacaine; RM, ropivacaine+dexmedetomidine; RS, ropivacaine+dexamethasone; RSM, ropivacaine+dexamethasone+dexmedetomidine.

doses.<sup>24,25</sup> The dose range of 4–8 mg dexamethasone is commonly employed for regional anesthesia indications and exhibits a relatively limited incidence of systemic side effects.<sup>26</sup> The administration of dexmedetomidine is determined by either weight-based dosing (0.75–1.0 µg/kg) or a fixed dose range (10–150 µg).<sup>27</sup> Currently, there is a dearth of relevant research investigating the optimal dosages of dexamethasone and dexmedetomidine for RISS block during thoracoscopic surgery, necessitating further exploration to ascertain precise dosage regimens.

A retrospective study revealed that the implementation of ultrasound-guided transversus abdominis plane block with a combination of dexmedetomidine and dexamethasone effectively reduces opioid consumption following laparoscopic colorectal surgery.<sup>28</sup> In this study, the RSM group exhibited significantly reduced cumulative oxycodone consumption at 0–12 hours and 0–24 hours post-surgery, aligning with findings from prior research studies. The results of a randomized controlled trial revealed that the combination of ropivacaine with either dexmedetomidine or dexamethasone in thoracic paravertebral nerve block, along with eriospinal surface block, led to a significant reduction in postoperative NRS scores following VAST.<sup>21</sup> In this study, there were no significant differences in postoperative resting and coughing NRS scores among the four groups of patients. Similarly, a study investigating the analgesic duration of ultrasound-guided interscalene brachial plexus block with 0.5% ropivacaine supplemented with either dexmedetomidine or dexamethasone as adjuvants found no statistically significant differences in postoperative 24-hour NRS scores between the control group, dexamethasone-alone group, and dexmedetomidine-alone group, which is consistent with our findings.<sup>29</sup> The data demonstrated that median NRS scores at 1 hour, 3 hours, 6 hours, 12 hours, 24 hours, and 48 hours postoperatively for both resting and coughing were below a threshold of three and four respectively. This indicates that irrespective of the adjuvant used, the multimodal analgesic approach employed in this study effectively managed postoperative pain; thus lack of observed differences may be associated with the consumption of opioid drugs within 0–24 hours postoperatively.

Ding et al discovered that the early ambulation time for lung cancer patients undergoing thoracoscopy was  $34.18 \pm 17.18$  hours, with 33 cases having their first ambulation time exceeding 48 hours, accounting for 14.6%.<sup>30</sup> There was no significant difference in the time to first ambulation among the four groups of patients in this study; however, a higher proportion (27.5%) of patients had their time to first ambulation after surgery exceeding 48 hours. The primary determinants of early postoperative ambulation in patients undergoing thoracic surgery include factors such as stimulation from the thoracic catheter, catheterization, and postoperative pain. In this study, there was no difference in the length of hospital stay among the four groups, possibly because there was no difference in the postoperative NRS score and the time to first ambulation. In addition, there were other factors affecting the length of hospital stays such as preoperative complications, chest drainage tubes, and postoperative complications.<sup>31</sup> Zhang P et al and Yang J et al did not observe a reduction in postoperative nausea with the use of dexmedetomidine or dexamethasone in combination with ropivacaine for nerve block in VAST patients.<sup>12,21</sup> However, we found that the combination of dexmedetomidine and dexamethasone for RISS block can effectively reduce the incidence of postoperative nausea in VATS patients. The occurrence of postoperative nausea is mainly associated with the use of opioid drugs. Oxycodone is a semi-synthetic opioid drug commonly used for its analgesic properties. In this study, the cumulative oxycodone consumption within 0–12 hours and 0–24 hours postoperatively in the RSM group was significantly less than the other three groups, which may be the primary reason for the lower incidence of postoperative nausea in the RSM group compared to the other three groups.

## Limitations

First, we did not confirm the RISS block effectiveness with sensory level testing after local anesthetic injection. However, we instead observed the spread patterns of the local anesthetic on ultrasound to reinforce the optimal diffusion of the local anesthetic and ensure enhanced efficacy. Second, no group received intravenous dexamethasone, intravenous dexmedetomidine, or a combination of both via intravenous administration. The role of the intravenous combination of dexmedetomidine and dexamethasone as well as the efficacy of intravenous administration remains controversial,<sup>32,33</sup> necessitating further research to explore potential disparities in effectiveness between combining intravenous dexmedetomidine with dexamethasone and peripheral nerve administration of this combination. Third, the number of female patients in the RSM group was lower compared to the other three groups in this study. Females are recognized as risk factors for both postoperative acute pain and analgesic usage after surgery. The smaller representation of females within the RSM group may potentially influence our research findings. However, we conducted additional analyses to compare the duration of analgesia between males and females within each group, as well as across all patients collectively (Supplementary Table 2). We also assessed whether there were any gender disparities in cumulative oxycodone consumption during both 0–12 hours and 0–24 hours after surgery periods. Our results indicated no statistically significant differences, suggesting that this gender discrepancy did not impact our research outcomes. Finally, the sample size calculation was based on the results of intercostal muscle blockade, which is inconsistent with the intervention method used in our study, potentially leading to inaccurate sample size calculation. However, both RISS block and intercostal nerve block can be effectively used for thoracic surgery analgesia with comparable effects.

## Conclusions

We have demonstrated that the coadministration of 0.375% ropivacaine with 8 mg of dexamethasone and 1 µg/kg of dexmedetomidine for RISS block in patients undergoing VATS significantly extends the duration of analgesia and reduces postoperative oxycodone consumption.

## Data Sharing Statement

The data generated during the current study are available from the corresponding author (Qing-Ren Liu) upon reasonable request. The study protocol, statistical analysis plan, and clinical study report will also be available.

## Acknowledgments

The authors thank all the members of the Thoracic Surgery Department (The Second Affiliated Hospital of Nanjing Medical University, Nanjing, Jiangsu Province, China; Xishan People's Hospital of Wuxi City, Wuxi, Jiangsu Province, China) for their great help and support. This work was supported by the Wuxi City Commission of Health (Grant No M202219) and the Top Talent Support Program for Young and Middle-aged People of Wuxi Health Committee (HB2023114).

## Disclosure

The authors report no conflicts of interest related to this work.

## References

1. Vannucci F, Gonzalez-Rivas D. Is VATS lobectomy standard of care for operable non-small cell lung cancer? *Lung Cancer*. 2016;100:114–119. doi:10.1016/j.lungcan.2016.08.004
2. Berfield KS, Farjah F, Mulligan MS. Video-assisted thoracoscopic lobectomy for lung cancer. *Ann Thorac Surg*. 2019;107(2):603–609. doi:10.1016/j.athoracsur.2018.07.088
3. Elsharkawy H, Saifullah T, Kolli S, et al. Rhomboid intercostal block. *Anaesthesia*. 2016;71(7):856–857. doi:10.1111/anae.13498
4. Elsharkawy H, Hamadnalla H, Altinpulluk EY, et al. Rhomboid intercostal and subscapular plane block -A case series. *Korean J Anesthesiol*. 2020;73(6):550–556. doi:10.4097/kja.19479
5. Longo F, Piliego C, Martuscelli M, et al. Rhomboid intercostal and subscapular plane block for intubated uniportal video-assisted thoracoscopic surgery lobectomy. *J Clin Anesth*. 2020;65:109881. doi:10.1016/j.jclinane.2020.109881
6. Kozanhan B, Semerkant T, Esme H, et al. Efficacy of rhomboid intercostal and subscapular plane block performed under direct vision on postoperative pain after thoracotomy. *J Clin Anesth*. 2019;58:95–97. doi:10.1016/j.jclinane.2019.05.021

7. Elsharkawy H, Ince I, Pawa A. Rhomboid intercostal and sub-serratus (RISS) plane block for analgesia after lung transplant. *J Clin Anesth.* 2019;56:85–87. doi:10.1016/j.jclinane.2019.01.042
8. Yayik AM, Aydin ME, Tekin E, et al. An alternative plane block for multiple rib fractures: rhomboid Intercostal and Sub-Serratus block (RISS). *Am J Emerg Med.* 2019;37(12):2263.e5–2263.e7. doi:10.1016/j.ajem.2019.158429
9. Deng W, Hou XM, Zhou XY, et al. Rhomboid intercostal block combined with sub-serratus plane block versus rhomboid intercostal block for postoperative analgesia after video-assisted thoracoscopic surgery: a prospective randomized-controlled trial. *BMC Pulm Med.* 2021;21(1):68. doi:10.1186/s12890-021-01432-7
10. Rancourt MP, Albert NT, Côté M, et al. Posterior tibial nerve sensory blockade duration prolonged by adding dexmedetomidine to ropivacaine. *Anesth Analg.* 2012;115(4):958–962. doi:10.1213/ANE.0b013e318265bab7
11. Kim YS, Park Y, Koh HJ. Is there a difference between perineural dexamethasone with single-shot interscalene block (SSIB) and interscalene indwelling catheter analgesia (IICA) for early pain after arthroscopic rotator cuff repair? A pilot study. *J Clin Med.* 2022;11(12):3409. doi:10.3390/jcm11123409
12. Zhang P, Liu S, Zhu J, et al. Dexamethasone and dexmedetomidine as adjuvants to local anesthetic mixture in intercostal nerve block for thoracoscopic pneumonectomy: a prospective randomized study. *Reg Anesth Pain Med.* 2019;44(10):917–922. doi:10.1136/rapm-2018-100221
13. Sakae TM, Marchioro P, Schuelter-Trevisol F, et al. Dexamethasone as a ropivacaine adjuvant for ultrasound-guided interscalene brachial plexus block: a randomized, double-blinded clinical trial. *J Clin Anesth.* 2017;38:133–136. doi:10.1016/j.jclinane.2017.02.004
14. Seidenari S, Di Nardo A, Mantovani L, et al. Parallel intraindividual evaluation of the vasoconstrictory action and the anti-allergic activity of topical corticosteroids. *Exp Dermatol.* 1997;6(2):75–80. doi:10.1111/j.1600-0625.1997.tb00150.x
15. Talke P, Stapelfeldt C, Lobo E, et al. Effect of alpha2B-adrenoceptor polymorphism on peripheral vasoconstriction in healthy volunteers. *Anesthesiology.* 2005;102(3):536–542. doi:10.1097/0000542-200503000-00010
16. Wang K, Wang LJ, Yang T, et al. Dexmedetomidine combined with local anesthetics in thoracic paravertebral block: a systematic review and meta-analysis of randomized controlled trials. *Medicine (Baltimore).* 2018;97(46):e13164. doi:10.1097/MD.00000000000013164
17. Zha J, Ji S, Wang C, et al. Thoracic paravertebral nerve block with ropivacaine and adjuvant dexmedetomidine produced longer analgesia in patients undergoing video-assisted thoracoscopic lobectomy: a randomized trial. *J Healthc Eng.* 2021;2021:1846886. doi:10.1155/2021/1846886
18. Sun K, Liu D, Chen J, et al. Moderate-severe postoperative pain in patients undergoing video-assisted thoracoscopic surgery: a retrospective study. *Sci Rep.* 2020;10(1):795. doi:10.1038/s41598-020-57620-8
19. Rizk NP, Ghanie A, Hsu M, et al. A prospective trial comparing pain and quality of life measures after anatomic lung resection using thoracoscopy or thoracotomy. *Ann Thorac Surg.* 2014;98(4):1160–1166. doi:10.1016/j.athoracsurg.2014.05.028
20. Aliste J, Layera S, Bravo D, et al. Randomized comparison between perineural dexamethasone and combined perineural dexamethasone-dexmedetomidine for ultrasound-guided infraclavicular block. *Reg Anesth Pain Med.* 2022;47(9):554–559. doi:10.1136/rapm-2022-103760
21. Yang J, Zhao M, Zhang XR, et al. Ropivacaine with dexmedetomidine or dexamethasone in a thoracic paravertebral nerve block combined with an erector spinae plane block for thoracoscopic lobectomy analgesia: a randomized controlled trial [published correction appears in drug des devel ther. *Drug Des Devel Ther.* 2022;16:1561–1571. doi:10.2147/DDDT.S366428
22. Kataria S, Mitra S, Saroa R, et al. A randomized double blinded trial comparing dexmedetomidine with dexamethasone as an adjunct to ropivacaine in ultrasound guided interscalene block for arthroscopic shoulder surgery. *Asian J Anesthesiol.* 2019;57(1):10–18. doi:10.6859/aja.201903\_57(1).0003
23. Albrecht E, Vorobeichik L, Jacot-Guillarmod A, et al. Dexamethasone is superior to dexmedetomidine as a perineural adjunct for supraclavicular brachial plexus block: systematic review and indirect meta-analysis. *Anesth Analg.* 2019;128(3):543–554. doi:10.1213/ANE.0000000000003860
24. Tandoc MN, Fan L, Kolesnikov S, et al. Adjuvant dexamethasone with bupivacaine prolongs the duration of interscalene block: a prospective randomized trial. *J Anesth.* 2011;25(5):704–709. doi:10.1007/s00540-011-1180-x
25. Liu J, Richman KA, Grodofsky SR, et al. Is there a dose response of dexamethasone as adjuvant for supraclavicular brachial plexus nerve block? A prospective randomized double-blinded clinical study. *J Clin Anesth.* 2015;27(3):237–242. doi:10.1016/j.jclinane.2014.12.004
26. Heesen M, Rijs K, Hilber N, et al. Effect of intravenous dexamethasone on postoperative pain after spinal anaesthesia - A systematic review with meta-analysis and trial sequential analysis. *Anaesthesia.* 2019;74(8):1047–1056. doi:10.1111/anae.14666
27. Vorobeichik L, Brull R, Abdallah FW. Evidence basis for using perineural dexmedetomidine to enhance the quality of brachial plexus nerve blocks: a systematic review and meta-analysis of randomized controlled trials. *Br J Anaesth.* 2017;118(2):167–181. doi:10.1093/bja/aew411
28. Chapman BC, Shepherd B, Moore R, et al. Dual adjunct therapy with dexamethasone and dexmedetomidine in transversus abdominis plane blocks reduces postoperative opioid use in colorectal surgery. *Am J Surg.* 2021;222(1):198–202. doi:10.1016/j.amjsurg.2020.09.027
29. Margulis R, Francis J, Tischenkel B, et al. Comparison of dexmedetomidine and dexamethasone as adjuvants to ultra-sound guided interscalene block in arthroscopic shoulder surgery: a double-blinded randomized placebo-controlled study. *Anesth Pain Med.* 2021;11(3):e117020. doi:10.5812/aapm.117020
30. Ding X, Zhang H, Liu H. Early ambulation and postoperative recovery of patients with lung cancer under thoracoscopic surgery-an observational study. *J Cardiothorac Surg.* 2023;18(1):136. doi:10.1186/s13019-023-02263-9
31. Huang L, Kehlet H, Petersen RH. Reasons for staying in hospital after video-assisted thoracoscopic surgery lobectomy. *BJS Open.* 2022;6(3):zrac050. doi:10.1093/bjsopen/zrac050
32. Kang RA, Jeong JS, Yoo JC, et al. Improvement in postoperative pain control by combined use of intravenous dexamethasone with intravenous dexmedetomidine after interscalene brachial plexus block for arthroscopic shoulder surgery: a randomised controlled trial. *Eur J Anaesthesiol.* 2019;36(5):360–368. doi:10.1097/EJA.0000000000000977
33. Maagaard M, Funder KS, Schou NK, et al. Combined dexamethasone and dexmedetomidine as adjuncts to popliteal and saphenous nerve blocks in patients undergoing surgery of the foot or ankle: a randomized, blinded, placebo-controlled, clinical trial. *Anesthesiology.* 2024;140(6):1165–1175. doi:10.1097/ALN.0000000000004977

Drug Design, Development and Therapy

Dovepress

## Publish your work in this journal

Drug Design, Development and Therapy is an international, peer-reviewed open-access journal that spans the spectrum of drug design and development through to clinical applications. Clinical outcomes, patient safety, and programs for the development and effective, safe, and sustained use of medicines are a feature of the journal, which has also been accepted for indexing on PubMed Central. The manuscript management system is completely online and includes a very quick and fair peer-review system, which is all easy to use. Visit <http://www.dovepress.com/testimonials.php> to read real quotes from published authors.

Submit your manuscript here: <https://www.dovepress.com/drug-design-development-and-therapy-journal>