


The Cerebellum–Ventral Tegmental Area Microcircuit and Its Implications for Autism Spectrum Disorder: A Narrative Review

Peiling Zhou¹, Shiyu Peng², Sizhe Wen¹, Qinghui Lan¹, Yingyin Zhuang¹, Xuyan Li¹, Mengliang Shi^{1,3}, Changzheng Zhang¹ 

¹Guangdong Provincial Key Laboratory of Development and Education for Special Needs Children & School of Educational Sciences, Lingnan Normal University, Zhanjiang, 524048, People's Republic of China; ²Shanghai Key Laboratory of Psychotic Disorders, Shanghai Mental Health Center, Shanghai Jiaotong University School of Medicine, Shanghai, People's Republic of China; ³School of Education, South China Normal University, Guangzhou, 510631, People's Republic of China

Correspondence: Changzheng Zhang, School of Educational Sciences, Lingnan Normal University, 29 Cunjin Road, Zhanjiang, Guangdong Province, 524048, People's Republic of China, Email neurozhang@163.com; Mengliang Shi, School of Education, South China Normal University, 55 West Zhongshan Avenue, Shipai Street, Guangzhou, Guangdong Province, 510631, People's Republic of China, Email 20240169@m.scnu.edu.cn

Abstract: The cerebellum has long been implicated in the etiopathogenesis of autism spectrum disorder (ASD), and emerging evidence suggests a significant contribution by reciprocal neural circuits between the cerebellum and ventral tegmental area (VTA) in symptom expression. This review provides a concise overview of morphological and functional alterations in the cerebellum and VTA associated with ASD symptoms, primarily focusing on human studies while also integrating mechanistic insights from animal models. We propose that cerebello–VTA circuit dysfunction is a major contributor to ASD symptoms and that these circuits are promising targets for drugs and therapeutic brain stimulation methods.

Keywords: autism spectrum disorder, cerebellum, ventral tegmental area, neural circuit

Introduction

Autism spectrum disorder (ASD) encompasses a cluster of neurodevelopmental disabilities characterized by challenges in social interactions, difficulties in verbal and non-verbal communication, and restricted/stereotyped patterns of behavior, activities, and interests. Multiple epidemiological studies have documented a dramatic increase in ASD prevalence over the past few decades, and current estimates suggest that ASD afflicts 1–2% of children globally.^{1–3} Regrettably, existing treatments are of limited efficacy for mitigating the core symptoms of ASD. For instance, several recent reports suggest that neither pharmacotherapies nor behavioral interventions can substantially improve social skills or suppress stereotyped behaviors in most patients with ASD.^{4,5} Consequently, a substantial number of ASD patients require extensive lifelong medical and social support, imposing considerable stress and financial strain on families and healthcare systems.^{6–8}

The cerebellum has been the focus of ASD research for several decades due to numerous reports of morphological and histological abnormalities associated with autistic phenotypes such as communication deficits, social dysfunction, and repetitive behaviors.⁹ Recent studies also suggest that dysfunctional dopaminergic signaling from the ventral tegmental area (VTA) may contribute to certain autistic traits.^{10,11} Despite the strong functional connectivity between the cerebellum and VTA, the contributions of cerebello–VTA circuit dysfunction to ASD development and symptoms remain largely unexplored. This narrative review seeks to provide a better understanding of cerebello–VTA interactions related to ASD, thereby providing support for these circuits as novel targets for intervention.

Cerebellar Alterations in ASD Patients

A myriad of studies using different designs and research methods have reported abnormalities in regional cerebellar structure and function associated with autistic traits ([Supplementary Table](#)). For instance, children with ASD were reported to exhibit significantly diminished structural complexity in the right cerebellar cortex marked by flatter and less regular surface protrusions; further, these abnormalities were associated with reduced social interactions.¹² However, both the causes of these abnormalities in cerebellar development and the impacts on specific ASD symptoms remain unknown.

Volumetric Changes

Multiple studies have reported differences in regional cerebellar volumes among patients with ASD compared to typically developing (TD) controls. However, reported changes include both decreases (atrophy)^{13,14} and increases,¹⁵ while several others have found no significant changes.^{16–19} One prevailing theory posits that early cerebellar development is accelerated in infants with suspected ASD, followed by deceleration in growth rate, ultimately resulting in a smaller volume by adulthood.²⁰ Moreover, distinct subregions of the cerebellum display varying degrees of volumetric change in ASD patients.^{21,22} Of particular note, several morphometric studies have noted hypoplasia in the Crus I/II strongly associated with the severity of core ASD symptoms such as social deficits, communication difficulties, and repetitive behaviors.^{23–26}

Cell Type-Specific Changes in Autistic Cerebellum

The cerebellum contains the largest number of neurons in the central nervous system, and these numbers are frequently altered in ASD. Further, multiple cell types may be differentially altered in specific regions, underscoring the complex neurobiology of the disorder.

Purkinje Cells

Purkinje cells (PCs) are the exclusive output neurons of the cerebellar cortex, projecting predominantly to three bilateral deep cerebellar nuclei (DCN), the fastigial nuclei (FN), interpositus nuclei (IN, including emboliform and globose nuclei), and dentate nuclei (DN). It is widely reported that the number of PCs is reduced in patients with ASD.^{19,27–30} However, some studies have reported no significant reduction in PC density among autistic individuals.^{31,32} These discrepancies may reflect regional heterogeneity, differences among developmental stages, and (or) the use of different measurement techniques. For example, no decrease was reported in lobule X, while moderate reductions were found in lobules IV–VI, pronounced reductions in the vermis, and greatest reductions in Crus I/II.^{27,32,33} Further, an initial increase was found during the earlier postnatal days followed by a dramatic decrease in an ASD mouse model.³⁴ Finally, various histological techniques and quantitative methodologies may introduce unique biases contributing to inconsistent outcomes across studies.^{35,36} Nonetheless, it appears that greatest PC loss occurs in Crus I/II among patients with ASD.³³ In summary, while there is compelling evidence for region-specific PC loss and cortical atrophy within the autistic cerebellum,^{31,37} it remains uncertain how and why such ultrastructural changes manifest as ASD symptoms.

Granule Cells

While one study reported no detectable loss of granule cells among patients with ASD,¹⁹ several others have found significant reductions in granule cell numbers.^{27,29,30,35} Moreover, a mouse model carrying a mutation in the ASD-linked gene *Engrailed2* specifically within granule cells exhibited cerebellar pathology associated with multiple ASD-related behaviors.³⁸

Golgi Cells

One study reported heightened immunoreactivity of antibodies targeting a cerebellar-specific protein of approximately 52 kDa in Golgi cells of the autistic cerebellum compared to the healthy individuals.³⁹

Basket Cells and Stellate Cells

The outputs of PCs are modulated by GABAergic basket cells and stellate cells within the cerebellar molecular layer. According to Whitney et al, the densities of basket and stellate cells per PC did not differ between autistic patients and TD controls.⁴⁰ However, despite no change in total interneuron number, Yip et al reported significant upregulation of GAD67 mRNA specifically within basket cells and a slight increase in stellate cells among ASD patients,³⁶ suggesting reorganization of GABAergic input to PCs and ensuing alterations in PC output patterns.

Glial cells

Greater reactivity of Bergmann glia, microglia, and astrocytes has been reported in the cerebellum of ASD patients,^{19,30} suggesting potential influences on synaptic transmission, neuronal metabolism, and the immune milieu. Further, investigation of changes in other glial cells, such as oligodendrocytes, are warranted to examine the impacts on neurotransmission within cerebellar circuits.

Neurons in Deep Cerebellar Nuclei

Significant neuronal loss has also been observed in the FN and IN but not the DN of ASD patients.²⁹ However, dysmorphic DN neurons have been found in ASD patients.²⁹ Yip et al reported a marked decrease in GAD65 mRNA expression within GABAergic neurons of the DN among patients with autism, suggesting significant effects on the temporal pattern and magnitude of cerebellar outputs.⁴¹

Collectively, these structural and functional alterations in cerebellar neurons, particularly of PCs, suggest marked changes in cerebellar circuit transmission, integration, plasticity, and output patterns in response to cerebellar inputs. Further study is required to describe these changes in input–output functions and associated influences on ASD-relevant behaviors.

Changes in Cerebello–VTA Microcircuits

Cerebellar Projections to the VTA

Early studies utilizing classical anterograde and retrograde tracing techniques revealed that all three DCN project to the VTA in both humans and animals (Figure 1), although with distinct patterns. According to these studies, the largest number of projections originates from the contralateral DN, followed by the IN, while relatively few

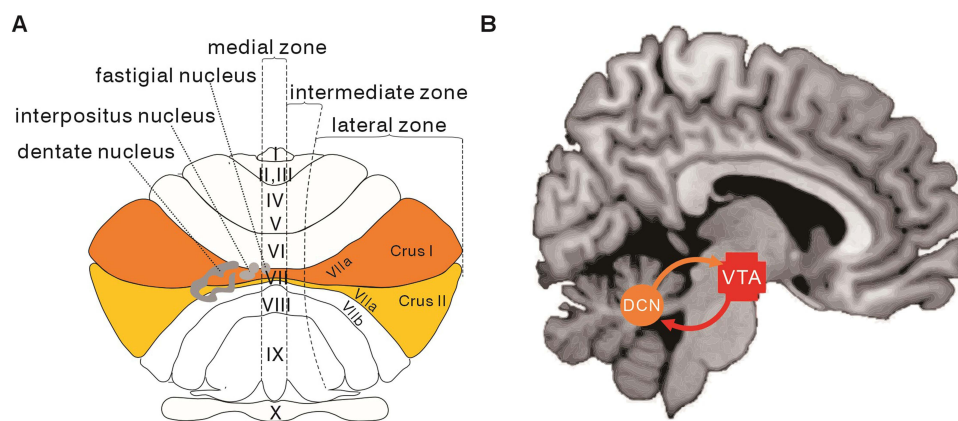


Figure 1 Depiction of cerebellar anatomy and connections with the ventral tegmental area (VTA). **(A)** Dorsal view of the cerebellum showing the numerically labeled lobules within the vermis. Crus I and II are major sites of VTA inputs (highlighted with colored overlays). **(B)** Anatomical representation of the bidirectional connections between the deep cerebellar nuclei (DCN) and the VTA based on brain magnetic resonance imaging. Adapted from Esslinger C, Braun U, Schirmbeck F et al. Activation of midbrain and ventral striatal regions implicates salience processing during a modified beads task. *PLoS ONE*. 2013; 8(3):e58536. Creative Commons.⁴²

originate from the FN.⁴³ However, others have also identified DCN projections to the ipsilateral VTA.^{44,45} Findings on the reciprocal connections between the cerebellum and VTA are summarized in Table 1.

Recently, synaptic anterograde/retrograde viral tracing in transgenic mouse lines has provided precise insights into these mutual connections. However, there is still disagreement among studies regarding the origins of DCN projections and the cell types involved. For instance, Baek et al reported abundant projections from the DN, fewer from the IN, and none from the FN to the VTA, whereas another study identified direct projections from the FN to the VTA using trans-synaptic anterograde tracing in mice.⁶⁰ A recent human study further reported that all DCN project to the VTA, with the IN contributing the largest number.⁴⁷ Moreover, multiple animal studies have found that cerebellar outputs from the three DCN target both dopaminergic neurons and non-dopaminergic neurons in the VTA.^{11,55,59,61}

Table 1 Summary of Studies Investigating Reciprocal Connectivity Between the VTA and Cerebellum

Connection	Species	Methodology	Principal Results	References
CC → VTA	Rats and cats	HRP retrograde tracing	Vermis → ipsilateral VTA?	Snider, 1976 ⁴⁶
	Humans	DWI and probabilistic tractography	Paravermis → mostly ipsilateral VTA (with predominance from the right hemisphere)	Hoffman, 2024 ⁴⁷
	Mice	AAV anterograde tracing, AAV-retro and Fast Blue retrograde tracing	Vermian lobule IX → ipsilateral VTA	Hashimoto, 2018 ⁴⁸
VTA → CC	Rats	Fluoro-Gold retrograde tracing and Cholera toxin anterograde tracing	VTA → bilateral CC (with contralateral predominance)	Ikai, 1992 ⁴⁵
	Rats	Fast Blue retrograde tracing	VTA → bilateral CC (Crus I, with contralateral predominance)	Ikai, 1994 ⁴⁹
	Mice	AAV retrograde tracing	No VTA → CC	Wagner, 2017 ⁵⁰
	Mice	AAV/Dextran anterograde tracing, and Retrobead retrograde tracing	No VTA → CC	Li, 2023 ⁵¹
DN → VTA	Rats and cats	HRP retrograde tracing	DN → primarily contralateral VTA	Snider, 1976 ⁴⁶
	Rats	HRP retrograde tracing	DN → contralateral VTA	Phillipson, 1979 ⁵²
	Rats	HRP retrograde tracing, WGA-HRP anterograde/retrograde tracing	DN → contralateral VTA	Percivalle, 1989 ⁴³
	Rats	Cholera toxin retrograde tracing	DN → bilateral VTAs (with contralateral predominance)	Ikai, 1992 ⁴⁵
	Rats	PHA-L anterograde tracing	DN → contralateral VTA	Parker, 2014 ⁵³
	Mice	AAV anterograde/retrograde tracing	DN → contralateral VTA	Baek, 2022 ⁵⁴
	Humans	DWI and probabilistic tractography	DN → mostly ipsilateral VTA (with predominance from the right hemisphere)	Hoffman, 2024 ⁴⁷
	Mice	Rabies virus retrograde tracing	DN → VTA	Watabe-Uchida, 2012 ⁵⁵
	Mice	Herpes virus anterograde tracing	DN → VTA	Carta, 2019 ¹¹
	Rats	Dextranamine anterograde tracing, Fluoro-Gold retrograde tracing	DN → contralateral VTA	Gil-Miravet, 2019 ⁵⁶
VTA → DN	Rats	Fluoro-Gold retrograde tracing and Cholera toxin anterograde tracing	VTA → bilateral DNs (with contralateral predominance)	Ikai, 1992 ⁴⁵
	Rats	Fast Blue retrograde tracing	VTA → bilateral DNs (with contralateral predominance)	Ikai, 1994 ⁴⁹

(Continued)

Table 1 (Continued).

Connection	Species	Methodology	Principal Results	References
IN → VTA	Rats and cats	HRP retrograde tracing	IN → primarily contralateral VTA	Snider, 1976 ⁴⁶
	Rats	Cholera toxin retrograde tracing	IN → bilateral VTAs (with contralateral predominance)	Ikai, 1992 ⁴⁵
	Mice	AAV anterograde tracing	IN → contralateral VTA	Judd, 2021 ⁵⁷
	Rats	Fluoro-Gold retrograde tracing	IN → contralateral VTA	Gil-Miravet, 2019 ⁵⁶
	Humans	DWI and probabilistic tractography	IN → mostly ipsilateral VTA (with predominance from the right hemisphere)	Hoffman, 2024 ⁴⁷
	Rats	HRP retrograde tracing, WGA-HRP anterograde/retrograde tracing	IN → contralateral VTA	Perciavalle, 1989 ⁴³
	Mice	Herpes virus anterograde tracing	IN → VTA	Carta, 2019 ¹¹
	Mice	AAV anterograde/retrograde tracing	IN → contralateral VTA	Baek, 2022 ⁵⁴
VTA → IN	Rats	Fluoro-Gold retrograde tracing and Cholera toxin anterograde tracing	VTA → bilateral INs (with contralateral predominance)	Ikai, 1992 ⁴⁵
FN → VTA	Rats and cats	HRP retrograde tracing	FN → primarily ipsilateral VTA	Snider, 1976 ⁴⁶
	Mice	AAV anterograde tracing	FN → contralateral VTA	Chao, 2023 ⁵⁸
	Rats	HRP retrograde tracing, WGA-HRP anterograde/retrograde tracing	None FN → VTA	Perciavalle, 1989 ⁴³
	Rats	Cholera toxin retrograde tracing	None FN → VTA	Ikai, 1992 ⁴⁵
	Mice	AAV anterograde/retrograde tracing	None FN → VTA	Baek, 2022 ⁵⁴
	Rats	Fluoro-Gold retrograde tracing	None FN → VTA	Gil-Miravet, 2019 ⁵⁶
	Rats	PHA-L anterograde tracing	FN → contralateral VTA	Parker, 2014 ⁵³
	Humans	DWI and probabilistic tractography	FN → mostly ipsilateral VTA (with predominance from the right hemisphere)	Hoffman, 2024 ⁴⁷
	Mice	Herpes virus anterograde tracing	FN → VTA	Carta, 2019 ¹¹
VTA → FN	Rats	Fluoro-Gold retrograde tracing and Cholera toxin anterograde tracing	None VTA → FN	Ikai, 1992 ⁴⁵

Notes: The table lists only those studies that specified the individual cerebellar nuclei [eg, fastigial nucleus (FN), interposed nucleus (IN), and dentate nucleus (DN)]. Studies not distinguishing individual cerebellar nuclei, such as one employing rabies virus retrograde tracing to map projections to the VTA,⁵⁹ have been omitted.

VTA Projections to Cerebellum

Several studies have documented direct dopaminergic projections from the VTA to the cerebellum (as shown in Figure 1), with a particularly large projection terminating in bilateral Crus I with contralateral predominance in rats.^{45,49} Alternatively, a combined anterograde and retrograde tracing study by Li et al challenged this notion, suggesting instead that in mice, dopaminergic afferents to the cerebellum may originate from PCs in the cerebellar cortex constituting an intrinsic dopaminergic system.⁵¹ However, numerous subsequent studies have confirmed reciprocal cerebellar connections with the VTA, particularly in the Crus I/II region (Table 1), and further reported associations with ASD pathogenesis.⁶²

VTA Alterations in ASD

The VTA consists primarily of dopaminergic neurons interspersed with smaller numbers of GABAergic and glutamatergic neurons.^{63,64} These dopaminergic projection neurons are crucial for the reward-dependent reinforcement of

behaviors, including social activities.⁶⁵ Notably, intranasal administration of oxytocin, a neurotransmitter strongly implicated in social bonding, improved social communication in patients with ASD,⁶⁶ possibly through actions within the VTA.⁶⁷

Alterations in the VTA dopaminergic system have been observed in various animal models of ASD, including a reduction in dopaminergic output.⁶⁸ These alterations likely contribute to ASD-relevant social deficits in animals as they can be mitigated by specific activation of VTA dopaminergic neurons.^{10,68–70} The neural mechanisms underlying these alterations warrant further investigation.

Cerebello–VTA Circuit Dysfunction and Autistic Traits

The cerebellum and VTA are crucially involved in reinforcement, social actions, and motor behaviors. However, the influence of cerebello–VTA circuit activities on autistic behaviors remains largely unexplored. Nonetheless, there is emerging evidence to suggest that modulating this circuit can influence autistic phenotypes. For instance, chemogenetic inhibition of PC activity in the right Crus I of wild-type mice induced ASD-like social deficits as well as repetitive and restricted behaviors, whereas activation of these cells mitigated social impairments in ASD model mice.⁷¹

Stereotyped Behavior

The cerebellum serves as a crucial neural substrate for predictive processing by encoding adaptive internal models that facilitate automatic, rapid, and finely-tuned behaviors.⁷² Mice with diminished numbers of cerebellar PCs displayed more frequent repetitive behaviors⁷³ and these behaviors were negatively correlated with PC numbers.^{73,74}

Circuits reciprocally connecting the cerebellum and VTA likely transmit limbic signals to cortico-ponto-cerebellar loops essential for the execution and coordination of voluntary movements.⁴⁵ Consequently, the cerebellar abnormalities and reorganization of VTA pathways detected in ASD patients ([Supplementary Table](#)) may lead to diminished dopaminergic modulation of motor outputs and ensuing behavioral stereotypy.⁷⁵ Additionally, stronger connectivity between the VTA and bilateral thalamus has been reported in ASD patients, and was associated with repetitive and restrictive behaviors.⁷⁶ Thus, VTA outputs triggered by cerebellar projections may also activate thalamo-basal ganglia-cortical circuits, resulting in stereotyped behaviors.

Social Interaction

Supekar et al proposed that deficits in mesolimbic reward pathways contribute to impaired social skills among children with autism,⁶⁵ and that the cerebello–VTA pathway may contribute to socio-affective disorders by disrupting normal reward-seeking behavior, resulting in reduced social motivation. In accord with this notion, optogenetic modulation of the cerebellum–VTA pathway was reported to bidirectionally influence social behavior and reward in ASD model animals.⁶² Moreover, the integrity of the DN–VTA pathway in mice was found to be necessary for normal social preference behaviors.¹¹

Reinforcement

The cerebello–VTA pathway also appears to strongly influence reinforcement. Carta et al reported that transient optogenetic silencing of the DN–VTA in mice reduced the influence of rewarding stimuli on behavior.¹¹ Similarly, the modulation of the DCN–VTA pathway in mice altered food intake irrespective of baseline satiety levels.⁷⁷ These findings suggest that specific regions of the cerebellum regulate reward signals (a core feature of VTA dopaminergic functions), thereby either promoting or inhibiting reinforced (reward-dependent) behaviors. Moreover, individuals with ASD were reported to exhibit abnormal structural and functional connections between the VTA and the nucleus accumbens, the primary integration site for reward-related signals and motor commands, potentially leading to reduced motivation for social interaction.^{65,78,79}

Hyphedonia

Lesioning of the rat DN resulted in decreased hedonic motivation, a hallmark of emotional disorders.⁸⁰ A recent study also reported that PCs in Crus I influenced VTA activity in mice through connections with the DN.⁵⁴ Additionally, the

deactivation of DN neurons projecting to the VTA attenuated depressive symptoms in animals,⁵⁴ while conversely, dysfunction of the cerebello–VTA circuit was associated with hyphedonia-like symptoms.

Conclusions

Developmental abnormalities in the cerebellum and VTA may contribute to ASD pathogenesis and autistic phenotypes. Indeed, the cerebellum and VTA are strongly and reciprocally connected, and this review summarizes emerging evidence that cerebello–VTA circuit dysfunction is an important contributor to ASD pathology. However, several outstanding issues warrant further exploration.

(1) Elucidating the precise neural pathways between the cerebellum and VTA: Precise mapping of VTA projections to cerebellar cortex and deep nuclei and of feedback fibers from the cerebellum to the VTA is critical for delineating the contributions of regional cerebello–VTA circuit abnormalities to ASD pathogenesis and symptoms.

(2) Exploring the potential of cerebello-VTA circuit modulation in clinical ASD research: Findings of cerebello-VTA circuit abnormalities in ASD present new research opportunities, although clinical applications remain highly speculative at this stage. While bilateral cerebellar repetitive transcranial magnetic stimulation has shown benefits for Parkinson's disease patients,⁸¹ its efficacy for ASD requires much additional investigation. Future research could employ non-invasive neuroimaging to better characterize cerebello-VTA connectivity in the different stages of ASD and among patients with variations in symptom profile. Moreover, integrating knowledge of cerebello-VTA circuits into existing behavioral therapies may facilitate more targeted interventions.

(3) Understanding the pathophysiological mechanisms linking cerebello–VTA circuit abnormalities to ASD: Preclinical and clinical studies are crucial for a deeper understanding of how cerebello–VTA circuit activity changes during development and how these changes relate to the emergence of autistic symptoms. Animal models of ASD and genetic tools offer promising avenues for elucidating the contributions of these circuits to ASD pathogenesis.

In conclusion, this review suggests that impaired cerebello–VTA circuitry may contribute to autistic symptoms and further suggests that cerebello–VTA circuits are promising targets for the clinical treatment of ASD. Future systematic reviews are warranted to offer a more structured analysis of this important field.

Abbreviations

AAV, adeno-associated virus; ASD, autism spectrum disorder; CC, cerebellar cortex; DCN, deep cerebellar nuclei; DN, dentate nucleus; DWI, Diffusion weighted imaging; FN, fastigial nucleus; HRP, Horseradish peroxidase; IN, interpositus nucleus; PC, Purkinje cell; PHA-L, Phaseolus vulgaris leucoagglutinin; TD, typically developing; VTA, ventral tegmental area; WGA, wheat germ agglutinin.

Funding

This work was supported by grants from Guangdong Basic and Applied Basic Research Foundation (2024A1515012913), Key Research Foundation of Guangdong Provincial Education Bureau (2023ZDZX2036), National Natural Science Foundation of China (82372583), Shanghai Rising-Star Program (21QA1408000), Innovation Project for Marine Youth Talent of Zhanjiang City (2021E05024), and the Special Fund of Science and Technology Innovation Cultivation of Guangdong University Students (pdjh2024a238).

Disclosure

The authors report no conflicts of interest in this work.

References

1. Zeidan J, Fombonne E, Scora J, et al. Global prevalence of autism: a systematic review update. *Autism Res.* 2022;15(5):778790. doi:10.1002/aur.2696
2. Maenner MJ, Warren Z, Williams AR, et al. Prevalence and characteristics of autism spectrum disorder among children aged 8 years-autism and developmental disabilities monitoring network, 11 Sites, United States, 2020. *MMWR Surveill Summ.* 2023;72(2):1–14. doi:10.15585/mmwr.ss7202a1

3. Salari N, Rasoulpoor S, Rasoulpoor S, et al. The global prevalence of autism spectrum disorder: a comprehensive systematic review and meta-analysis. *Ital J Pediatr*. 2022;48(1):112. doi:10.1186/s13052-022-01310-w
4. Gilbert E, Morasse K, Rouleau N. Source memory and social functioning in children with high functioning ASD-a pilot study. *Int Meet Autism Res*. 2008;2018:1.
5. Zhou MS, Nasir M, Farhat LC, Kook M, Artukoglu BB, Bloch MH. Meta-analysis: pharmacologic treatment of restricted and repetitive behaviors in autism spectrum disorders. *J Am Acad Child Adolesc Psychiatry*. 2021;60(1):35–45. doi:10.1016/j.jaac.2020.03.007
6. Lord C, Elsabbagh M, Baird G, Veenstra-Vanderweele J. Autism spectrum disorder. *Lancet*. 2018;392(10146):508–520. doi:10.1016/s0140-6736(18)31129-2
7. Lavelle TA, Weinstein MC, Newhouse JP, Munir K, Kuhlthau KA, Prosser LA. Economic burden of childhood autism spectrum disorders. *Pediatrics*. 2014;133(3):e520–e529. doi:10.1542/peds.2013-0763
8. Zhao Y, Luo Y, Zhang R, Zheng X. Direct and indirect costs for families of children with autism spectrum disorder in China. *Autism*. 2023;27(8):2337–2347. doi:10.1177/13623613231158862
9. Hampson DR, Blatt GJ. Autism spectrum disorders and neuropathology of the cerebellum. *Front Neurosci*. 2015;9:420. doi:10.3389/fnins.2015.00420
10. Krishnan V, Stoppel DC, Nong Y, et al. Autism gene Ube3a and seizures impair sociability by repressing VTA Cbln1. *Nature*. 2017;543(7646):507–512. doi:10.1038/nature21678
11. Carta I, Chen CH, Schott AL, Dorizan S, Khodakhah K. Cerebellar modulation of the reward circuitry and social behavior. *Science*. 2019;363(6424):6424. doi:10.1126/science.aav0581
12. Zhao G, Walsh K, Long J, Gui W, Denisova K, Pavlova MA. Reduced structural complexity of the right cerebellar cortex in male children with autism spectrum disorder. *PLoS One*. 2018;13(7):e0196964. doi:10.1371/journal.pone.0196964
13. Pagnozzi AM, Eugenia C, Sara C, Jurgen F, Rose SE. A systematic review of structural MRI biomarkers in autism spectrum disorder: a machine learning perspective. *Int J Dev Neurosci*. 2018;71:68–82. doi:10.1016/j.ijdevneu.2018.08.010
14. Carper RA, Courchesne E. Inverse correlation between frontal lobe and cerebellum sizes in children with autism. *Brain*. 2000;123(4):836–844. doi:10.1093/brain/123.4.836
15. Piven J, Saliba K, Bailey J, Arndt S. An MRI study of autism: the cerebellum revisited. *Neurology*. 1997;49(2):546–551. doi:10.1212/wnl.49.2.546
16. Rumsey JM, Creasey H, Stepanek JS, et al. Hemispheric asymmetries, fourth ventricular size, and cerebellar morphology in autism. *J Autism Dev Disord*. 1988;18(1):127–137. doi:10.1007/BF02211823
17. Laidi C, Floris DL, Tillmann J, et al. Cerebellar atypicalities in autism? *Biol Psychiatry*. 2022;92(8):674–682. doi:10.1016/j.biopsych.2022.05.020
18. Kumar M, Hiremath C, Khokhar SK, et al. Altered cerebellar lobular volumes correlate with clinical deficits in siblings and children with ASD: evidence from toddlers. *J Transl Med*. 2023;21(1):246. doi:10.1186/s12967-023-04090-x
19. Bailey A, Luthert P, Dean A, et al. A clinicopathological study of autism. *Brain*. 1998;121(5):889–905. doi:10.1093/brain/121.5.889
20. Toback M, Zangeneh K, Siddiqui TJ, Marzban H. Neurodevelopmental disorders of the cerebellum: autism spectrum disorder. In: Marzban H, editor. *Development of the Cerebellum from Molecular Aspects to Diseases*. Contemporary Clinical neuroscience. Cham: Springer; 2017:1. doi:10.1007/978-3-319-59749-2_18
21. Liu J, Yao L, Zhang W, et al. Gray matter abnormalities in pediatric autism spectrum disorder: a meta-analysis with signed differential mapping. *Eur Child Adolesc Psychiatry*. 2017;26(8):933–945. doi:10.1007/s00787-017-0964-4
22. Scott JA, Schumann CM, Goodlin-Jones BL, Amaral DG. A comprehensive volumetric analysis of the cerebellum in children and adolescents with autism spectrum disorder. *Autism Res*. 2009;2(5):246–257. doi:10.1002/aur.97
23. D'Mello AM, Crocetti D, Mostofsky SH, Stoodley CJ. Cerebellar gray matter and lobular volumes correlate with core autism symptoms. *Neuroimage Clin*. 2015;7:631–639. doi:10.1016/j.nicl.2015.02.007
24. McKinney WS, Kelly SE, Unruh KE, et al. Cerebellar volumes and sensorimotor behavior in autism spectrum disorder. *Front Integr Neurosci*. 2022;16:821109. doi:10.3389/fnint.2022.821109
25. D'Mello AM, Moore DM, Crocetti D, Mostofsky SH, Stoodley CJ. Cerebellar gray matter differentiates children with early language delay in autism. *Autism Res*. 2016;9(11):1191–1204. doi:10.1002/aur.1622
26. Olivito G, Lupo M, Laghi F, et al. Lobular patterns of cerebellar resting-state connectivity in adults with autism spectrum disorder. *Eur J Neurosci*. 2018;47(6):729–735. doi:10.1111/ejn.13752
27. Lee M, Martin-Ruiz C, Graham A, et al. Nicotinic receptor abnormalities in the cerebellar cortex in autism. *Brain*. 2002;125(7):1483–1495. doi:10.1093/brain/awf160
28. Ritvo ER, Freeman BJ, Scheibel AB, et al. Lower Purkinje cell counts in the cerebella of four autistic subjects: initial findings of the UCLA-NSAC research report. *Am J Psychiatry*. 1986;143(7):862–866. doi:10.1176/ajp.143.7.862
29. Bauman ML, Kemper TL, Bauman M, Kemper TL. Histoanatomic observations of the brain in early infantile autism. *Neurology*. 1985;35(6):866–874. doi:10.1212/wnl.35.6.866
30. Vargas DL, Nascimbene C, Krishnan C, Zimmerman AW, Pardo CA. Neuroglial activation and neuroinflammation in the brain of patients with autism. *Ann Neurol*. 2005;57(1):67–81. doi:10.1002/ana.20315
31. Fatemi SH, Halt AR, Realmuto G, et al. Purkinje cell size is reduced in cerebellum of patients with autism. *Cell Mol Neurobiol*. 2002;22(2):171–175. doi:10.1023/a:1019861721160
32. Whitney ER, Kemper TL, Bauman ML, Rosene DL, Blatt GJ. Cerebellar Purkinje cells are reduced in a subpopulation of autistic brains: a stereological experiment using calbindin-D28k. *Cerebellum*. 2008;7(3):406–416. doi:10.1007/s12311-008-0043-y
33. Jerry S, Christopher C, Katelyn E, et al. Regional alterations in purkinje cell density in patients with autism. *PLoS One*. 2014;9(2):e81255. doi:10.1371/journal.pone.0081255
34. Roux S, Bailly Y, Bossu JL. Regional and sex-dependent alterations in Purkinje cell density in the valproate mouse model of autism. *Neuroreport*. 2019;30(2):82–88. doi:10.1097/wnr.0000000000001164
35. Heh CW, Smith R, Wu J, et al. Positron emission tomography of the cerebellum in autism. *Am J Psychiatry*. 1989;146(2):242–245. doi:10.1176/ajp.146.2.242
36. Yip J, Soghomonian JJ, Blatt GJ. Increased GAD67 mRNA expression in cerebellar interneurons in autism: implications for Purkinje cell dysfunction. *J Neurosci Res*. 2008;86(3):525–530. doi:10.1002/jnr.21520

37. Jeong-Won J, Tiwari VN, Behen ME, Chugani HT, Chugani DC. In vivo detection of reduced Purkinje cell fibers with diffusion MRI tractography in children with autistic spectrum disorders. *Front Hum Neurosci*. 2014;8(1):110. doi:10.3389/fnhum.2014.00110
38. Rossman IT, Lulu L, Morgan KM, et al. Engrailed2 modulates cerebellar granule neuron precursor proliferation, differentiation and insulin-like growth factor 1 signaling during postnatal development. *Mol Autism*. 2014;5(1):9. doi:10.1186/2040-2392-5-9
39. Wills S, Cabanlit M, Bennett J, Ashwood P, Amaral DG, Water JVD. Detection of autoantibodies to neural cells of the cerebellum in the plasma of subjects with autism spectrum disorders. *Brain Behav Immun*. 2009;23(1):64–74. doi:10.1016/j.bbi.2008.07.007
40. Whitney ER, Kemper TL, Rosene DL, Bauman ML, Blatt GJ. Density of cerebellar basket and stellate cells in autism: evidence for a late developmental loss of Purkinje cells. *J Neurosci Res*. 2009;87(10):2245–2254. doi:10.1002/jnr.22056
41. Yip J, Soghomonian JJ, Blatt GJ. Decreased GAD65 mRNA levels in select subpopulations of neurons in the cerebellar dentate nuclei in autism: an in situ hybridization study. *Autism Res*. 2009;2(1):50–59. doi:10.1002/aur.62
42. Esslinger C, Braun U, Schirmbeck F, et al. Activation of midbrain and ventral striatal regions implicates salience processing during a modified beads task. *PLoS One*. 2013;8(3):e58536. doi:10.1371/journal.pone.0058536
43. Perciavalle V, Berretta S, Raffaele R. Projections from the intracerebellar nuclei to the ventral midbrain tegmentum in the rat. *Neuroscience*. 1989;29(1):109–119. doi:10.1016/0306-4522(89)90336-9
44. Snider RS, Maiti A. Cerebellar contributions to the Papez circuit. *J Neurosci Res*. 1976;2(2):133–146. doi:10.1002/jnr.490020204
45. Ikai Y, Takada M, Shinonaga Y, Mizuno N. Dopaminergic and non-dopaminergic neurons in the ventral tegmental area of the rat project, respectively, to the cerebellar cortex and deep cerebellar nuclei. *Neuroscience*. 1992;51(3):719–728. doi:10.1016/0306-4522(92)90310-x
46. Snider RS, Maiti A, Snider SR. Cerebellar pathways to ventral midbrain and nigra. *Exp Neurol*. 1976;53(3):714–728. doi:10.1016/0014-4886(76)90150-3
47. Hoffman LJ, Leong JK, Sullivan-Toole H, Foley J, Elliott BL, Olson IR. An in vivo dissection, and analysis of socio-affective symptoms related to cerebellum-midbrain reward circuitry in humans. *bioRxiv*. 2024. doi:10.1101/2023.09.29.560239
48. Hashimoto M, Yamanaka A, Kato S, Tanifuji M, Kobayashi K, Yaginuma H. Anatomical evidence for a direct projection from Purkinje cells in the mouse cerebellar vermis to medial parabrachial nucleus. *Front Neural Circuits*. 2018;12:6. doi:10.3389/fncir.2018.00006
49. Ikai Y, Takada M, Mizuno N. Single neurons in the ventral tegmental area that project to both the cerebral and cerebellar cortical areas by way of axon collaterals. *Neuroscience*. 1994;61(4):925–934. doi:10.1016/0306-4522(94)90413-8
50. Wagner MJ, Kim TH, Savall J, Schnitzer MJ, Luo L. Cerebellar granule cells encode the expectation of reward. *Nature*. 2017;544(7648):96–100. doi:10.1038/nature21726
51. Li C, Saliba NB, Martin H, et al. Purkinje cell dopaminergic inputs to astrocytes regulate cerebellar-dependent behavior. *Nat Commun*. 2023;14(1):1613. doi:10.1038/s41467-023-37319-w
52. Phillipson OT. Afferent projections to the ventral tegmental area of Tsai and interfascicular nucleus: a horseradish peroxidase study in the rat. *J Comp Neurol*. 1979;187(1):117–143. doi:10.1002/cne.901870108
53. Parker KL, Narayanan NS, Andreasen NC. The therapeutic potential of the cerebellum in schizophrenia. *Front Syst Neurosci*. 2014;8:163. doi:10.3389/fnsys.2014.00163
54. Baek SJ, Park JS, Kim J, Yamamoto Y, Tanaka-Yamamoto K. VTA-projecting cerebellar neurons mediate stress-dependent depression-like behaviors. *Elife*. 2022;11:e72981. doi:10.7554/eLife.72981
55. Watabe-Uchida M, Zhu L, Ogawa SK, Vamanrao A, Uchida N. Whole-brain mapping of direct inputs to midbrain dopamine neurons. *Neuron*. 2012;74(5):858–873. doi:10.1016/j.neuron.2012.03.017
56. Gil-Miravet I, Melchor-Eixea I, Arias-Sandoval E, et al. From back to front: a functional model for the cerebellar modulation in the establishment of conditioned preferences for cocaine-related cues. *Addict Biol*. 2019;26(1):e12834. doi:10.1111/adb.12834
57. Judd EN, Lewis SM, Person AL. Diverse inhibitory projections from the cerebellar interposed nucleus. *Elife*. 2021;10:e66231. doi:10.7554/eLife.66231
58. Chao OY, Pathak SS, Zhang H, et al. Social memory deficit caused by dysregulation of the cerebellar vermis. *Nat Commun*. 2023;14(1):6007. doi:10.1038/s41467-023-41744-2
59. Beier K, Steinberg E, Deloach K, et al. Circuit architecture of VTA dopamine neurons revealed by systematic input-output mapping. *Cell*. 2015;162(3):622–634. doi:10.1016/j.cell.2015.07.015
60. Fujita H, Kodama T, Lac SD. Modular output circuits of the fastigial nucleus for diverse motor and nonmotor functions of the cerebellar vermis. *Elife*. 2020;9(e58613). doi:10.7554/eLife.58613
61. Yoshida J, Oñate M, Khatami L, Vera J, Nadim F, Khodakhah K. Cerebellar contributions to the basal ganglia influence motor coordination, reward processing, and movement vigor. *J Neurosci*. 2022;42(45):8406–8415. doi:10.1523/jneurosci.1535-22.2022
62. Fernández M, Sierra-Arregui T, Peñagarikano O. The cerebellum and autism: more than motor control. *IntechOpen*. 2019;1–17. doi:10.5772/intechopen.85897
63. Morales M, Margolis EB. Ventral tegmental area: cellular heterogeneity, connectivity and behaviour. *Nat Rev Neurosci*. 2017;18(2):73–85. doi:10.1038/nrn.2016.165
64. Zhang C, Liu X, Zhou P, Zhang J, He W, Yuan TF. Cholinergic tone in ventral tegmental area: functional organization and behavioral implications. *Neurochem Int*. 2018;114:127–133. doi:10.1016/j.neuint.2018.02.003
65. Supekar K, Kochalka J, Schaer M, et al. Deficits in mesolimbic reward pathway underlie social interaction impairments in children with autism. *Brain*. 2018;141(9):2795–2805. doi:10.1093/brain/awy191
66. Greene RK, Spanos M, Alderman C, et al. The effects of intranasal oxytocin on reward circuitry responses in children with autism spectrum disorder. *J Neurodev Disord*. 2018;10(1):12. doi:10.1186/s11689-018-9228-y
67. Borland JM, Aiani LM, Norvelle A, et al. Sex-dependent regulation of social reward by oxytocin receptors in the ventral tegmental area. *Neuropsychopharmacology*. 2019;44(4):785–792. doi:10.1038/s41386-018-0262-y
68. Ádám Á, Kemecsei R, Company V, et al. Gestational exposure to sodium valproate disrupts fasciculation of the mesotelencephalic dopaminergic tract, with a selective reduction of dopaminergic output from the ventral tegmental area. *Front Neuroanat*. 2020;14:29. doi:10.3389/fnana.2020.00029
69. Bariselli S, Hörnberg H, Prévostolié C, et al. Role of VTA dopamine neurons and neuroligin 3 in sociability traits related to nonfamiliar conspecific interaction. *Nat Commun*. 2018;9(1):3173. doi:10.1038/s41467-018-05382-3

70. Bariselli S, Tzanoulinou S, Glanetas C, et al. SHANK3 controls maturation of social reward circuits in the VTA. *Nat Neurosci.* 2016;19(7):926–934. doi:10.1038/nm.4319
71. Stoodley CJ, D'Mello AM, Ellegood J, et al. Altered cerebellar connectivity in autism and cerebellar-mediated rescue of autism-related behaviors in mice. *Nat Neurosci.* 2017;20(12):1744–1751. doi:10.1038/s41593-017-0004-1
72. Jiang S, Ma Y, Hu X, Wu H. Cerebellar circuits in autism-linked social behavior. *Stress Brain.* 2023;3(1):1–5. doi:10.26599/SAB.2022.9060029
73. Martin LA, Dan G, Guy M. Repetitive behavior and increased activity in mice with Purkinje cell loss: a model for understanding the role of cerebellar pathology in autism. *Eur J Neurosci.* 2010;31(3):544–555. doi:10.1111/j.1460-9568.2009.07073.x
74. Dickson PE, Rogers TD, Del MN, et al. Behavioral flexibility in a mouse model of developmental cerebellar Purkinje cell loss. *Neurobiol Learn Mem.* 2010;94(2):220–228. doi:10.1016/j.nlm.2010.05.010
75. Rogers TD, Dickson PE, Mckimm E, et al. Reorganization of circuits underlying cerebellar modulation of prefrontal cortical dopamine in mouse models of autism spectrum disorder. *Cerebellum.* 2013;12(4):547–556. doi:10.1007/s12311-013-0462-2
76. Huang Y, Yu S, Wilson G, et al. Altered extended locus coeruleus and ventral tegmental area networks in boys with autism spectrum disorders: a resting-state functional connectivity study. *Neuropsychiatry Dis Treat.* 2021;17:1207–1216. doi:10.2147/ndt.s301106
77. Low AYT, Goldstein N, Gaunt JR, et al. Reverse-translational identification of a cerebellar satiation network. *Nature.* 2021;600(7888):269–273. doi:10.1038/s41586-021-04143-5
78. Nakamura Y, Ishida T, Tanaka SC, et al. Distinctive alterations in the mesocorticolimbic circuits in various psychiatric disorders. *Psychiatry Clin Neurosci.* 2023;77(6):345–354. doi:10.1111/pcn.13542
79. Pavál D, Micluția IV. The dopamine hypothesis of autism spectrum disorder revisited: current Status and future prospects. *Dev Neurosci.* 2021;43(2):73–83. doi:10.1159/000515751
80. Bauer DJ, Kerr AL, Swain RA. Cerebellar dentate nuclei lesions reduce motivation in appetitive operant conditioning and open field exploration. *Neurobiol Learn Mem.* 2011;95(2):166–175. doi:10.1016/j.nlm.2010.12.009
81. Koch G. rTMS effects on levodopa induced dyskinesias in Parkinson's disease patients: searching for effective cortical targets. *Restor Neurol Neurosci.* 2010;28(4):561–568. doi:10.3233/rnn-2010-0556

Neuropsychiatric Disease and Treatment

Dovepress

Publish your work in this journal

Neuropsychiatric Disease and Treatment is an international, peer-reviewed journal of clinical therapeutics and pharmacology focusing on concise rapid reporting of clinical or pre-clinical studies on a range of neuropsychiatric and neurological disorders. This journal is indexed on PubMed Central, the 'PsycINFO' database and CAS, and is the official journal of The International Neuropsychiatric Association (INA). The manuscript management system is completely online and includes a very quick and fair peer-review system, which is all easy to use. Visit <http://www.dovepress.com/testimonials.php> to read real quotes from published authors.

Submit your manuscript here: <https://www.dovepress.com/neuropsychiatric-disease-and-treatment-journal>