

Impact of transcranial Direct Current Stimulation on stereoscopic vision and retinal structure in adult amblyopic rodents

Gema Martinez-Navarrete^{1,2}, Sergio Castaño-Castaño³⁻⁶, Miguel Morales-Navas⁴, Francisco Nieto-Escámez^{4,7}, Fernando Sánchez-Santed⁴, Eduardo Fernandez^{1,2}

¹Neuroprosthesis and Neuroengineering Research Group, Institute of Bioengineering (IB), University Miguel Hernández (UMH), Elche, 03020, Spain; ²Networking Research Centre of Bioengineering, Biomaterials and Nanomedicine (CIBER-BBN), Zaragoza, Spain; ³Department Psychology, University of Oviedo, Plaza Feijoo S/N, Oviedo, 33003, Spain; ⁴Department of Psychology, University of Almería, Ctra. Sacramento S/N, La Cañada de San Urbano, Almería, 04120, Spain; ⁵Institute of Neurosciences of the Principality of Asturias (INEUROPA), Oviedo, Spain; ⁶Institute of Health Research of the Principality of Asturias (ISPA), Oviedo, Spain; ⁷Neuropsychological Evaluation and Rehabilitation Center (CERNEP), Ctra. Sacramento S/N, La Cañada de San Urbano, Almería, 04120, Spain

Correspondence: Gema Martinez-Navarrete, Department of Histology and Anatomy (Faculty of Medicine). Neuroengineering Biomedical Research Group, Institute of Bioengineering, University Miguel Hernandez, Elche, 03202, Spain, Email gema.martinezn@umh.es; Sergio Castaño-Castaño, Department Psychology, University of Oviedo, Plaza Feijoo s/n, Asturias, 33003, Spain, Email castanosergio@uniovi.es

Purpose: The impact of visual deprivation on retinal structure is widely debated. Experimental models, like monocular deprivation through lid suture, provide insights into the consequences of lacking visual experience during development. This deprivation delays primary visual cortex (CV1) maturation due to improper neural connection consolidation, which remains plastic beyond the critical period. However, few studies have used Optical Coherence Tomography (OCT) to investigate structural alterations in the retina of animal models following monocular deprivation. Instead, some studies have focused on the ganglion cell layer using post-mortem histological techniques in amblyopia models induced by monocular deprivation.

Methods: In this study, we used Cliff test to assess stereoscopic vision and spectral domain optical coherence tomography (SD-OCT) to evaluate retinal changes in an in vivo model of visual deprivation treated with Transcranial Direct Current Stimulation (tDCS).

Results: The depth perception test initially revealed differences between individuals with amblyopia and the control group. However, after 8 tDCS sessions, amblyopic subjects matched the control group's performance, which remained stable. Additionally, significant changes were observed in retinal structures post-tDCS treatment. Specifically, the thickness of the Nerve Fiber Layer + Ganglion Cell Layer + Inner Plexiform Layer (NFL+GCL+IPL) increased significantly in amblyopic eyes ($p < 0.001$). Moreover, significant retinal thickening, including the Nerve Fiber Layer + Ganglion Cell Layer + Inner Plexiform Layer (NFL+GCL+IPL) and the entire retina, was observed post-tDCS treatment ($p < 0.05$), highlighting the critical role of tDCS in ameliorating amblyopia. Additionally, treated animals exhibited reduced thickness in the Inner Nuclear Layer (INL) and Outer Nuclear Layer (ONL).

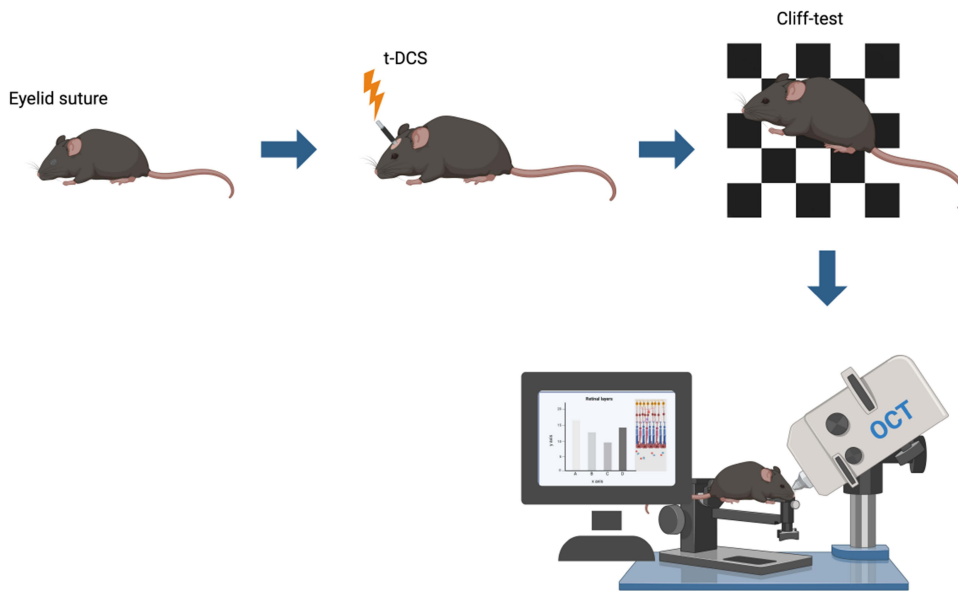
Conclusion: tDCS treatment effectively restores amblyopic individuals' stereoscopic vision, aligning their performance with controls, while impacting retinal structure, highlighting its potential in ameliorating amblyopia's visual deficits.

Keywords: amblyopia, monocular visual deprivation model, tDCS, stereoscopic vision, OCT

Introduction

Amblyopia, often referred to as "lazy eye", is a developmental visual disorder that arises from monocular or binocular visual deprivation during critical periods of visual development. This condition results from a reduction in visual acuity and can potentially lead to profound and permanent visual function loss if not addressed promptly. The severity of amblyopia-related visual deficits and the potential for recovery depend on the timing of visual deprivation. Deprivation during the peak critical period may lead to spontaneous recovery upon resumption of visual stimulation, whereas congenital or early deprivation results in profound and permanent visual function loss.¹⁻⁴

Graphical Abstract



Experimental models of monocular deprivation, particularly those involving eyelid suturing, have been crucial for understanding how visual deprivation affects development. This includes a delay in the maturation of the contralateral primary visual cortex (CV1)^{5–22} and trigger abnormal interactions in CV1, leading to significant changes in ocular dominance.¹³ Postnatal maturation of the retina is essential for the proper development of the neural retina.²³ The initial response to deprivation includes a reduction in functional strength in the amblyopic eye,^{6,11,12,24,25} followed by a gradual strengthening of the non-amblyopic eye.^{6,26,27} These changes are also associated with structural modifications, such as an increase in proteases leading to the breakdown of the extracellular matrix^{28,29} and alterations in neuronal structure and connectivity.^{30–37}

Several molecules have been identified, including components of the extracellular matrix, trophic factors, transcription factors, and kinases, as vital players in the plasticity of CV1 during postnatal development.³⁸ Changes in visual connectivity may also occur in adulthood in response to alterations in sensory experience alterations,³⁹ potentially affecting not only the contralateral visual cortex but also other sensory pathways.^{40–43}

The retina's critical role in the visual system has been well-studied, with extensive investigations into its structure, function, and significance in signal conversion.^{44,45} The technique of optical coherence tomography (OCT) has had a significant impact on retinal evaluation.^{46–48} While OCT is widely used in clinical settings to assess various ocular conditions, its application in amblyopia research remains debated.^{49–51} The debate centers on whether OCT can reliably correlate retinal structural changes with functional improvements in amblyopia. Furthermore, its use in animal models following monocular deprivation is still limited,^{22,52,53} which highlights the need for further investigation into its effectiveness and application in this context.

Transcranial direct current stimulation (tDCS) has shown promise as a non-invasive treatment for amblyopia. Castaño et al⁵⁴ conducted research exploring the effects of transcranial direct current stimulation (tDCS) on adult rats with amblyopia, revealing notable improvements in depth perception and cortical activity reorganization in the visual cortex after tDCS treatment. The study observed that amblyopic rats, initially exhibiting limited depth discrimination during the Cliff test, demonstrated enhanced depth discrimination abilities and behaviors similar to control rats following tDCS intervention. Subsequent studies conducted by Castaño et al^{54–56} further supported these findings, showing that tDCS can positively influence cortical and visual functions in adult amblyopic individuals.

The present study seeks to employ OCT imaging to assess retinal layer thickness in amblyopic animals and examine the effects of tDCS treatment. This involves exploring possible links between amblyopia, tDCS treatment, and changes in retinal

structure. Additionally, the study aims to determine whether the model impacts both cortical and ocular neural structures and to investigate potential indirect effects of tDCS on ocular structures in both healthy and amblyopic subjects.

Our study is based on the practical consideration that tDCS, commonly targeted at the visual cortex in deprivation amblyopia cases, might exert effects that go beyond the immediate area of application. Building on the well-documented ability of tDCS to induce neural changes, we explore the idea that improvements in cortical function could extend to positively impact retinal function. This perspective is grounded in the understanding that our neural systems are interconnected, and changes in one part can have ripple effects across related areas.^{57,58} By investigating these potential broader effects, our research introduces practical insights that could shape new approaches to treating amblyopia.

Methods

Animals

For this experimental series, 10 male Long Evans rats were used (n=5 per group). The groups were as follows: (1) amblyopic group (n=5), which underwent monocular deprivation, and (2) control group (n=5), which was not subjected to any deprivation. The animal facility, laboratory, and animal housing were equipped with automated temperature control (maintained at 22°C) and operated on a light-dark cycle with a 12-hour light period. The rats had ad libitum access to food and water.

All procedures were carried out in accordance with the recommendations in the Guide for the Care and Use of Laboratory Animals of the Association for Research in Vision and Ophthalmology and the Spanish Royal Decree 53/2013; European Directive 2010/63/EU. All the protocols were previously reviewed and approved by the Bioethics Committee of the University of Almeria.

Experimental Procedure

Figure 1A provides a visual representation of the experimental sequence and the phases involved. Initially, monocular deprivation was induced by suturing the eyelid after 12 postnatal days (PN) (the unsutured eye is referred to as contralateral). After a period of 60 PN days, the eyelid was reopened, and the Cliff test was conducted after an additional 30 days. Subsequently, on day 95 PN, an examination using OCT was conducted, followed by the application of tDCS treatment for 20 minutes daily over 8 consecutive days (from day 100 to 107). Following this, another Cliff test was carried out on day 115 postnatal, and OCT analysis was repeated 5 days later.

Experimental Amblyopia

The induction of experimental amblyopia followed a protocol adapted from Castaño et al.⁵⁵ Rats underwent eyelid suturing at postnatal day 12, just before natural eye opening, to ensure retinal exposure to environmental light. Anesthesia was administered via an intraperitoneal injection of ketamine (80 mg/kg) and xylazine (10 mg/kg). Lid margins were sutured with 6-0 silk, and a post-operative health check was conducted daily until complete cicatrization. Control rats received anesthesia without eyelid suturing. Post-surgery, rats were returned to their mother's cage until

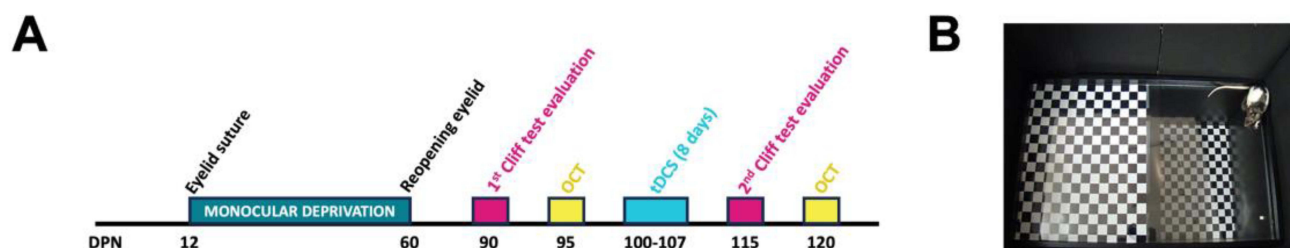


Figure 1 Experimental schedule and visual cliff test. **(A)** Monocular deprivation was performed by suturing the eyelid between PND 12–60. On day 90, a first Cliff test evaluation was performed, 5 days later the animals underwent an ocular analysis by OCT before being subjected to stimulation. Then tDCS treatment was performed on days 100–107. A final evaluation was made in the gully test on day 115 (8 days after the end of the tDCS session). Finally, after 120 postnatal days (13 days after the end of tDCS) they were again evaluated using OCT. **(B)** Amblyopic rat performing the visual cliff test.

weaning at postnatal day 21, followed by group housing. Finally, eyelid reopening occurred at two months, with a one-month recovery period before individual housing during the behavioral testing phase.

Epicranial Electrode Implantation and Stimulation for tDCS

The procedure for implanting and stimulating epicranial electrodes in this study followed the methodology outlined in previous work by Castaño et al.⁵⁵ Rats, anesthetized with Equithesin (0.3 mL/100 g i.p.) and positioned stereotaxically, had a gold-plated aluminum small electrode port surgically inserted into the cranial bone, connecting to a specialized vest designed for rat tDCS application (produced by NeuroDigital Technologies SL, Spain). Electrodes were consistently placed on the side opposite the amblyopic eye, directly over the visual cortex. Control and amblyopic groups not undergoing stimulation did not receive surgical treatment but were administered equithesine.

After a one-week recovery, rats underwent eight consecutive days of 20 minutes with a direct current of 200 μ A delivered by a 355 WPI stimulator (World Precision Instruments). To ensure a gradual commencement and cessation of the current, the stimulation intensity was manually modulated, gradually increasing from 0 to 200 μ A and decreasing back to 0 over a 20-second period at the beginning and end of each session. The anode connected to the skull electrode, and the cathode was on the rat's back, both moistened with conductive gel (Quirumed).

Cliff Test

A modification of the Cliff test, initially proposed by Booher and Walk in 1968,⁵⁹ was used with the aim of measuring the stereoscopic vision capability of animals. This modification involved using a specially constructed wooden box (84×53×41 cm), with a rectangular arena (84×53 cm) enclosed by a black plexiglass fence to prevent the animal from escaping. The floor of the arena was a glass surface divided into two areas. Underneath one area was a checkerboard pattern (3×3 cm squares) called the “UP zone”. In the second area, termed the “DOWN zone”, the checkerboard was positioned at the bottom of the wooden box (34 cm below the glass floor). The Cliff box was positioned on a black cm above the floor, in a room with walls covered by black curtains. The room was lit by a 20W halogen lamp on the floor to provide soft ambient lighting, ensuring the animals could discriminate between the two areas without glare. The test was conducted by placing the rat at the midpoint of the arena for 5 minutes in a controlled, noise-free environment. Due to difficulties with automated video tracking, performance was recorded using a ceiling-mounted camera with infrared sensor. Trials were reviewed manually by a blinded researcher, and the Index of Discrimination (ID) was calculated. This modification was conducted similarly to the method published in the work carried out by Castaño et al.⁵⁶

Depth Perception Assessment

The assessment of depth perception was carried out using the “Gully Test” at two experimental moments: pre-treatment moment (before being treated with tDCS) and post-treatment moment (after stimulation with tDCS) (Table 1).

The incorporation of a control group comprising rats with normal vision played a pivotal role in our study. This group, strategically chosen to gauge the animals' discrimination abilities and examine eye structures before treatment initiation, provided crucial insights into potential morphological changes in retinal layers following epicranial tDCS. The inclusion of this control group furnished us with a clear reference point, facilitating a meticulous assessment of tDCS-induced effects.

Conversely, the tDCS-stimulated amblyopic group was instrumental in confirming amblyopic conditions and assessing ocular differences before and after treatment. This comprehensive approach significantly enhanced our understanding of how tDCS affects both visual discrimination and ocular morphology.

Table 1 Different Phases of Treatment for the Evaluation of Stereopsis

Group	Pre-Treatment	Treatment	Post- Treatment
Amblyopic	1° Cliff Evaluation	tDCS 2mA/20min	2° Cliff Evaluation
Control	1° Cliff Evaluation	tDCS 2mA/20min	2° Cliff Evaluation

Opting for normal-vision rats as the control group, instead of a deprivation plus sham stimulation group, enabled a direct comparison of tDCS effects. This strategic design, avoiding additional variables associated with sham stimulation, focused our study on differences solely attributed to the amblyopic condition and its response to tDCS treatment. Notably, this approach enhanced the precision of our investigation, contributing to a clearer interpretation of results and ensuring a more accurate assessment of tDCS's potential impact on amblyopia.⁶⁰

To assess stereoscopic vision, we employed the adapted Cliff test (Figure 1B) following the protocol detailed in Castaño et al.⁵⁶ The test involved placing rats equidistant between two arena areas, allowing free exploration for 5 minutes during quiet, disruption-free periods. Due to the checkerboard pattern blending with the rats' coat color, automated video tracking was impractical. Instead, a Sony DSC-H9 camera, utilizing its night mode infrared sensor in low-light conditions, recorded the trials. Post-trial, the arena was cleaned to remove olfactory cues.

Recorded trials were manually reviewed by an unbiased researcher, unaware of group assignments and recording times (pre- or post-tDCS). Animals were coded numerically for objectivity. The Index of Discrimination (ID) was calculated as (Time Spent in Upper Area - Time Spent in Lower Area) / Total Time. Each subject underwent the test pre- and post-treatment, with a 23-day interval between conditions.

OCT Evaluation

The OCT images were obtained using the Heidelberg Spectralis OCT device, known for its high-resolution imaging capabilities, and the procedure for obtaining OCT images was following previously described methods with some modifications.⁶¹ High-resolution images of the retinal fundus were obtained, including circular scans focused on the optic nerve with a diameter of 3.3 mm and high-resolution mode set at 100 ART. A total of 20 thickness measurements were obtained for each retinal layer in the captured images, including the NFL+GCL+IPL (Nerve Fiber Layer + Ganglion Cell Layer + Inner Plexiform Layer), INL (Inner Nuclear Layer), and ONL (Outer Nuclear Layer), as well as measurements of the entire retina (thickness between the internal limiting membrane and Bruch's membrane) for each eye (Figure 2).

Due to the equipment's segmentation algorithm being optimized for human retinal layers, a manual measurement approach was employed. Two independent investigators, who were blinded to both experimental groups and time-points, performed the measurements on each OCT image acquired, in accordance with established protocols used in previous studies.^{62,63} Measurements were conducted using FIJI software (<https://imagej.net/software/fiji/>) with a dedicated plugin designed for this purpose, ensuring a detailed and accurate assessment of the retinal layers. This manual assessment ensured accurate segmentation and measurement of the retinal layers in our experimental analysis.

The examination of the retinal layers was conducted in both eyes of the animals. In the control group, the examination took place 5 days after completing the initial Cliff test. In the amblyope group, the examination was conducted on both the amblyopic eye and the normal eye at two distinct time points: (1) 15 days after the opening of the amblyopic eye and 1 day after the initial pre-treatment evaluation in the Cliff test, (2) 15 days after completing the tDCS sessions and 1 day after the post-treatment evaluation in the Cliff test.




Figure 2 Fundus and retinal layers of an OCT scan. On the left, a circular scan centered on the optic nerve on the retinal background (the green circle indicates the position of the peripapillary scan where the retinal sections were taken). On the right, a section of the retina with a diagram of the layers evaluated for the study: NFL+GCL+IPL (optic nerve fiber layer + ganglion cell layer + inner plexiform layer), INL (inner nuclear layer), ONL (outer nuclear layer) and entire retina. Scale: 200 microns.

Statistic

The SPSS 26.0 statistical package (IBM Corp., Armonk USA) was utilized for data analysis and graphic representations. The discrimination index (DI) was used as the dependent variable.⁵⁶

Sample size was determined using G*Power 3.1 Calculator with an alpha level of 0.05 and a power of 80%. Data normality was assessed using the Kolmogorov–Smirnov test, and Levene’s test was employed to examine variance homogeneity. Two-group comparisons utilized the Student’s *t*-test under conditions of normality and homogeneity, while the Mann–Whitney *U*-test was employed when these assumptions were not met. Multiple comparisons with normal distribution and variance homogeneity involved One-way or two-way ANOVA, followed by post hoc tests such as Bonferroni or Tukey. In cases where the data did not follow a normal distribution, the Mann–Whitney or Kruskal–Wallis *U*-test was used to determine differences. A significance level of $p < 0.05$ (* $p < 0.05$; *** $p < 0.001$) was considered statistically significant. Data are presented as means \pm SD.

Results

Depth Perception Test Results

The analysis revealed a significant main effect of treatment on the dependent variable ID; $F(1,8) = 15.003$, $p < 0.05$. Furthermore, a significant interaction effect between treatment and group was observed; $F(1,8) = 12.760$, ($p < 0.05$).

The results of the depth perception test showed significant differences between the amblyope group and the control group before tDCS stimulation (mean difference = 0.606, $p < 0.001$). After tDCS treatment, depth perception improved in the amblyopic group to the point where no significant differences were observed between the amblyopic and control groups (mean difference = 0.089, $p > 0.05$). Additionally, within the amblyopic group, a significant improvement in depth perception was noted from pre-treatment to post-treatment (mean difference = 0.539, $p = 0.001$). In contrast, the control group did not exhibit significant changes in depth perception between pre-treatment and post-treatment (mean difference = 0.022, $p > 0.05$) (Figure 3).

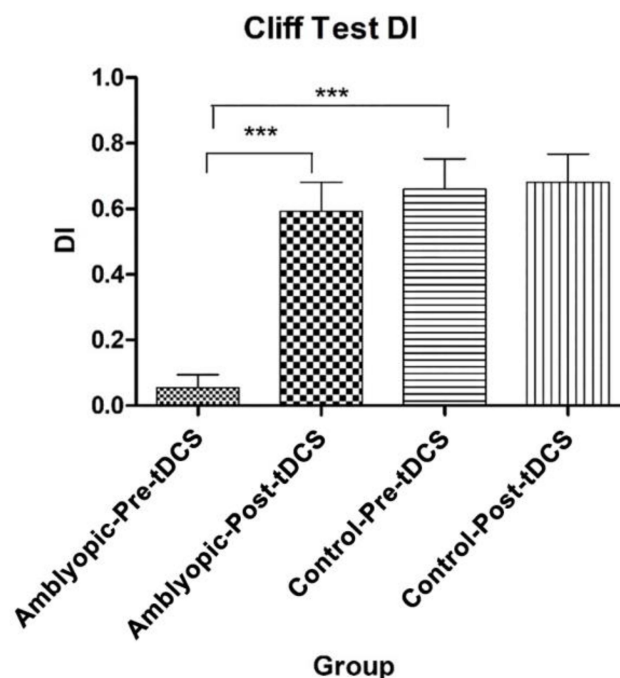


Figure 3 Effect of tDCS treatment on stereopsis (DI, Discrimination Index) in Amblyopic Rats. Significant improvement in DI observed in private rats post-treatment, contrasting with no improvement in the untreated amblyopic group. Data are represented as mean \pm SD. Significant differences between the different groups are plotted as *** $p < 0.001$.

Morphological Changes in the Retina After Visual Deprivation

To evaluate the morphological changes in the retina following visual deprivation, we measured the combined thickness of the NFL+GCL+IPL layers, which encompass the nerve fiber layer (NFL), ganglion cell layer (GCL), and inner plexiform layer (INL) (Figure 4B–C, red bars). Figure 4 provides a visual representation of the eye fundus with a circular scan conducted around the optic nerve, specifically capturing the peripapillary retina (Figure 4A). Additionally, two representative SD-OCT images of retinal sections are depicted, showcasing the amblyopic eyes before treatment with tDCS (Figure 4B) and after treatment with tDCS (Figure 4C). These images qualitatively and schematically demonstrate the noticeable increase in thickness observed in the NFL+GCL+IPL layer and the overall retina section of the amblyopic retina following tDCS treatment.

Effect of tDCS on Retinal Structure

Prior to comparing the treated and control amblyopic eyes, we examined whether there were any differences in the thicknesses of the studied retinal layers in the control eyes before and after tDCS application. Our analysis revealed no significant differences in the thicknesses of the analyzed layers between the control eyes pre-tDCS and post-tDCS (Figure 5). Subsequently, we calculated the mean value of all the data, including pre-treatment and post-treatment measurements, in order to compare them with the pre-tDCS and post-tDCS measurements of the amblyopic eyes, as well as the measurements of their contralateral eyes (Figure 5).

In relation to the NFL+GCL+IPL layer, the thickness showed a significant increase after treatment with tDCS in amblyopic eyes ($p < 0.001$). This indicates that tDCS had a positive effect on the thickness of this layer, suggesting a potential improvement in retinal structure. Conversely, the amblyopic eyes, which experienced monocular deprivation, exhibited a reduction in NFL+GCL+IPL thickness compared to the control group. This difference highlights the impact of monocular deprivation on retinal layer thickness and underscores the significance of the observed increase following tDCS treatment. These findings are depicted in Figure 6A, supporting the notion that tDCS may play a role in promoting structural changes in the NFL+GCL+IPL layer.

Regarding the INL and ONL layers, a noteworthy finding was the significant thinning observed in amblyopic eyes following tDCS treatment ($p < 0.05$). Intriguingly, prior to treatment, the control eyes exhibited lower thickness in both the INL and ONL layers compared to the amblyopic and contralateral eyes ($p < 0.01$ and $p < 0.001$, respectively). However, it is worth noting that after tDCS treatment, the thickness of these layers in the control eyes, amblyopic eyes with tDCS, and contralateral eyes with tDCS exhibited a remarkably similar pattern (Figure 6B and C). These findings suggest that tDCS treatment may have influenced the thinning of the INL and ONL layers in amblyopic eyes, potentially contributing to retinal remodeling.

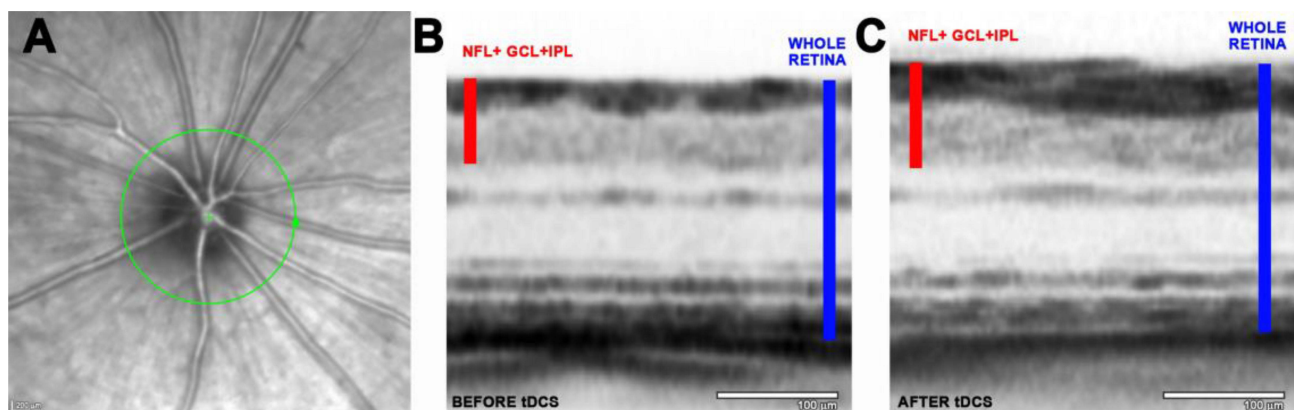


Figure 4 Representative fundus images of a private eye and their corresponding cross-sectional OCT images before and after tDCS treatment. (A) The green circle highlights the 360° transverse circumference in the peripapillary retina adjacent to the optic nerve, which was used for analyzing the thicknesses of different layers. Representative images of retinal morphology extracted from the corresponding OCTs scans of amblyopic rats prior to tDCS treatment (B), and after treatment (C). The red bars represent the thickness of the NFL+GCL+IPL layer set. The blue bars show the thickness of the entire retina. NFL+GCL+IPL, nerve fiber layer+ganglion cell layer +inner plexiform layer. Scale bar in (A): 200 μ m. Scale bar in (B) and (C): 100 μ m.

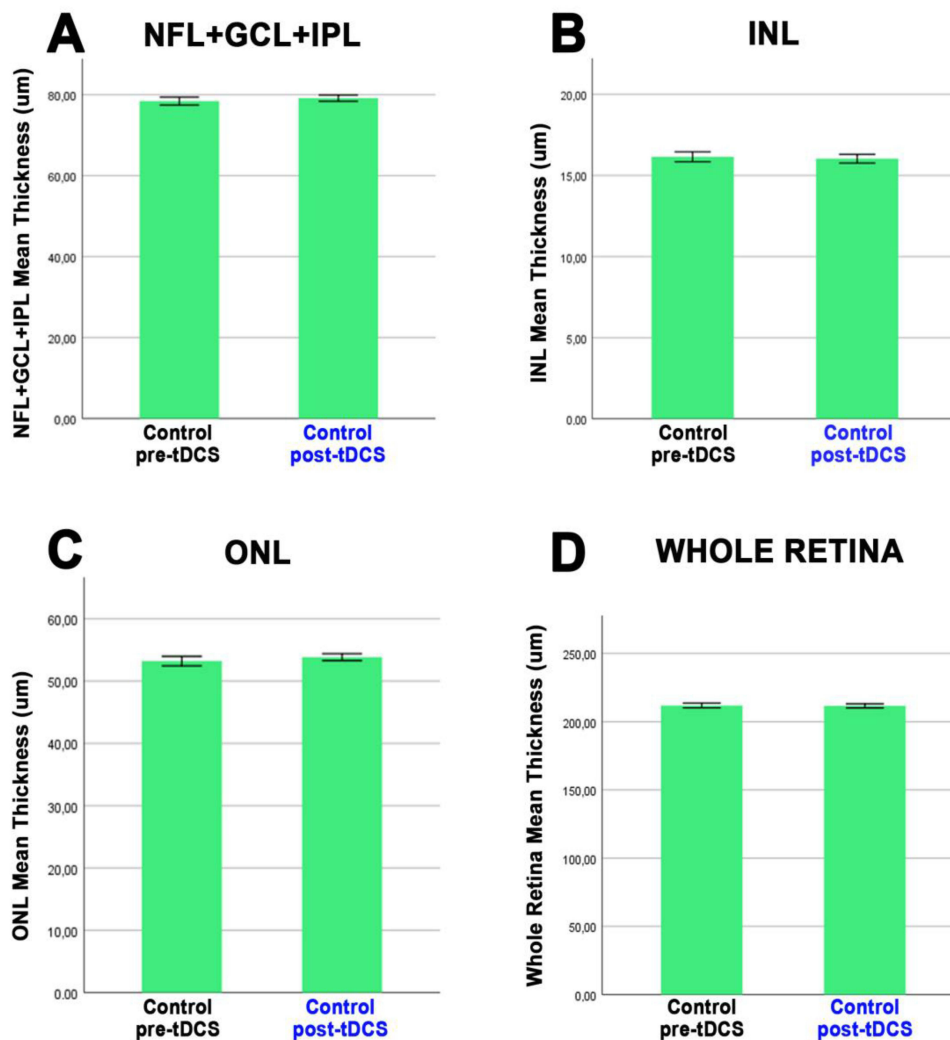


Figure 5 Comparison of retinal layer thickness in pre-tDCS control animals and post-tDCS determined by SD-OCT. The histograms depict the thickness measurements of various retinal layers, including the NFL+GCL+IPL layer (A), the INL layer (B), the ONL layer (C), and the entire retina (D), in the eyes of the subjects. No significant differences were observed between the pre-tDCS control animals and post-tDCS conditions. Data are represented as mean \pm SD. Twenty measurements were made for each layer and per eye (n=5).

Lastly, when considering the total thickness of the entire retina, a significant increase was observed in amblyopic eyes following tDCS treatment, with values changing from $207.5 \pm 6.7 \mu\text{m}$ before treatment to $213.7 \pm 6.9 \mu\text{m}$ after treatment ($p < 0.05$) (Figure 6D). In contrast, the total retinal thickness did not display significant differences between the control eyes and the contralateral eyes without and with treatment, demonstrating values of $211.5 \pm 6.1 \mu\text{m}$, $211.6 \pm 5.0 \mu\text{m}$, and $211.7 \pm 6.8 \mu\text{m}$, respectively. These findings indicate that the increase in total retinal thickness was specific to amblyopic eyes after tDCS intervention, while control and contralateral eyes maintained similar thickness levels (Figure 6D).

Concerning the contralateral eyes, a similar pattern was evident, resembling that observed in eyes with amblyopia both before and after treatment. Specifically, there was an increase in the thickness of the NFL+GCL+IPL layer and a decrease in the INL and ONL layers ($p < 0.05$). However, there were no statistically significant differences in the total retinal thickness before and after tDCS treatment in the contralateral eyes (Figure 6D). These findings suggest that the effects of tDCS on retinal layers are specific to the amblyopic eyes and do not extend to the contralateral eyes, as indicated by the absence of changes in the overall retinal thickness (Figure 6D).

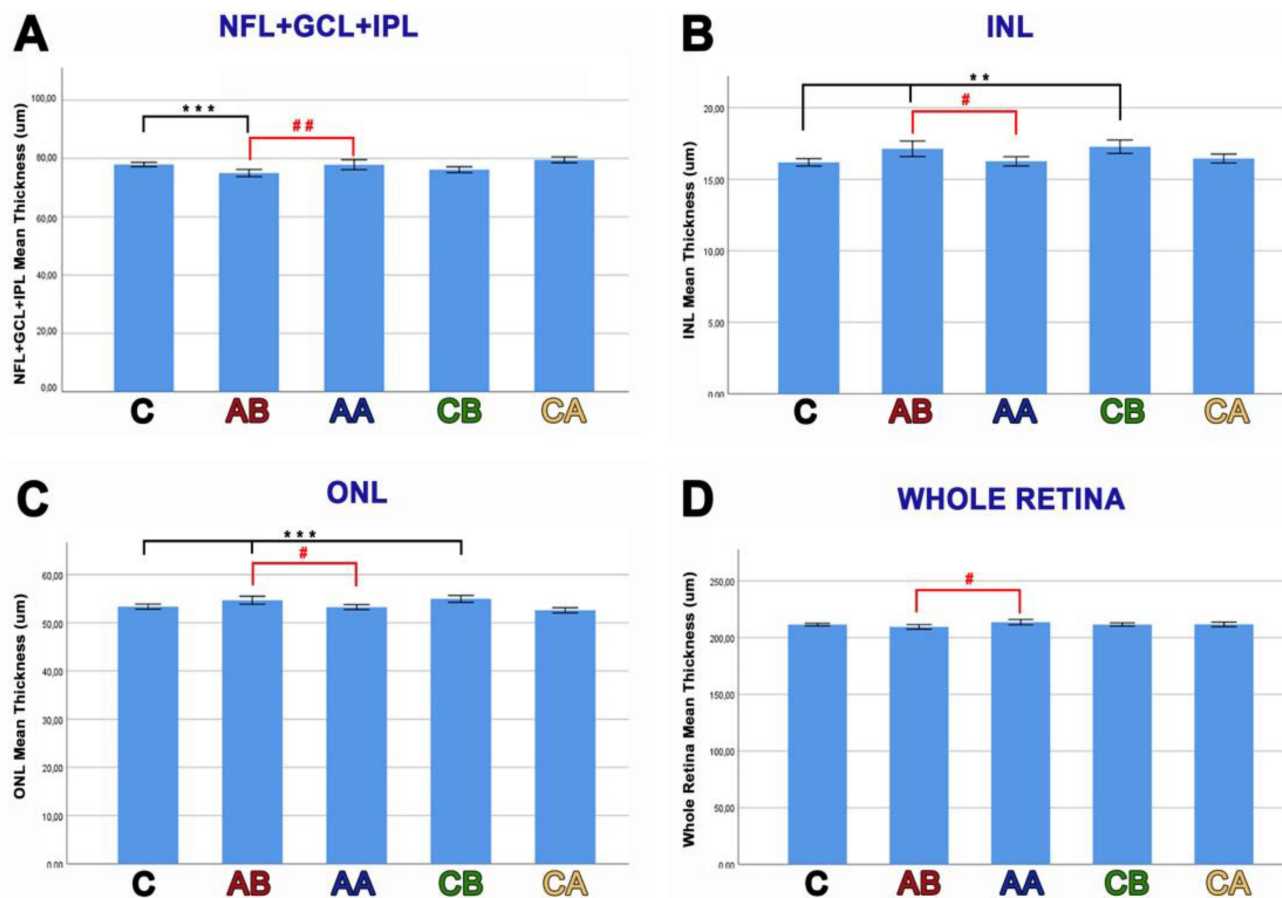


Figure 6 Changes in retinal thickness before and after tDCS treatment in control and amblyopic rats. Histograms present the thickness measurements of different retinal layers, including the NFL+GCL+IPL layer (**A**), the INL layer (**B**), the ONL layer (**C**), and the entire retina (**D**). The measurements were obtained from control eyes (C), amblyopic eyes before tDCS treatment (AB) and after treatment (AA), as well as their corresponding contralateral eyes before tDCS treatment (CB) and after treatment (CA). The data are represented as the mean \pm SD, with a total of twenty measurements per layer and per eye. Each group consisted of five animals ($n=5$). Significant differences between the different groups and control eyes are plotted as $**p < 0.01$, $***p < 0.001$. Specific comparisons between amblyopic eyes before and after treatment are shown as $\#p < 0.05$ and $\#\#p < 0.01$. NFL+GCL+IPL, nerve fiber layer+ganglion cell layer+inner plexiform layer; INL, inner nuclear layer; ONL, outer nuclear layer; C, control; AB, amblyopic eye before tDCS; AA, amblyopic eye after tDCS; CB, contralateral eye before tDCS; CA, contralateral eye after tDCS.

Discussion

The findings of our study align with previous research^{54–56} that has demonstrated the impact of visual acuity deprivation on depth perception in amblyopic rats. Consistent with these earlier studies, we observed a compromised depth perception in amblyopic rats, as reflected by their lower ID scores in the gully test. Notably, tDCS treatment substantially enhanced depth perception in amblyopic rats, suggesting its promise in mitigating amblyopia-related deficits. In contrast, control rats displayed consistent gully test performance, unaffected by tDCS. These findings underscore tDCS's therapeutic potential for amblyopia, particularly its influence on depth perception in amblyopic individuals.

We employed optical coherence tomography (OCT) imaging for non-invasive retinal assessment, offering advantages over conventional histological methods. The use of this imaging technique allowed us to monitor retinal morphology in the same animal across multiple time points, enabling dynamic *in vivo* analysis. This longitudinal OCT approach provided valuable insights into the evolving retinal anatomy efficiently and with minimal disruption, aligning with prior research highlighting OCT's benefits for non-invasive and longitudinal retinal studies.⁶⁴

The understanding of retinal changes in amblyopic eyes remains a subject of ongoing investigation and debate. Previous studies exploring retinal alterations in human amblyopic eyes using optical coherence tomography (OCT) have yielded inconclusive and conflicting findings. Some studies have reported no significant retinal changes over time in individuals with amblyopia^{65,66} Conversely, other investigations have observed an increase in the inner retinal layers

among amblyopic patients.⁶⁷ However, there is a dearth of literature regarding retinal changes in animal models of amblyopia. Studies conducted on these experimental models have indicated a reduction in the thickness of the optic nerve fiber layer, as well as a decrease in the number and size of ganglion cells and their nucleolar volume^{53,68,69} Furthermore, our study provides a mechanistic and structural basis for understanding how tDCS can induce functional and structural changes in the retina and visual cortex, aligning with clinical findings in humans.^{70,71} Therefore, further research is required to comprehensively elucidate the specific retinal changes associated with amblyopia, considering both human and animal studies, to enhance our understanding of the underlying mechanisms and potential therapeutic approaches.

Previous studies conducted on animal models have provided valuable insights into the effects of monocular visual deprivation on retinal morphology. In 1977, Von Noorden and colleagues investigated the impact of unilateral eyelid sutures on parafoveal ganglion cells in *Macaca mulatta*.⁵³ The study, spanning 24 months from birth, demonstrated a significant decrease in both the density and size of these cells. Similarly, studies conducted on cats subjected to monocular visual deprivation during the first 17 weeks after birth revealed a thinning of the inner plexiform layer and a decrease in the density of Müller's fibers within this layer.⁷² A recent study involving rabbits and monocular deprivation revealed a significant decrease in cell density across the inner nuclear layer (INL), outer nuclear layer (ONL), and notably in the ganglion cell layer (GCL). Moreover, the extent of these changes was found to be more pronounced with longer durations of deprivation.⁵² These findings collectively emphasize the profound impact of monocular visual deprivation on retinal cell density and organization, shedding light on the dynamic nature of retinal changes in response to visual experience or deprivation.

In this study, the effects of tDCS on retinal structure in amblyopic eyes were investigated. The results indicated that tDCS had no impact on the retinal structure of control eyes, demonstrating the safety of this intervention. However, in amblyopic eyes subjected to tDCS, significant anatomical changes were primarily observed in the inner retina. This was reflected in a notable increase in total retinal thickness in the treated amblyopic eyes. Our analysis of retinal thickness using OCT showed a highly significant reduction in the thickness of NFL, GCL, and IPL in amblyopic eyes compared to control eyes before tDCS. Notably, these three innermost layers of the retina account for approximately 30% of the total retinal thickness.⁷³ However, no significant changes in the thickness of the entire retina were observed between the contralateral eyes and control eyes. Interestingly, after 20 days of tDCS treatment, both the overall retinal thickness and the thickness of the innermost layers (NFL+GCL+IPL) increased. Conversely, INL and ONL, which had larger thicknesses in amblyopic eyes before treatment, decreased after tDCS. These findings suggest a potential compensatory mechanism, with tDCS inducing positive structural changes in the inner retina of amblyopic eyes, enhancing retinal integrity, and potentially improving visual function in individuals with amblyopia. This investigation aligns with previous research that has demonstrated tDCS, using currents as low as 2.5 μ A, can induce lasting changes in isolated retinal ganglion cell responses.⁷⁴ Our study found that tDCS induced changes in the inner retinal structure of amblyopic eyes, suggesting a potential compensatory mechanism. This could improve retinal integrity and visual function in amblyopia. Additional research is essential to uncover the mechanisms at play and the sustained effects of tDCS on retinal structure and visual outcomes in individuals with amblyopia.

In line with our results, Spiegel et al (2013) demonstrated the potential of non-invasive interventions in amblyopia treatment, highlighting how anodal transcranial direct current stimulation (a-tDCS) transiently enhances contrast sensitivity and normalizes visual cortex activation in individuals with amblyopia.⁷⁵ This underscores the leverage of adult brain plasticity for improving amblyopia therapies. Levi's et al holistic approach to amblyopia treatment, incorporating experimental strategies like perceptual learning and video games, aligns with the implications of our study on the efficacy of new therapeutic strategies.⁷⁶

Moreover, Bocci et al's findings on cathodal transcranial direct current stimulation (c-tDCS) enhancing visual acuity by reducing transcallosal inhibition suggest a valuable therapeutic tool, complementing the approaches discussed in our study.⁷⁷ Donkor et al's research on transcranial random noise stimulation (tRNS) in amblyopic adults provides promising evidence for the efficacy of non-invasive methods, indicating ongoing plasticity in the adult visual system.⁷⁸ Integrating these findings, Moret et al's study on high-frequency tRNS combined with perceptual training further supports the potential benefits of integrated therapies, offering a comprehensive perspective for advancing amblyopia treatment research and clinical applications.⁷⁹

A primary limitation of our study is the relatively small sample size of 5 rats per group, which may affect the robustness of our findings. Additionally, the use of a single animal model to study amblyopia and the effects of tDCS may limit the broader applicability of our results to human conditions. Future research should incorporate larger sample sizes and diverse animal models to validate and extend these findings.

In conclusion, our study provides strong evidence supporting tDCS as a non-invasive treatment to enhance both visual acuity and depth perception in amblyopia. Furthermore, we have demonstrated tDCS-induced changes in retinal structure, suggesting its potential impact on retinal health. These findings highlight tDCS as a promising non-invasive therapy for amblyopia, with the potential to enhance visual function and outcomes by targeting neural circuits and fostering neuroplasticity.

To translate these findings into clinical practice, future research should focus on conducting controlled clinical trials in amblyopic patients, developing longitudinal studies to assess long-term effects, and identifying biomarkers to predict treatment response. Additionally, integrating animal and human models in translational studies will help elucidate the mechanisms underlying tDCS-induced visual improvements and optimize the therapy for clinical applications.

Acknowledgments

This research was supported by the Spanish Ministerio de Ciencia, Innovación y Universidades/Agencia Estatal de Investigación (project PS09-01163), the Spanish Ministerio de Ciencia, Innovación y Universidades/Agencia Estatal de Investigación (project PSI2014-55785-C2-1-R), the Spanish Ministerio de Ciencia e Innovación (project PID2022-1416060B-I00), by the European Union's Horizon 2020 Research and Innovation Programme under Grant Agreement No. 899287 (NeuraViPeR), and by the Bidons Egara Research Chair of the University Miguel Hernandez.

Disclosure

The authors declare that they have no known competing financial interests or personal relationships that could have appeared to influence the work reported in this paper.

References

1. Wiesel TN, Hubel DH. Extent of recovery from the effects of visual deprivation in kittens. *J Neurophysiol.* 1965;28(6):1060–1072. doi:10.1152/jn.1965.28.6.1060
2. Eaton NC, Sheehan HM, Quinlan EM. Optimization of visual training for full recovery from severe amblyopia in adults. *Learn Memory.* 2016;23(2):99–103. doi:10.1101/lm.040295.115
3. Liao DS, Krahe TE, Prusky GT, Medina AE, Ramoa AS. Recovery of cortical binocularity and orientation selectivity after the critical period for ocular dominance plasticity. *J Neurophysiol.* 2004;92(4):2113–2121. doi:10.1152/jn.00266.2004
4. Schwarzkopf DS, Vorobyov V, Mitchell DE, Sengpiel F. Brief daily binocular vision prevents monocular deprivation effects in visual cortex. *Eur. J. Neurosci.* 2007;25(1):270–280. doi:10.1111/j.1460-9568.2006.05273.x
5. Sato M, Stryker MP. Distinctive features of adult ocular dominance plasticity. *J Neurosci.* 2008;28(41):10278–10286. doi:10.1523/JNEUROSCI.2451-08.2008
6. Frenkel MY, Bear MF. How monocular deprivation shifts ocular dominance in visual cortex of young mice. *Neuron.* 2004;44(6):917–923. doi:10.1016/j.neuron.2004.12.003
7. Prusky GT, Douglas RM. Developmental plasticity of mouse visual acuity. *Eur. J. Neurosci.* 2003;17(1):167–173. doi:10.1046/j.1460-9568.2003.02420.x
8. Taha S, Stryker MP. Rapid ocular dominance plasticity requires cortical but not geniculate protein synthesis. *Neuron.* 2002;34(3):425–436. doi:10.1016/S0896-6273(02)00673-6
9. Mataga N, Nagai N, Hensch TK. Permissive proteolytic activity for visual cortical plasticity. *Proceedings of the National Academy of Sciences.* 2002;99:7717–7721.
10. Trachtenberg JT, Stryker MP. Rapid anatomical plasticity of horizontal connections in the developing visual cortex. *J Neurosci.* 2001;21(10):3476–3482. doi:10.1523/JNEUROSCI.21-10-03476.2001
11. Hensch TK, Fagioli M, Mataga N, Stryker MP, Baekkeskov S, Kash SF. Local GABA circuit control of experience-dependent plasticity in developing visual cortex. *Science.* 1998;282(5393):1504–1508. doi:10.1126/science.282.5393.1504
12. Gordon JA, Stryker MP. Experience-dependent plasticity of binocular responses in the primary visual cortex of the mouse. *J Neurosci.* 1996;16(10):3274–3286. doi:10.1523/JNEUROSCI.16-10-03274.1996
13. Fagioli M, Pizzorusso T, Berardi N, Domenici L, Maffei L. Functional postnatal development of the rat primary visual cortex and the role of visual experience: dark rearing and monocular deprivation. *Vision Res.* 1994;34(6):709–720. doi:10.1016/0042-6989(94)90210-0
14. Antonini A, Stryker MP. Rapid remodeling of axonal arbors in the visual cortex. *Science.* 1993;260(5115):1819–1821. doi:10.1126/science.8511592
15. Shatz CJ, Stryker MP. Ocular dominance in layer IV of the cat's visual cortex and the effects of monocular deprivation. *J Physiol.* 1978;281(1):267–283. doi:10.1113/jphysiol.1978.sp012421

16. LeVay S, Stryker MP, Shatz CJ. Ocular dominance columns and their development in layer IV of the cat's visual cortex: a quantitative study. *J Comp Neurol.* 1978;179(1):223–244. doi:10.1002/cne.901790113
17. Blakemore C, Garey LJ, Vital-Durand F. The physiological effects of monocular deprivation and their reversal in the monkey's visual cortex. *J Physiol.* 1978;283(1):223–262. doi:10.1113/jphysiol.1978.sp012498
18. Movshon JA, Dursteler MR. Effects of brief periods of unilateral eye closure on the kitten's visual system. *J Neurophysiol.* 1977;40(6):1255–1265. doi:10.1152/jn.1977.40.6.1255
19. Hubel DH, Wiesel TN, LeVay S, Barlow HB, Gaze RM. Plasticity of ocular dominance columns in monkey striate cortex. *Philos Trans R Soc Lond B Biol Sci.* 1977;278:377–409.
20. Olson CR, Freeman RD. Progressive changes in kitten striate cortex during monocular vision. *J Neurophysiol.* 1975;38(1):26–32. doi:10.1152/jn.1975.38.1.26
21. Hubel DH, Wiesel TN. The period of susceptibility to the physiological effects of unilateral eye closure in kittens. *J Physiol.* 1970;206(2):419–436. doi:10.1113/jphysiol.1970.sp009022
22. Wiesel TN, Hubel DH. Single-cell responses in striate cortex of kittens deprived of vision in one eye. *J Neurophysiol.* 1963;26(6):1003–1017. doi:10.1152/jn.1963.26.6.1003
23. Sengpiel F, Kind PC. The role of activity in development of the visual system. *Curr Biol.* 2002;12:R818–26.
24. Trachtenberg JT, Trepel C, Stryker MP. Rapid extragranular plasticity in the absence of thalamocortical plasticity in the developing primary visual cortex. *Science.* 2000;287(5460):2029–2032. doi:10.1126/science.287.5460.2029
25. Saiepour MH, Rajendran R, Omrani A, et al. Ocular dominance plasticity disrupts binocular inhibition-excitation matching in visual cortex. *Curr Biol.* 2015;25(6):713–721. doi:10.1016/j.cub.2015.01.024
26. Kaneko M, Stellwagen D, Malenka RC, Stryker MP. Tumor necrosis factor- α mediates one component of competitive, experience-dependent plasticity in developing visual cortex. *Neuron.* 2008;58(5):673–680. doi:10.1016/j.neuron.2008.04.023
27. Sawtell NB, Frenkel MY, Philpot BD, Nakazawa K, Tonegawa S, Bear MF. NMDA receptor-dependent ocular dominance plasticity in adult visual cortex. *Neuron.* 2003;38(6):977–985. doi:10.1016/S0896-6273(03)00323-4
28. Oray S, Majewska A, Sur M. Dendritic spine dynamics are regulated by monocular deprivation and extracellular matrix degradation. *Neuron.* 2004;44(6):1021–1030. doi:10.1016/j.neuron.2004.12.001
29. Mataga N, Mizuguchi Y, Hensch TK. Experience-dependent pruning of dendritic spines in visual cortex by tissue plasminogen activator. *Neuron.* 2004;44(6):1031–1041. doi:10.1016/j.neuron.2004.11.028
30. Duffy KR, Mitchell DE. Darkness alters maturation of visual cortex and promotes fast recovery from monocular deprivation. *Curr Biol.* 2013;23(5):382–386. doi:10.1016/j.cub.2013.01.017
31. Duffy KR, Livingstone MS. Loss of neurofilament labeling in the primary visual cortex of monocularly deprived monkeys. *Cereb. Cortex.* 2005;15(8):1146–1154. doi:10.1093/cercor/bhh214
32. Duffy KR, Murphy KM, Frosch MP, Livingstone MS. Cytochrome oxidase and neurofilament reactivity in monocularly deprived human primary visual cortex. *Cereb. Cortex.* 2007;17(6):1283–1291. doi:10.1093/cercor/bhl038
33. Djurisic M, Vidal GS, Mann M, et al. PirB regulates a structural substrate for cortical plasticity. *Proceedings of the National Academy of Sciences* 2013;110:20771–20776.
34. Yu H, Majewska AK, Sur M. Rapid experience-dependent plasticity of synapse function and structure in ferret visual cortex in vivo. *Proceedings of the National Academy of Sciences* 2011;108:21235–21240.
35. Coleman JE, Nahmani M, Gavornik JP, et al. Rapid structural remodeling of thalamocortical synapses parallels experience-dependent functional plasticity in mouse primary visual cortex. *J Neurosci.* 2010;30(29):9670–9682. doi:10.1523/JNEUROSCI.1248-10.2010
36. Antonini A, Fagioli M, Stryker MP. Anatomical correlates of functional plasticity in mouse visual cortex. *J Neurosci.* 1999;19(11):4388–4406. doi:10.1523/JNEUROSCI.19-11-04388.1999
37. Montey KL, Quinlan EM. Recovery from chronic monocular deprivation following reactivation of thalamocortical plasticity by dark exposure. *Nat Commun.* 2011;2(1):317. doi:10.1038/ncomms1312
38. Ossipow V, Pellissier F, Schaad O, Ballivet M. Gene expression analysis of the critical period in the visual cortex. *Mol Cell Neurosci.* 2004;27(1):70–83. doi:10.1016/j.mcn.2004.05.003
39. Hofer SB, Mrsic-Flogel TD, Bonhoeffer T, Hübener M. Experience leaves a lasting structural trace in cortical circuits. *Nature.* 2009;457(7227):313–317. doi:10.1038/nature07487
40. García Del Caño G, Gerrikagoitia I, Goñi O, Martínez-Millán L. Sprouting of the visual corticocollicular terminal field after removal of contralateral retinal inputs in neonatal rabbits. *Exp Brain Res.* 1997;117(3):399–410. doi:10.1007/s002210050234
41. García Del Caño G, Gerrikagoitia I, Martínez-Millán L. Plastic reaction of the rat visual corticocollicular connection after contralateral retinal deafferentiation at the neonatal or adult stage: axonal growth versus reactive synaptogenesis. *J Comp Neurol.* 2002;446(2):166–178. doi:10.1002/cne.10179
42. García Del Caño G, Uria I, Gerrikagoitia I, Martínez-Millán L. Connection from the dorsal column nuclei to the superior colliculus in the rat: topographical organization and somatotopic specific plasticity in response to neonatal enucleation. *J Comp Neurol.* 2004;468(3):410–424. doi:10.1002/cne.10982
43. Rhoades RW. Expansion of the ipsilateral visual corticotectal projection in hamsters subjected to partial lesions of the visual cortex during infancy: anatomical experiments. *J Comp Neurol.* 1981;197(3):425–445. doi:10.1002/cne.901970306
44. Masland RH. The neuronal organization of the retina. *Neuron.* 2012;76(2):266–280. doi:10.1016/j.neuron.2012.10.002
45. Pito M, Bleau M, Bouskila J. The retina: a window into the brain. *Cells.* 2021;10(12):3269. doi:10.3390/cells10123269
46. Adhi M, Duker JS. Optical coherence tomography—current and future applications. *Curr Opin Ophthalmol.* 2013;24(3):213. doi:10.1097/ICU.0b013e32835f8bf8
47. Drexler W, Liu M, Kumar A, Kamali T, Unterhuber A, Leitgeb RA. Optical coherence tomography today: speed, contrast, and multimodality. *J Biomed Opt.* 2014;19(7):71412. doi:10.1117/1.JBO.19.7.071412
48. Toth CA, Narayan DG, Boppart SA, et al. A comparison of retinal morphology viewed by optical coherence tomography and by light microscopy. *Archives of Ophthalmology.* 1997;115(11):1425–1428. doi:10.1001/archoph.1997.01100160595012

49. Gaier ED, Gise R, Heidary G. Imaging amblyopia: insights from optical coherence tomography (OCT). In: *Semin Ophthalmol*. Vol. 34. Taylor & Francis; 2019:303–311.
50. Avram E. CAN optical coherence tomography redefine amblyopia? *Rom J Ophthalmol*. 2017;61(2):95. doi:10.22336/rjo.2017.18
51. Araki S, Miki A, Goto K, et al. Macular retinal and choroidal thickness in unilateral amblyopia using swept-source optical coherence tomography. *BMC Ophthalmol*. 2017;17(1):1–13. doi:10.1186/s12886-017-0559-3
52. Mwachaka PM, Saidi H, Odula PO, Mandela PI. Effect of monocular deprivation on rabbit neural retinal cell densities. *J Ophthalmic Vis Res*. 2015;10(2):144. doi:10.4103/2008-322X.163770
53. Von Noorden GK, Crawford MLJ, Middleditch PR. Effect of lid suture on retinal ganglion cells in *Macaca mulatta*. *Brain Res*. 1977;122(3):437–444. doi:10.1016/0006-8993(77)90455-3
54. Castaño-Castaño S, Martínez-Navarrete G, Morales-Navas M, Fernández-Jover E, Sanchez-Santed F, Nieto-Escámez F. Transcranial direct-current stimulation (tDCS) improves detection of simple bright stimuli by amblyopic long evans rats in the SLAG task and produces an increase of parvalbumin labelled cells in visual cortices. *Brain Res*. 2019;1704:94–102. doi:10.1016/j.brainres.2018.09.039
55. Castaño-Castaño S, García-Moll A, Morales-Navas M, Fernandez E, Sanchez-Santed F, Nieto-Escamez F. Transcranial direct current stimulation improves visual acuity in amblyopic Long-Evans rats. *Brain Res*. 2017;1657:340–346. doi:10.1016/j.brainres.2017.01.003
56. Castaño-Castaño S, Feijoo-Cuaresma M, Paredes-Pacheco J, et al. tDCS recovers depth perception in adult amblyopic rats and reorganizes visual cortex activity. *Behav Brain Res*. 2019;370:111941. doi:10.1016/j.bbr.2019.111941
57. Miller EK, Cohen JD. An integrative theory of prefrontal cortex function. *Annu Rev Neurosci*. 2001;24(1):167–202. doi:10.1146/annurev.neuro.24.1.167
58. Power JD, Cohen AL, Nelson SM, et al. Functional network organization of the human brain. *Neuron*. 2011;72(4):665–678. doi:10.1016/j.neuron.2011.09.006
59. Booher HR, Walk RD. Apparatus for the differential visual depth threshold and its determination in the hooded rat. *Psychon Sci*. 1968;12(5):187–188. doi:10.3758/BF03331262
60. Nitsche MA, Cohen LG, Wassermann EM, et al. Transcranial direct current stimulation: state of the art 2008. *Brain Stimul*. 2008;1(3):206–223. doi:10.1016/j.brs.2008.06.004
61. Blanco R, Martínez-Navarrete G, Pérez-Rico C, et al. A chronic ocular-hypertensive rat model induced by injection of the sclerosant agent polidocanol in the aqueous humor outflow pathway. *Int J Mol Sci*. 2019;20(13):3209. doi:10.3390/ijms20133209
62. Li L, Huang H, Fang F, Liu L, Sun Y, Hu Y. Longitudinal morphological and functional assessment of RGC neurodegeneration after optic nerve crush in mouse. *Front Cell Neurosci*. 2020;14:109. doi:10.3389/fncel.2020.00109
63. Knott EJ, Sheets KG, Zhou Y, Gordon WC, Bazan NG. Spatial correlation of mouse photoreceptor-RPE thickness between SD-OCT and histology. *Exp Eye Res*. 2011;92(2):155–160. doi:10.1016/j.exer.2010.10.009
64. Kim KH, Puoris' Haag M, Maguluri GN, et al. Monitoring mouse retinal degeneration with high-resolution spectral-domain optical coherence tomography. *J Vis*. 2008;8(1):17. doi:10.1167/8.1.17
65. Lekskul A, Wuthisiri W, Padungkiatsagul T. Evaluation of retinal structure in unilateral amblyopia using spectral domain optical coherence tomography. *J AAPOS*. 2018;22(5):386–389. doi:10.1016/j.jaapos.2018.05.014
66. Parikh R, Sachdeva V, Kekunnaya R, Rao BV, Parikh S, Thomas R. Retinal nerve fiber layer thickness in amblyopia. *Indian J Ophthalmol*. 2022;70(8):3065. doi:10.4103/ijjo.IJO_2875_21
67. Alotaibi AG, Al Enazi B. Unilateral amblyopia: optical coherence tomography findings. *Saudi J Ophthalmol*. 2011;25(4):405–409. doi:10.1016/j.sjopt.2011.06.001
68. Masri OS, Abiad B, Darwich MJ, et al. Morphological changes in amblyopic eyes in choriocapillaris and Sattler's layer in comparison to healthy eyes, and in retinal nerve fiber layer in comparison to fellow eyes through quantification of mean reflectivity: a pilot study. *PLoS One*. 2021;16(8):e0255735. doi:10.1371/journal.pone.0255735
69. Rasch E, Swift H, Riesen AH, Chow KL. Altered structure and composition of retinal cells in dark-reared mammals. *Exp Cell Res*. 1961;25(2):348–363. doi:10.1016/0014-4827(61)90285-3
70. Spiegel DP, Li J, Hess RF, et al. Transcranial direct current stimulation enhances recovery of stereopsis in adults with amblyopia. *Neurotherapeutics*. 2013;10(4):831. doi:10.1007/S13311-013-0200-Y
71. Ding Z, Li J, Spiegel DP, et al. The effect of transcranial direct current stimulation on contrast sensitivity and visual evoked potential amplitude in adults with amblyopia. *Sci Rep*. 2016;6(1):6. doi:10.1038/SREP19280
72. Weiskrantz L. Sensory deprivation and the cat's optic nervous system. *Nature*. 1958;181(4615):1047–1050. doi:10.1038/1811047b0
73. Curcio CA, Allen KA. Topography of ganglion cells in human retina. *J Comp Neurol*. 1990;300(1):5–25. doi:10.1002/cne.903000103
74. Strang CE, Ray MK, Boggiano MM, Amthor FR. Effects of tDCS-like electrical stimulation on retinal ganglion cells. *Eye Brain*. 2018; Volume 10:65–78. doi:10.2147/EB.S163914
75. Spiegel DP, Byblow WD, Hess RF, Thompson B. Anodal transcranial direct current stimulation transiently improves contrast sensitivity and normalizes visual cortex activation in individuals with Amblyopia. *Neurorehabil Neural Repair*. 2013;27(8):760–769. doi:10.1177/1545968313491006
76. Levi DM. Rethinking amblyopia 2020. *Vision Res*. 2020;176:118–129. doi:10.1016/j.visres.2020.07.014
77. Bocci T, Nasini F, Caleo M, et al. Unilateral application of cathodal tDCS reduces transcallosal inhibition and improves visual acuity in amblyopic patients. *Front Behav Neurosci*. 2018;12:12. doi:10.3389/fnbeh.2018.00109
78. Donkor R, Silva AE, Teske C, Wallis-Duffy M, Johnson AP, Thompson B. Repetitive visual cortex transcranial random noise stimulation in adults with amblyopia. *Sci Rep*. 2021;11(1):3029. doi:10.1038/s41598-020-80843-8
79. Moret B, Camilleri R, Pavan A, et al. Differential effects of high-frequency transcranial random noise stimulation (hf-tRNS) on contrast sensitivity and visual acuity when combined with a short perceptual training in adults with amblyopia. *Neuropsychologia*. 2018;114:125–133. doi:10.1016/j.neuropsychologia.2018.04.017

Eye and Brain**Dovepress****Publish your work in this journal**

Eye and Brain is an international, peer-reviewed, open access journal focusing on clinical and experimental research in the field of neuro-ophthalmology. All aspects of patient care are addressed within the journal as well as basic research. Papers covering original research, basic science, clinical and epidemiological studies, reviews and evaluations, guidelines, expert opinion and commentary, case reports and extended reports are welcome. The manuscript management system is completely online and includes a very quick and fair peer-review system, which is all easy to use. Visit <http://www.dovepress.com/testimonials.php> to read real quotes from published authors.

Submit your manuscript here: <https://www.dovepress.com/eye-and-brain-journal>