

Bio-Interventional Cyclodialysis and Allograft Scleral Reinforcement for Uveoscleral Outflow Enhancement in Open-Angle Glaucoma Patients: One-Year Clinical Outcomes

Tsontcho Ianchulev^{1,*}, Robert N Weinreb^{2,*}, Ernesto A Calvo^{3,*}, James Lewis^{4,*}, Gautam Kamthan^{1,*}, Arsham Sheybani^{5,*}, Douglas J Rhee^{6,*}, Iqbal K Ahmed^{7,*}

¹Department of Ophthalmology, New York Eye and Ear of Mount Sinai, New York, NY, USA; ²Shiley Eye Institute, University of California San Diego, La Jolla, CA, USA; ³Clinica de Ojos Orillac-Calvo, Panama City, Panama; ⁴Cataract Philadelphia, Elkins Park, PA, USA; ⁵Department of Ophthalmology and Visual Sciences, Washington University School of Medicine, St. Louis, MO, USA; ⁶Department of Ophthalmology & Visual Sciences, University Hospitals, Case Western Reserve University, Cleveland, OH, USA; ⁷John Moran Eye Center, University of Utah, Salt Lake City, UT, USA

*These authors contributed equally to this work

Correspondence: Tsontcho Ianchulev, Ophthalmology, New York Eye and Ear of Mount Sinai, New York, NY, USA, Email tianchul@yahoo.com

Background: To evaluate the one-year safety and effectiveness of bio-interventional cyclodialysis and scleral reinforcement in open-angle glaucoma (OAG) patients undergoing cataract surgery.

Methods: An ab-interno approach was used to create a sectoral cyclodialysis in OAG patients who were prospectively followed in a consecutive case series. Subsequent visco-cycloplasty with scleral reinforcement using homologous minimally modified allograft scaffold was completed to maintain patency of the cyclodialysis reservoir and increase uveoscleral outflow. Outcomes were mean medicated IOP and mean number of IOP-lowering medications. Safety outcomes were adverse events (AEs) and best-corrected visual acuity (BCVA) changes.

Results: Successful cyclodialysis and allograft bio-scaffold reinforcement was achieved in 117 eyes. There was minimal intraoperative bleeding and few post-operative adverse events. At baseline, mean BCVA was 0.48 (95% CI: 0.42–0.54; 20/40 Snellen) and mean \pm SD medicated IOP was 20.2 ± 6.0 mmHg on 1.4 ± 1.3 IOP-lowering medications. At 12 months, there was a 27.1% reduction from baseline mean medicated IOP. In eyes with medicated baseline IOP > 21 mmHg ($n = 45$), there was a 39.7% paired IOP reduction at 12 months with a concurrent reduction in the mean number of IOP lowering medications to 0.8 ± 0.9 which were statistically significant ($p < 0.01$). For all eyes, 81.9% achieved a medicated IOP ≤ 18 mmHg with no increase in medications at 12 months. To achieve target IOP control, secondary glaucoma surgery was performed in 3.2% of the cases.

Conclusion: IOP lowering through uveoscleral outflow enhancement can be achieved by means of a bio-interventional cyclodialysis procedure with allograft scleral reinforcement.

Keywords: glaucoma, open-angle, intraocular pressure, cataract, allografts

Introduction

The worldwide prevalence of open-angle glaucoma (OAG), a leading cause of global blindness, exceeds 80 million, with more than 3 million cases in the US.^{1,2} Surgical approaches for glaucoma treatment aim to lower IOP by increasing aqueous drainage and outflow.^{3–6} While the majority of the outflow enhancing surgical procedures augment the trabecular outflow pathway, few surgical options exist for the other major outflow pathway – the uveoscleral pathway. The cornerstone of surgical outflow enhancement of the uveoscleral pathway remains the cyclodialysis procedure.^{7–10} As early as 1905 Heine first devised and reported the creation of surgical cyclodialysis to create an adjunct aqueous conduit for uveoscleral outflow enhancement,¹¹ and later in the mid 1900s it was recognized widely as a treatment modality for

open angle and aphakic glaucoma. Various modifications of the primary surgical technique have been tried including a combination of procedures of cyclodialysis with viscoelastic or other implantable material for improved structural support and durability.

From a mechanistic standpoint, physiologic studies inform of a dual mechanism of IOP lowering after a cyclodialysis—both through increased uveoscleral outflow as well as reduction in aqueous production from the detached ciliary body.^{12,13} In the last decade, with the advent of more targeted interventional approaches, there has been increased interest in more advanced approaches and surgical techniques, which can offer much-needed access to one of the major remaining untapped outflow pathways for aqueous egress.^{14–16}

Bio-reinforced cyclodialysis technique using adjunct allogeneic scleral tissue scaffolding as reinforcement can be a natural solution to the premature closure of cyclodialysis intervention by maintaining a permanent uveoscleral conduit for aqueous outflow. An internal uveoscleral filtration reservoir is thus supported by the allogeneic bio-scaffold which acts as a biologic non-absorbable spacer between the ciliary body and the adjacent scleral wall. Scleral allograft tissue has been safely used for decades in glaucoma surgery as a reinforcement adjunct to conventional subconjunctival aqueous drainage implants.¹⁷ From a material science and bio-compatibility perspective, scleral allograft tissue offers significant advantages to exogenous implantable hardware. Its acellular collagen matrix properties are homologous to the surrounding tissue and offer durability, structural stability, permeability, and hydrophilicity.¹⁸ It has been well established that implant material properties are critical to the healing, rejection, and inflammatory reaction of the surrounding tissues. One of the most salient determinants of implant fibrosis, granulomatous inflammation, and macrophage activation is the stiffness mismatch between the implant and the physical/elastic properties of the surrounding tissues.¹⁰ Minimizing this gap by matching the stiffness of the implant to the surrounding tissue can improve implant biocompatibility.¹⁹ Optical coherence tomography (OCT) imaging of the scleral allograft confirms its homogeneity and compatibility to the native supraciliary anatomy (Figure 1) – in distinct contrast to synthetic implants.^{20–22} Such bio-conforming and bio-compatible material properties are well suited for surgical application as a natural substrate for intraocular structural reinforcement, stenting, scaffolding or stabilization.

Here, we report long-term results and clinical experience with bio-scaffolded cyclodialysis (BSC) intervention for the enhancement of uveoscleral outflow and internal aqueous filtration in patients with OAG.

Methods

We report on the consecutive case series of OAG patients with mild, moderate, or severe visual field loss who underwent ab-interno BSC using a homologous donor scleral allograft by 12 surgeons from the CREST US and OUS clinical study (clinicaltrials.gov NCT05506423). The CREST clinical study is a real-world evidence registry where patients are followed prospectively through 24 months after undergoing cyclodialysis intervention. The study protocol adhered to the tenets of the Declaration of Helsinki and was approved by the WCG central institutional review board (Princeton, NJ). Eligible patients had to meet the criteria of confirmed primary OAG with open angles Shaffer grade 3+ in all 4 quadrants, operable cataract, and no exclusionary co-morbidities such as prior incisional glaucoma surgery, potentially

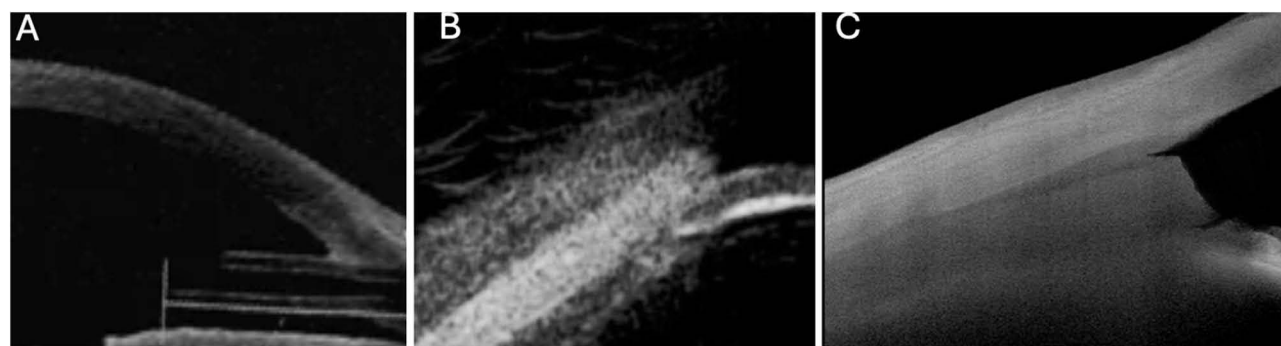


Figure 1 OCT gonio-imaging of implantable hardware materials vs allograft biotissue: (A) Ahmed™ glaucoma drainage device, (B) Miniject™ supraciliary device and (C) AlloFlo™ allogeneic scleral bio-scaffold. The homologous bio-conforming non-rigid allograft is positioned in an AC-clear endoscleral deployment at the iris root.

sight-threatening visual field loss within central 10°, or clinically significant corneal opacity. OAG patients were enrolled and had received standard-of-care pre-operative workup prior to the combined cataract and glaucoma procedure. Informed consent was obtained from eligible patients prior to enrolment in the study.

Allograft Bio-Scaffold Scleral Implant

The allograft bio-scaffold is prepared using a proprietary minimal modification and manipulation process (Iantrek, Inc.) from donor acellular scleral allogeneic tissue from an eye tissue bank following standard screening protocols for infectious disease. The biotissue is packaged sterile with a 1-year shelf life. Dimensionally, the allograft is an elongated micro-trephined construct 5-mm in length and 500-microns in width.

Bio-Interventional Cyclodialysis Procedure with Scleral Reinforcement

Procedurally, the scleral reinforcement is done using advanced instrumentation and surgical technique for ab-interno intervention. In eyes undergoing a concurrent cataract procedure, the cyclodialysis and scleral reinforcement interventions are performed following the phacoemulsification surgery. Topical anaesthesia with or without intracameral lidocaine was employed as per the investigator's standard protocol. The eye and microscope are positioned for standard gonio-intervention.²² After achieving adequate visualization and confirming open-angle anatomy, the cyclodialysis procedure is performed to dissect and separate the ciliary body from the scleral wall in order to create a sectoral 1–2 clock hours of dialysis using micro-surgical cyclodialysis instrumentation. Visco-cycloplasty is then performed with injection of an ophthalmic viscoelastic device (OVD), with sufficient volume to augment the cleft and create an internal reservoir, as well as to tamponade any reflux bleeding.

After the cyclodialysis and cycloplasty interventions, the allograft spacer deployment procedure is undertaken for reinforcement of the endoscleral wall around the cyclodialysis. The allograft bio-scaffold is inserted between the ciliary body at the endoscleral plane using the CycloPen interventional system (Iantrek Inc., White Plains, NY). Precise anatomic placement is important for AC-clear deployment with the proximal end of the bio-tissue positioned “flush” with the iris root (Figure 2). Irrigation/aspiration is performed to evacuate any viscoelastic. Before completion of the surgery, gonio-confirmation is done to verify implant position. A standard postoperative regimen of topical antibiotics and steroids is indicated for 30 days post-op (fourth-generation fluoroquinolone and prednisolone 4×/day), and patients return for follow-up examinations at 1 day, 1-week, 1-month, 6-months, and 12-months.

Data Analysis

Outcome measures were collected for ocular safety, medication burden and IOP. Continuous data are expressed as mean \pm SD, with differences in starting versus 12-month IOP and medication numbers compared using paired two-tailed *t*-tests. Categorical data are presented as numbers and percentages and were compared where indicated using Fisher's exact test with 2×2 contingency tables. Statistical significance was defined as $p < 0.05$. Statistical and graphing software included Excel (Microsoft Corp., Redmond, WA) and Prism v.9.0 (GraphPad Software, La Jolla, CA).

Results

The consecutive case series comprised 117 eyes of 89 patients (28 bilateral) with OAG that had undergone micro-interventional cyclodialysis and allograft scleral reinforcement prior to February 14, 2023, and had long-term evaluable data at either the 6- or 12-month timepoint. Of the 117 eyes, there were 12 eyes of 9 patients (3 bilateral), which did not have evaluable data at the 12M timepoint in the registry due to loss to follow-up.

Demographic and baseline characteristics of the subjects are presented in Table 1. Mean medicated IOP was 20.2 ± 6.0 mmHg, and subjects used 1.4 ± 1.3 IOP-lowering medications. At 12 months post-operatively ($n = 105$), mean \pm SD IOP was 13.9 ± 3.9 mmHg, and the mean \pm SD number of IOP lowering medications was 0.8 ± 0.9 (Figure 3). The 6.3mm reduction in mean medicated IOP from baseline through 12 months post-operatively was statistically significant ($p < 0.01$). Additionally, 86 out of 105 eyes evaluable at 12M (81.9%) achieved a medicated IOP of ≤ 18 mmHg while on the same or fewer medications. Of eyes with baseline IOP ≥ 21 mmHg evaluable at 12M ($n = 45$), mean medicated IOP

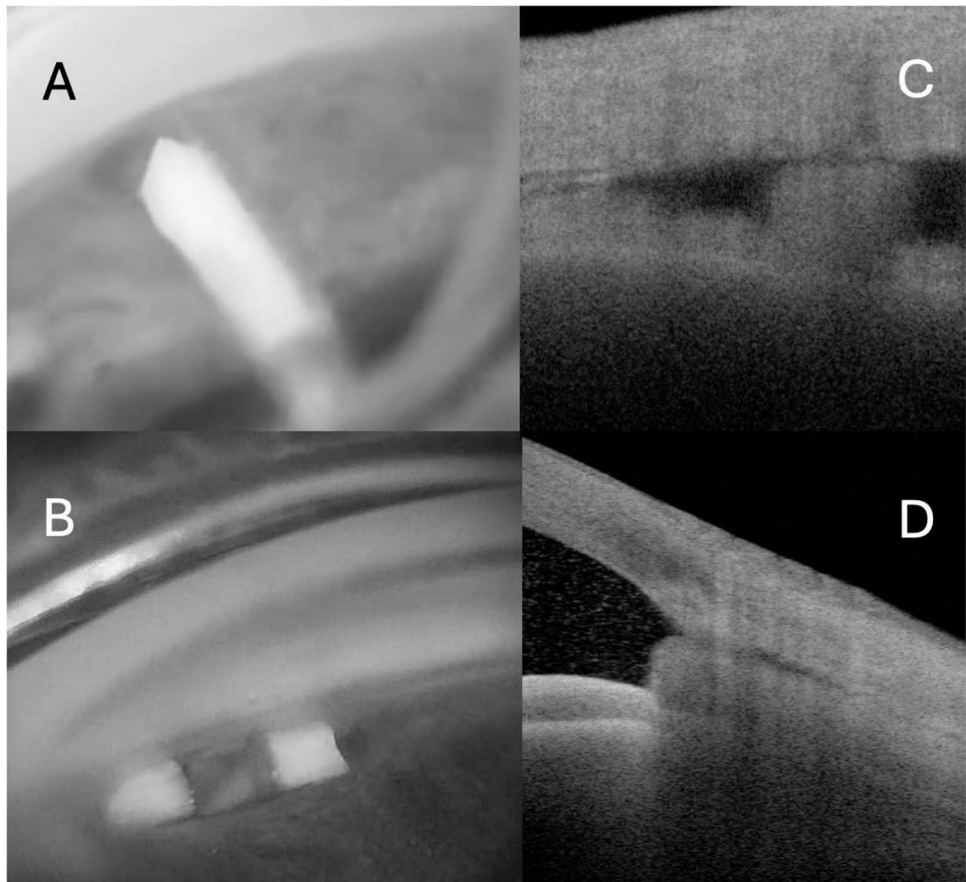


Figure 2 Imaging of the bio-reinforced cyclodialysis post-operatively. The allograft is shown within the transparent CycloPen™ micro-interventional delivery system during implantation (A). After implantation, gonioscopy shows the allograft bio-scaffold in proper position without anterior chamber prominence (B); Ultrasound bio-microscopy images of the allograft bio-tissue post-implantation demonstrating endoscleral reinforcement of the cyclodialysis cleft. (cross-sectional (C); and longitudinal (D)). Homologous allograft material is iso-dense on OCT imaging and nearly indistinguishable from native scleral tissue.

reduced pairwise by 39.7% by 12M, and 38 (84.4%) eyes achieved a medicated IOP reduction $\geq 20\%$ while on the same or fewer medications.

There were no vision-threatening intraoperative or postoperative complications (Table 2). In most cases, there was minimal blood reflux from the cyclodialysis cleft, which was not associated with any significant postoperative hyphema. No cases of severe or persistent inflammation or hyphema occurred, and no biotissue migration or corneal touch was

Table 1 Baseline Characteristics

Sample size, eyes, N	117
Patients, N	89
Age, mean \pm SD, years	70.4 \pm 8.7
Ethnicity	
White, non-Hispanic, n (%)	32 (27.3%)
White, Hispanic, n (%)	50 (42.7%)
Black, n (%)	35 (29.9%)
Gender: female, n (%)	63 (53.8%)

(Continued)

Table 1 (Continued).

Eyes undergoing concomitant phaco-emulsification cataract surgery	108 (96.4%)
Baseline BCVA, medicated, mean decimal value (95% CI)	0.48 (0.42–0.54)
Baseline IOP, mmHg, mean \pm SD	20.2 \pm 6.0
Number of IOP-lowering drugs, mean \pm SD	1.4 \pm 1.3

Abbreviations: BCVA, Best Corrected Visual Acuity; IOP, Intra-Ocular Pressure.

observed through the 12-month follow-up period. Transient numeric hypotony, defined as less than 6 mmHg without visually significant sequelae, occurred in 1 eye and at the 1-week visit and recovered by the 1M visit, and was controlled at 14 mmHg on 1 medication by 12M.

There were 3 patients who developed cystoid macular edema (CME) in the setting of a concurrent phaco procedure, which the investigators determined were not attributable to the glaucoma intervention (Table 2). All of those were mild, transient, not associated with significant vision loss, and resolved completely in the postoperative period. In one case, the CME was in the setting of pre-proliferative diabetic retinopathy. A single patient with a macular fold was in the setting of uneventful cataract and glaucoma surgery. The patient's post-operative IOP was consistently above 7 mmHg and was not associated with macular edema or persistent iritis. There was no decrease in visual acuity and achieved full resolution during the study follow-up period.

There were 9 eyes (7.7%) which experienced post-operative IOP elevation, defined as IOP \geq 30 mmHg. Two eyes (1.7%) received adjunct SLT to achieve target IOP control, including one which had previously received YAG laser treatment for iris synechia. One eye (0.8%) underwent a paracentesis at 2 weeks post-op. Intraocular surgical intervention for additional IOP control was needed in 4 eyes (3.2%): one case of an Ahmed valve (New World Medical, Rancho Cucamonga, CA, USA), one eye a XEN gel stent (Allergan, Naperville, IL, USA), two cases of CPC where one was in

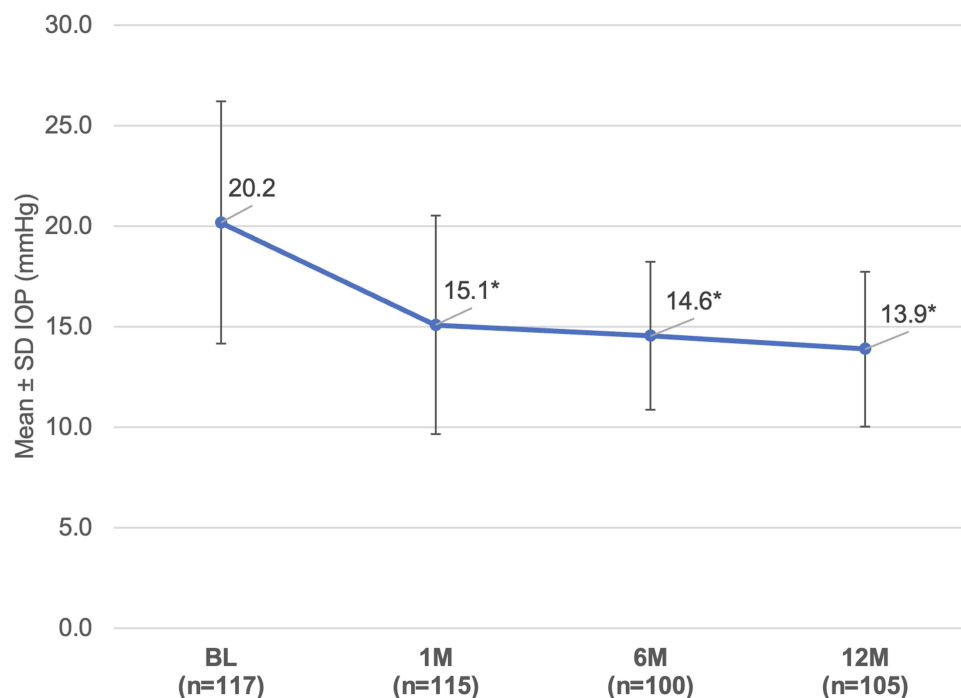


Figure 3 The mean \pm SD IOP was statistically significantly ($p < 0.001$) lower than baseline at all available timepoints through M12, with a 27.1% paired reduction at M12 vs baseline. (* $p < 0.01$).

Table 2 Intraoperative and Postoperative Adverse Events Within 12 Months Following Bio-Interventional Cyclodialysis with Allograft Scleral Reinforcement

Safety Outcome	Events, n (%)
>2 lines drop in BCVA, n (%)	0 (0%)
Persistent inflammation (>IM), n (%)	0 (0%)
Severe inflammation (grade 4+), n (%)	0 (0%)
Biotissue migration, n (%)	0 (0%)
Biotissue-corneal touch, n (%)	0 (0%)
Persistent corneal edema (>IM), n (%)	0 (0%)
Transient post-op IOP elevation, n (%)	9 (7.7%)
Transient hyphema greater than 2 mm present after 1 day postoperatively	3 (2.6%)
Transient hypotony, no visual sequelae	1 (0.8%)
Transient macular edema (phaco surgery-related)	4 (3.4%)
Zonular dehiscence during phaco surgery	1 (0.8%)

Abbreviations: BCVA, Best Corrected Visual Acuity; IOP, Intra-Ocular Pressure.

combination with a goniotomy. Additionally, 3 cases (2.6%) had follow-on procedures related to the phaco procedure and not related to the glaucoma intervention (Table 3).

Overall visual acuity increased from an average baseline BCVA of 0.48 decimal (20/40 Snellen; 0.30 LogMAR) to 0.77 decimal (20/28 Snellen; 0.15 LogMAR) at 12 months consistent with the phaco cataract procedure.

There were a total of 59 eyes with available preoperative and 12M endothelial cell count (ECC) data. The mean \pm SD endothelial cell density at baseline and at 12M were 2390.0 ± 445.8 and 2235.4 ± 377.9 , respectively. There were no eyes

Table 3 Secondary Surgical Interventions Related to Cataract and Glaucoma Procedures

Intervention	Number of Eyes N=117
Secondary Phaco-Related Interventions	3 (2.6%)
Cortical remnant removal from phaco procedure	1 (0.8%)
YAG laser capsulotomy	2 (1.7%)
Secondary Glaucoma Surgeries	4 (3.2%)
Cyclophotocoagulation	1 (0.8%)
Goniotomy with adjunct Cyclophotocoagulation	1 (0.8%)
Ahmed valve	1 (0.8%)
Xen gel stent	1 (0.8%)
Additional Non-invasive Procedures	4 (3.2%)
Paracentesis	1 (0.8%)
YAG laser for iris synechia lysis	1 (0.8%)
Selective laser trabeculoplasty	2 (1.7%)

with greater than 25% endothelial cell loss and the 6.5% mean reduction in ECD is in the range reported for stand-alone phaco-emulsification cataract intervention.²³

Discussion

This study provides results from our clinical experience with a bio-interventional surgical procedure for uveoscleral outflow enhancement using cyclodialysis with scleral allograft reinforcement for internal aqueous filtration. In 117 eyes, we demonstrate a robust physiologic effect of IOP lowering and medication reduction through 12 months of follow-up in patients undergoing a concurrent cataract procedure. In addition, the surgical safety shows no unanticipated or other serious treatment-emergent adverse events in this rather large consecutive case series – an encouraging safety profile likely related to the minimally invasive nature of the cyclodialysis technique as well as the biocompatible and bio-conforming profile of the homologous allogeneic material. In addition, the results demonstrate stability, retention, and long-term biocompatibility and durability of the allograft bio-matrix as well as the reinforced cyclodialysis conduit for internal filtration.

The IOP-lowering effect of trabecular outflow interventions is well established, both in the setting of concurrent cataract surgery and as a standalone procedure.^{24–28} The results of BSC compare favorably with the effectiveness seen from other real-world evidence glaucoma interventional studies in a similar cohort of patients (all-comers with respect to baseline medicated IOP range). Bio-reinforced cyclodialysis demonstrates significant IOP lowering (6.3 mmHg IOP reduction) through 1 year, alongside a reduction in IOP-lowering medication burden. With all the caveats of cross-study comparison and lack of direct head-to-head trial, the outcomes with uveoscleral outflow enhancement exceed the results reported with the real-world use of trabecular stent implants such as Hydrus and iStent inject (Table 4), where the IOP lowering effect is modest with 3.1 and 2.2 mmHg IOP reductions, respectively, through 2 years of follow-up.²⁹ Our population included more advanced glaucoma patients whose pre-operative medicated IOP baseline was higher compared to the study population of trabecular stents, which could also be contributing to the larger effect size.

When considering a subset of subjects with a baseline IOP over 18 mmHg (n = 68), the IOP-lowering effect was even more profound and increased from 6.3 mm Hg to 8.6 mm Hg (a 39.7% paired IOP reduction).

Both the cyclodialysis procedure and the scleral reinforcement procedures were well tolerated, demonstrating a MIGS-like safety profile without interfering with the outcomes and the follow-up of phaco-cataract surgery. The

Table 4 Comparison to Trabecular Outflow Enhancement from Real-World Interventional Studies with iStent and Hydrus versus Uveoscleral Outflow Enhancement with Bio-Reinforced Cyclodialysis

	Hydrus²⁹ N=120 2-Year	iStent inject²⁹ N=224 2-Year	Bio-Interventional Cyclodialysis with Allograft Scleral Reinforcement N=117 1-Year
In combination with cataract surgery	Yes	Yes	Yes
Baseline medicated IOP, mmHg	18.1 ± 5.5 ^a	16.3 ± 4.4	20.2 ± 6.0
Final medicated IOP, mmHg	15.1 ± 5.0	14.1 ± 4.2	13.9 ± 3.9
Mean IOP Change, mmHg	−3.1	−2.2	−6.3
Baseline Medications, n	2.1 ± 1.2	1.5 ± 1.2	1.3 ± 1.1
Final Medications, n	1.3 ± 1.4	0.8 ± 1.2	0.8 ± 0.9
Mean Change in Medications (95% CI), n	−0.8	−0.8	−0.5
Complete success, 18 mmHg, n ^b	15.8%	22.3%	26.7%

Notes: ^aData provided as mean ± SD or mean (95% CI range), as appropriate. ^bComplete success was defined as ≥20% IOP reduction with final IOP ≤ 18 mmHg with 0 glaucoma medications used at the endpoint.

flexible and homologous nature of the acellular allogeneic bio-matrix showed no significant intraocular reaction with no appreciable increase in iritis, which is consistent with the expectations of an inert, biocompatible material. The non-slippery non-rigid biomechanics of the scleral allograft may explain the lack of tissue migration in the post-operative period. This further highlights an essential aspect of corneal and endothelial safety where the bio-scaffold is fully protected within the cleft with no protruding or rigid hardware in the anterior chamber – an important attribute of this interventional approach.

Control of foreign body reaction, fibrovascular response and premature cyclodialysis “restenosis” and closure can be transformational to the clinical utility and application of one of the oldest conventional glaucoma surgeries. In the age of new interventional approaches for IOP lowering, combining two well-established and known surgical modalities, namely cyclodialysis and scleral allograft reinforcement, in a synergistic surgical framework to create improved ab-interno intervention for uveoscleral outflow enhancement is compelling.

While this study is informative, certain inherent limitations need to be highlighted. This is a consecutive case-series from a real-world, prospective, observational registry. There was no standardization of pre-operative, operative and post-operative care, all of which were a factor of the surgeon’s individual judgment and preference. There was no protocolized schedule on medication re-introduction or clinical rescue. It is nevertheless encouraging to see that neither the IOP efficacy nor the medication effect was attenuated by variable standard-of-care practice patterns of the individual physicians. Surgeons also tended to enroll more patients with moderate glaucoma, especially early in their surgical experience – whether because of tailored expectations from a uveoscleral outflow enhancing procedure or guarded conservative enrolment early in the learning curve. This may also account for the more robust efficacy seen compared to trabecular stents given the higher baseline medicated IOP. Nevertheless, 49.6% of patients were mild glaucoma with medicated IOP below 18mmHg. The vast majority of cases were combined with phacoemulsification cataract surgery, so the IOP lowering effect reflects the inherent contribution of the cataract procedure, which we know from the MIGS literature is additive to the glaucoma procedure. The profound efficacy seen in this uncontrolled investigation as compared to outcomes from other MIGS studies is reassuring and informative. In previous trabecular implant RCT studies, there is an incremental IOP lowering effect over phaco alone of approximately 1–2 mmHg.³⁰ Notably, our study effect size is robust and sustained across a significant sample size of patients over 12 months, but certainly no surrogate or substitute for surrogate randomized data. Another limitation of our study is that medication terminal washout is impossible with real-world evidence studies, which makes it difficult to isolate the effects of concomitant IOP-lowering eye drop use. Such is also the case with specular microscopy, which is not standard-of-care and not available in most clinics. Certainly, this is less clinically applicable with a clear-chamber cyclodialysis bio-interventional procedure where there is no protruding rigid hardware into the anterior chamber. It is also encouraging to see low levels of endothelial cell loss in the subset of sites where specular microscopy was available, which is consistent with reported levels for stand-alone phaco cataract surgery.²³

In conclusion, our results inform an improved technique and advancement of the cyclodialysis surgical paradigm with a novel bio-interventional approach using allograft scleral reinforcement. This can achieve sustained and enhanced internal outflow through the uveoscleral pathway and provide much-needed treatment options for IOP-lowering in glaucoma patients.

Data Sharing Statement

Data of the clinical trial results of the CREST investigation (NCT05506423) will be shared and publicly available on clinicaltrials.gov consistent with the Applicable Clinical Trial guidelines for results availability of the NIH/Clinicaltrial.gov registration. The results will be posted on the clinicaltrials.gov website after the conclusion of the study.

Acknowledgments

The authors thank Matt Silverman, PhD (Biomedical Publishing Solutions, Panama City, FL; mattsilver@yahoo.com) and Ravinder D. Pamnani (Stanford Byers Center for Biodesign, Stanford, CA, and Iantrek, Inc., White Plains, NY) for scientific, analytical, and writing assistance.

Funding

The study was financially supported by Iantrek, Inc. (White Plains, NY).

Disclosure

5 authors are consultants for Iantrek, Inc. (TI, RNW, GK, DJR, IKA). Three authors are investigators for the CREST-US/OUS real-world prospective observational clinical study, sponsored by Iantrek (EC, JL, AS). Four authors own equity in Iantrek, Inc. (TI, RNW, GK, IKA). One author is the inventor of the underlying technology evaluated in this study (TI). RNW reports personal fees from iSTAR Medical, outside the submitted work. AS also reports personal fees from Allergan/AbbVie, Alcon, Nova Eye, and Glaukos, during the conduct of the study. DJR also reports grants, personal fees from AbbVie/Allergan - H, C, RGI; Alcon - H, C, RGI; Ocular Therapeutix - RGI; Iantrek - C, RGI; iStar - C, grants, personal fees from Alcon, grants from Ocular Therapeutix, personal fees from iStar, personal fees from Qlaris, during the conduct of the study. IKA also reports personal fees from AbbVie, Ace Vision, Alcon, Aliph Medical, Aquea Health, Arcscan, Avellino Lab USA, Avisi, Balance Ophthalmics, Bausch and Lomb, Beaver Visitec, Belkin Vision, Bionode, Carl Zeiss, Centricity Vision Corneat Vision, Custom Surgical, Elios Vision, Elutimed, Eye to Eye TeleHealth, EyeMed, EyeQ Technologies, Exhaura Limited, Glaukos, Gore, Hexiris Pharma, InjectSense, Iridex, iCare, iStar Medical, Johnson & Johnson Vision, LayerBio, Liquid Medical, Long Bridge Medical Inc, Medicontur, MST Surgical, Myra Vision, New World Medical, Nove Eye, Ocular Instruments, Ocular Therapeutics, Oculus Surgical, OcuSciences, Omega Ophthalmics, Peripherex, PolyActiva, PulseMedica, Radiance Therapeutics, RadiusXr, Rheon Medical, Ripple Therapeutics, Sanoculis, Santen, Singapore Biodesign, Shifamed LLC, Sight Science, Smartlens, Stroma, Thea Pharma, TFS Health Science, Vialase, Visci Ltd, Visus Therapeutics, Vizzario, and Zilia Inc, outside the submitted work.

References

1. Vision Loss Expert Group of the Global Burden of Disease Study; GBD 2019 Blindness and Vision Impairment Collaborators. Global estimates on the number of people blind or visually impaired by glaucoma: a meta-analysis from 2000 to 2020. *Eye*. 2024. PMID: 38565601. doi:10.1038/s41433-024-02995-5
2. Zhao C, Ding Q, Yang Z. Burdens and trends of blindness and vision loss among those aged 55 years and older: a systematic analysis for the Global Burden of Disease Study 2019. *Eur J Ophthalmol*. 2024;11206721241238878. PMID: 38454852. doi:10.1177/11206721241238878
3. Richter GM, Coleman AL. Minimally invasive glaucoma surgery: current status and future prospects. *Clin Ophthalmol*. 2016;10:189–206. PMID: 26869753. doi:10.2147/OPTH.S80490
4. Birnbaum FA, Neeson C, Solá-Del Valle D. Microinvasive glaucoma surgery: an evidence-based review. *Semin Ophthalmol*. 2021;36(8):772–786. PMID: 34297650. doi:10.1080/08820538.2021.1903513
5. Nichani P, Popovic MM, Schlenker MB, Park J, Ahmed IIK. Microinvasive glaucoma surgery: a review of 3476 eyes. *Surv Ophthalmol*. 2021;66(5):714–742. PMID: 32998003. doi:10.1016/j.survophthal.2020.09.005
6. Samuelson TW, Katz LJ, Wells JM, Duh YJ, Giamporcaro JE; US iStent Study Group. Randomized evaluation of the trabecular micro-bypass stent with phacoemulsification in patients with glaucoma and cataract. *Ophthalmology*. 2011;118(3):459–467. doi:10.1016/j.ophtha.2010.07.007
7. Ahmed IIK, Fea A, Au L, et al. COMPARE investigators. A prospective randomized trial comparing Hydrus and iStent microinvasive glaucoma surgery implants for standalone treatment of open-angle glaucoma: the COMPARE study. *Ophthalmology*. 2020;127(1):52–61. doi:10.1016/j.ophtha.2019.04.034
8. Fea AM, Ahmed II, Lavia C, et al. Hydrus microstent compared to selective laser trabeculoplasty in primary open angle glaucoma: one year results. *Clin Exp Ophthalmol*. 2017;45(2):120–127. doi:10.1111/ceo.12805
9. Laspas P, Garcia-Feijoo J, Martinez-de-la-Casa JM, et al. Three-year results of Hydrus microstent with phacoemulsification. *Ophthalmol Glaucoma*. 2019;2(6):440–442. doi:10.1016/j.ogla.2019.08.006
10. Ni Y, Qi H, Zhang F, et al. Macrophages modulate stiffness-related foreign body responses through plasma membrane deformation. *Proc Natl Acad Sci USA*. 2023;120(3):e2213837120. doi:10.1073/pnas.2213837120
11. Böke H. Zur Geschichte der Zyklodialyse. In memoriam Leopold Heine 1870–1940 [History of cyclodialysis. In memory of Leopold Heine 1870–1940]. *Klin Monbl Augenheilkd*. 1990;197(4):340–348. German. doi:10.1055/s-2008-1046291
12. Toris CB, Pederson JE. Effect of intraocular pressure on uveoscleral outflow following cyclodialysis in the monkey eye. *Invest Ophthalmol Vis Sci*. 1985;26(12):1745–1749. PMID: 4066210.
13. Suguro K, Toris CB, Pederson JE. Uveoscleral outflow following cyclodialysis in the monkey eye using a fluorescent tracer. *Invest Ophthalmol Vis Sci*. 1985;26(6):810–813.
14. Dada T, Shakrawal J, Ramesh P, Sethi A. Trabeculectomy augmented with limited deep sclerectomy and cyclodialysis with use of scleral tissue as a spacer. *J Ophthalmic Vis Res*. 2022;17(4):596–600. doi:10.18502/jovr.v17i4.12342
15. Jordan JF, Engels BF, Dinslage S, et al. A novel approach to suprachoroidal drainage for the surgical treatment of intractable glaucoma. *J Glaucoma*. 2006;15(3):200–205. doi:10.1097/01.jig.0000212207.79899.85

16. Eleinen KGA, Makhlof SA, Barhooma MG, EL Shiw HT, Nagaty MWM, AbdelAti IM. Cyclodialysis revival of an abandoned technique in glaucoma surgery. Abstract. 6th International Conference & expo on euro optometry and vision science. *J Clin Exp Ophthalmol*. 2021.
17. Freedman J. Scleral patch grafts with Molteno setons. *Ophthalmic Surg*. 1987;18(7):532–534.
18. Capuani S, Malgir G, Chua CYX, Grattoni A. Advanced strategies to thwart foreign body response to implantable devices. *Bioeng Transl Med*. 2022;7(3):e10300. doi:10.1002/btm2.10300
19. De Francesco T, Ianchulev T, Rhee DJ, Gentile RC, Pasquale LR, Ahmed IIK. The evolving surgical paradigm of scleral allograft bio-tissue use in ophthalmic surgery: techniques and clinical indications for Ab-Externo and Ab-Interno scleral reinforcement. *Clin Ophthalmol*. 2024;18:1789–1795. doi:10.2147/OPTH.S462719
20. Vold S, Ahmed II, Craven ER, et al.; CyPass Study Group. Two-year COMPASS trial results: supraciliary microstenting with phacoemulsification in patients with open-angle glaucoma and cataracts. *Ophthalmology*. 2016;123(10):2103–2112. doi:10.1016/j.ophtha.2016.06.032
21. Figus M, Loiudice P, Passani A, et al. Long-term outcome of supraciliary gold micro shunt in refractory glaucoma. *Acta Ophthalmol*. 2022;100(3):e753–e759. doi:10.1111/aos.14989
22. Prausnitz MR, Noonan JS. Permeability of cornea, sclera, and conjunctiva: a literature analysis for drug delivery to the eye. *J Pharm Sci*. 1998;87(12):1479–1488. doi:10.1021/js9802594
23. Ahmed IIK, Sheybani A, De Francesco T, Samuelson TW. Corneal endothelial safety profile in minimally invasive glaucoma surgery. *J Cataract Refract Surg*. 2024;50(4):369–377. doi:10.1097/j.jcrs.0000000000001365
24. Radcliffe N. The case for standalone micro-invasive glaucoma surgery: rethinking the role of surgery in the glaucoma treatment paradigm. *Curr Opin Ophthalmol*. 2023;34(2):138–145. doi:10.1097/ICU.0000000000000927
25. Malvankar-Mehta MS, Iordanous Y, Chen YN, et al. iStent with phacoemulsification versus phacoemulsification alone for patients with glaucoma and cataract: a meta-analysis. *PLoS One*. 2015;10(7):e0131770. doi:10.1371/journal.pone.0131770
26. Samuelson TW, Sarkisian SR, Lubeck DM, et al.; iStent inject Study Group. Prospective, randomized, controlled pivotal trial of an Ab interno implanted trabecular micro-bypass in primary open-angle glaucoma and cataract: two-year results. *Ophthalmology*. 2019;126(6):811–821. doi:10.1016/j.ophtha.2019.03.006
27. Ahmed IIK, De Francesco T, Rhee D, et al. HORIZON investigators. Long-term outcomes from the HORIZON randomized trial for a schlemm's canal microstent in combination cataract and glaucoma surgery. *Ophthalmology*. 2022;129(7):742–751. doi:10.1016/j.ophtha.2022.02.021
28. Denis P, Hirneiß C, Durr GM, et al. Two-year outcomes of the MINiject drainage system for uncontrolled glaucoma from the STAR-I first-in-human trial. *Br J Ophthalmol*. 2022;106(1):65–70. doi:10.1136/bjophthalmol-2020-316888
29. Holmes DP, Clement CI, Nguyen V, et al. Comparative study of 2-year outcomes for Hydrus or iStent inject microinvasive glaucoma surgery implants with cataract surgery. *Clin Exp Ophthalmol*. 2022;50(3):303–311. doi:10.1111/ceo.14048
30. Carolan JA, Liu L, Alexeeff SE, Amsden LB, Shorstein NH, Herrinton LJ. Intraocular pressure reduction after phacoemulsification: a matched cohort study. *Ophthalmol Glaucoma*. 2021;4(3):277–285. doi:10.1016/j.ogla.2020.10.002

Clinical Ophthalmology

Dovepress

Publish your work in this journal

Clinical Ophthalmology is an international, peer-reviewed journal covering all subspecialties within ophthalmology. Key topics include: Optometry; Visual science; Pharmacology and drug therapy in eye diseases; Basic Sciences; Primary and Secondary eye care; Patient Safety and Quality of Care Improvements. This journal is indexed on PubMed Central and CAS, and is the official journal of The Society of Clinical Ophthalmology (SCO). The manuscript management system is completely online and includes a very quick and fair peer-review system, which is all easy to use. Visit <http://www.dovepress.com/testimonials.php> to read real quotes from published authors.

Submit your manuscript here: <https://www.dovepress.com/clinical-ophthalmology-journal>