

# Adjunctive Diagnosis of *Mycobacterium gordonae* Pneumonia by Metagenomic Next-Generation Sequencing in an Immunocompetent Patient: A Case Report and Literature Review

Shengqiao Shi<sup>1,\*</sup>, Wei Gai<sup>2,\*</sup>, Hui Huang<sup>1</sup>, Yafeng Zheng<sup>1b</sup>, Xiaojing Zhang<sup>2,3</sup>, Yuanrong Dai<sup>1</sup>, Chengyun Wu<sup>1</sup>

<sup>1</sup>Department of Respiratory Medicine, The 2nd Affiliated Hospital of Wenzhou Medical University, Wenzhou, Zhejiang, People's Republic of China;

<sup>2</sup>WillingMed Technology (Beijing) Co., Ltd, Beijing, People's Republic of China; <sup>3</sup>CAS Key Laboratory of Pathogenic Microbiology and Immunology, Institute of Microbiology, Chinese Academy of Sciences, Beijing, People's Republic of China

\*These authors contributed equally to this work

Correspondence: Chengyun Wu; Yuanrong Dai, Department of Respiratory Medicine, The 2nd Affiliated Hospital of Wenzhou Medical University, No. 109, College West Road, Wenzhou, Zhejiang, 325027, People's Republic of China, Email wcy857516126@126.com; daiyr@126.com

**Introduction:** *Mycobacterium gordonae* is a nonpathogenic pathogen commonly found in nature and is generally considered a contaminant in clinical practice. Although there have been few reported cases of infection, most of them are secondary to immunosuppression. This paper described a rare case of globular shadow in the chest of an immunocompetent male who was diagnosed with *M. gordonae* pulmonary disease. He went to the hospital with chest pains that had lasted for more than two weeks. The routine clinical pathogen detection failed to discover the cause of the infection. Although metagenomic next-generation sequencing (mNGS) of the lung tissue was negative, *M. gordonae* was detected in the background microorganism with only one read. Based on the pathological results, it was considered to be the causative pathogen. Two months of treatment with rifampicin, ethambutol, clarithromycin, and levofloxacin resulted in significant reduction and absorption of lung lesions. No abnormalities were detected in either lung one year later. The lack of positive culture and other conventional microbiological test results make this case is not a strictly confirmed case. This study also explored the clinical features and treatment options of 32 cases of *M. gordonae* pulmonary disease through a systematic review of the literature. Although there is no standard recommended treatment regimen for *M. gordonae* infection, but combination therapy with macrolides, rifampicin, and ethambutol has been proven effective.

**Conclusion:** This case highlights that when the clinical highly suspected of infection, mNGS can contribute to the early identification of non-tuberculous Mycobacterium (NTM) even with low reads, when clinical suspicion is high. Analyzing background microorganisms in sterile samples may help diagnose rare pathogens.

**Keywords:** *Mycobacterium gordonae*, globular shadow, pulmonary disease, nontuberculous mycobacterium, mNGS

## Introduction

*Mycobacterium gordonae* is a non-tuberculous Mycobacterium (NTM) that grows chronically and belongs to Runyon type II dark chromogenic bacteria.<sup>1</sup> It is widely found in natural environments such as water, soil, and unpasteurized milk. Although it is one of the least virulent NTM and generally non-pathogenic, it is more commonly found in hospital water supply systems. Nosocomial pseudoinfections have been reported, and the isolation and culture of this bacterium in laboratory specimens is generally considered to be contamination.<sup>2,3</sup>

Currently, the diagnosis of NTM is predominantly based on acid-fast stain (AFS) and culture.<sup>4</sup> The cell wall of NTM has a high lipid content, which makes it suitable for acid-fast staining. Nevertheless, the sensitivity of staining can be influenced by various factors, including pathogen abundance and sample processing methods. Moreover, clinical symptoms and acid-fast

bacilli (AFB) positive sputum smear or culture cannot accurately differentiate between *Mycobacterium tuberculosis* (MTB) infection, NTM infection, or NTM environmental contamination.<sup>5</sup> Culture continues to be one of the most sensitive methods for detecting NTM. However, problems such as low positive rate and long culture period cannot achieve early diagnosis.<sup>4</sup> T-SPOT can distinguish PTB from NTM-PD.<sup>6–9</sup> However, in clinical practice, the positive rate of T-SPOT in patients with NTM-PD is close to 30%, especially in countries with high TB burden, and the ability of T-SPOT to distinguish patients with NTM-PD from patients with PTB is limited.<sup>9</sup> GeneXpert *Mycobacterium tuberculosis*/rifampicin (MTB/RIF) is a conceptually helpful tool for establishing TB disease. Current research suggests that NTM will not cause false positives in GeneXpert, therefore, the presence of NTM is indicated by negative GeneXpert and positive smear microscopy results.<sup>10,11</sup> T-spot combined with GeneXpert can improve the diagnostic accuracy of NTM, but its application value in *M. gordonae* still needs to be confirmed by studies with larger sample sizes. Thus, the development of metagenomic next-generation sequencing (mNGS) technology makes the early diagnosis of NTM possible. However, most NTM are parasites, and only a small number of them are pathogenic to humans and are conditionally pathogenic bacteria.<sup>12,13</sup> Furthermore, for mycobacteria that are difficult to break and are usually considered contaminants, low read count detection may be classified as background bacteria. Therefore, when an uncommon pathogenic NTM with a low number of reads was detected, the determination of whether the NTM is pathogenic needs to be made comprehensively based on the patient's clinical manifestations and imaging evidence.

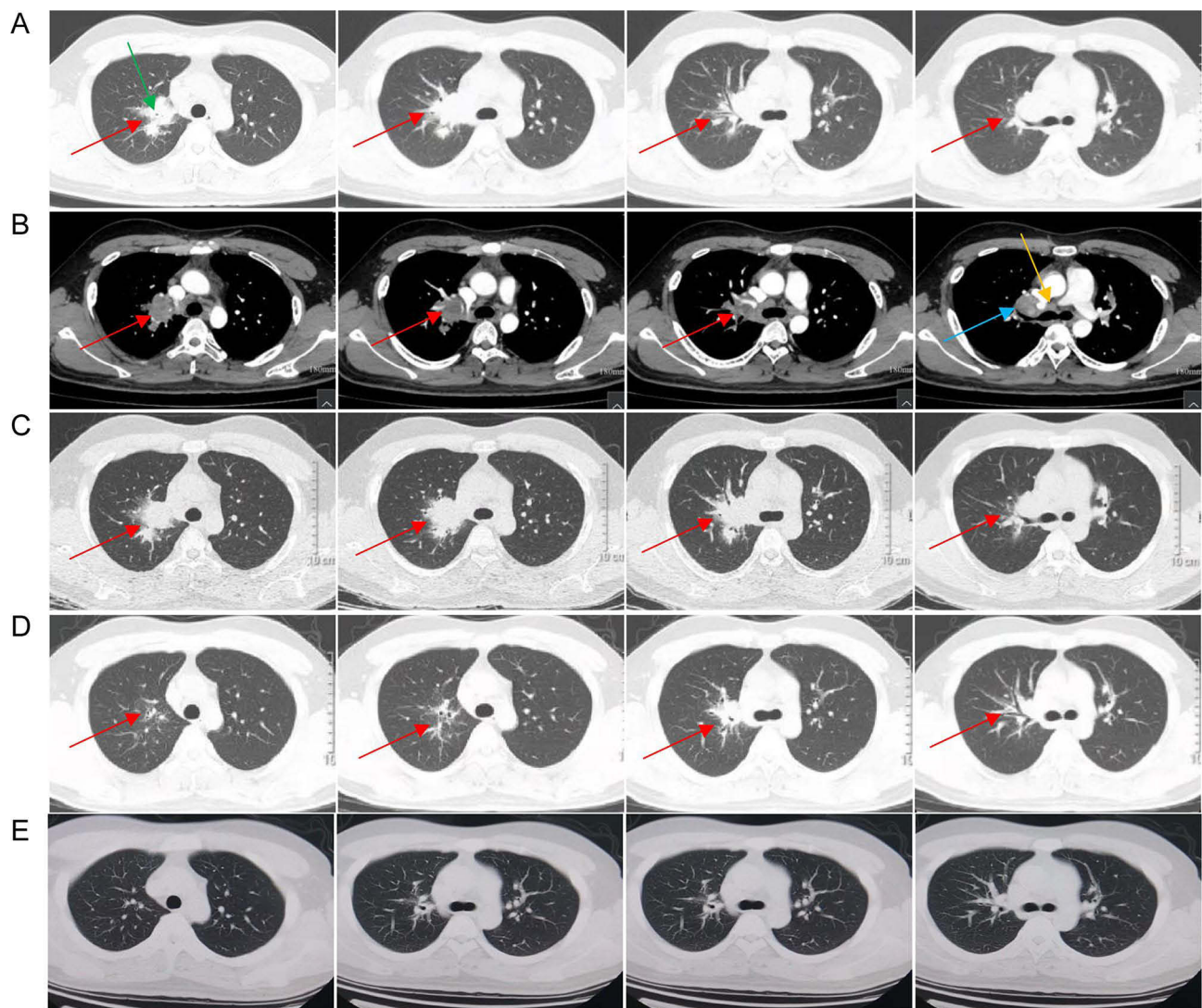
This paper presents a case study of a young male patient who was diagnosed with *M. gordonae* lung disease and has an immunocompetent status. The diagnosis was determined by examining for background bacteria when the mNGS results in lung tissue were negative. The patient had a good prognosis after treatment with rifampicin, ethambutol, clarithromycin, and levofloxacin. The case study highlights the clinical importance of mNGS in the early diagnosis of NTM, especially these which are generally considered as non-pathogenic and cannot be identified by conventional microbiological tests. Additionally, it is valuable to detect background bacteria using mNGS in sterile samples when infection is highly suspected clinically, but the cause is unknown, regardless of whether the patient is immunocompromised.

## Case Presentation

On April 27, 2021, a 21-year-old male patient presented to the outpatient Department of Respiratory Medicine at the Second Affiliated Hospital of Wenzhou Medical University with complaints of chest pain persisting for over two weeks. The patient described experiencing severe pain behind the sternum during inspiration, without any radiating pain, fever, cough, expectoration, chest tightness, hemoptysis, or weight loss. On April 26, the patient had sought care at Wenzhou Binhai Hospital. A chest-enhanced Computed Tomography (CT) scan revealed a lumpy high-density shadow in the upper right lung, and limited bronchial stenosis in the apical segment of the right upper lobe of the lung (Figure 1A), as well as multiple enlarged lymph nodes in the right hilum and mediastinum (Figure 1B). The patient was employed as a radiation technician in a hospital and reported being in good health. He denied having a history of chronic diseases such as hypertension and diabetes mellitus or any diseases affecting vital organs including heart disease, brain disorders, liver or kidneys problems. He also denied having had infectious diseases such as tuberculosis or any history of surgery, trauma, or blood transfusion. The patient declined hospitalization for further examinations.

On April 30, bronchoscopy was performed, which revealed purulent secretion at the opening of the right main bronchus, and occlusion of the bronchial opening of the right upper apical segment. The bronchoalveolar-lavage fluid (BALF) underwent AFS, bacterial and mycobacterial cultures, cryptococcal antigens, and GeneXpert MTB/RIF analysis, all of which yielded negative results. Additionally, brushing and lavage of the right upper apical segment of the lung did not reveal any neoplastic cells. The BALF's cell counts showed 66% lymphocytes, 6% neutrophils, 18% macrophages, and 10% ciliated columnar epithelial cells. The patient returned to Wenzhou Binhai Hospital for treatment with cefoperazone sulbactam needle (3 g, q12h) via intravenous drip for one week, and oral cefixime capsule (0.2 g, bid) for two weeks as part of an anti-infection regimen.

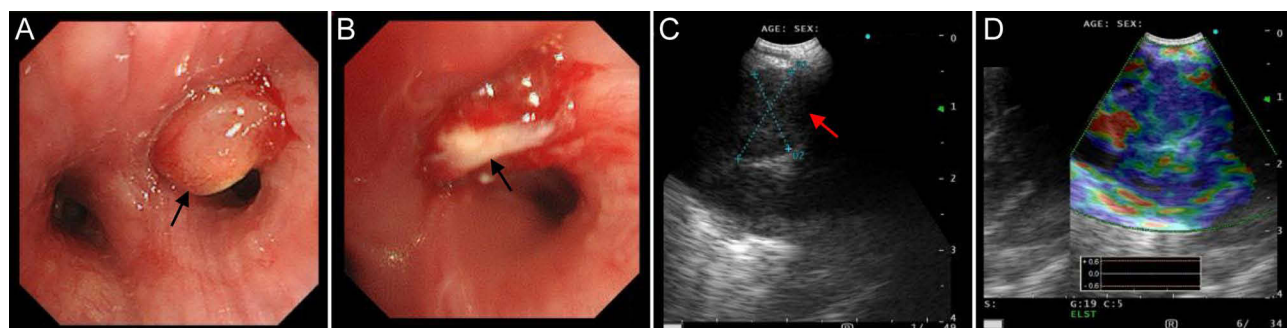
On June 6, the chest CT re-examination at our hospital revealed a slight progression of the lesion in the right upper lobe of the lung. Subsequently, the patient was admitted to the respiratory ward of our hospital on June 8. The initial diagnosis considered a number of potential causes for the right lung mass, including lung cancer, tuberculosis, sarcoidosis, and enlarged mediastinal lymph nodes. Upon admission, the physical examination revealed a heart rate of 102 beats/min, breathing rate of 18 beats/min, blood pressure of 128/80 mmHg, and a body temperature of 36.7°C. The patient's superficial lymph nodes were



**Figure 1** CT findings of the patient's lungs at different times. **(A)** On April 27, CT images of lung window showed a lumpy high-density shadow in the upper right lung (red arrow), limited bronchial stenosis in the apical segment of the right upper lobe of the lung (green arrow). **(B)** On April 27, CT images of mediastinal window showed multiple enlarged lymph nodes in the right hilum (blue arrow) and mediastinum (yellow arrow). Red arrow presents the lumpy high-density shadow in the upper right lung. **(C)** On August 10, a mass-like lesion (red arrow) in the upper lobe of the right lung was enlarged. **(D)** On October 27, the mass-like lesion (red arrow) in the upper lobe of the right lung was significantly absorbed and reduced in size. **(E)** On March 24, 2023, the follow-up CT results suggested the mass-like lesion in the upper lobe of the right lung was completely absorbed.

not enlarged, and his breathing was stable. Both lungs exhibited clear, with symmetrical breath sounds and no dry or wet rales. The heart rate was regular, with no murmur in the heart valve area, and the abdomen was flat and soft. There was no edema in either lower limb, and the pathological findings were negative. Laboratory tests revealed normal levels of C-reactive protein (CRP) at 2.64 mg/L, white blood cell count at  $5.98 \times 10^9/L$ , neutrophil ratio at 0.56, hemoglobin level at 146 g/L, and platelet count at  $237 \times 10^9/L$ . The test results for purified protein derivative (PPD), T-spot, multiple-sputum smears for AFB, blood galactomannan (GM), and cryptococcus antigen were all negative. Liver and kidney function, bleeding and coagulation function, lung tumor markers, autoimmune and anti-neutrophil cytoplasmic antibody (ANCA) series, and lymphocyte subsets were all within normal ranges. No significant abnormalities were detected in lung function, superficial lymph node B ultrasound, echocardiography, and electrocardiogram. On June 10, a repeat bronchoscopy performed revealed a bronchial neoplasm in the apical segment of the upper lobe of the right lung (high-frequency electrocoil ligation) (Figure 2A and B), enlarged lymph nodes in group 10R, and endobronchial ultrasound-guided transbronchial needle aspiration (EBUS-TBNA) was performed three times (Figure 2C and D). Postoperative pathology results showed that the biopsy of the

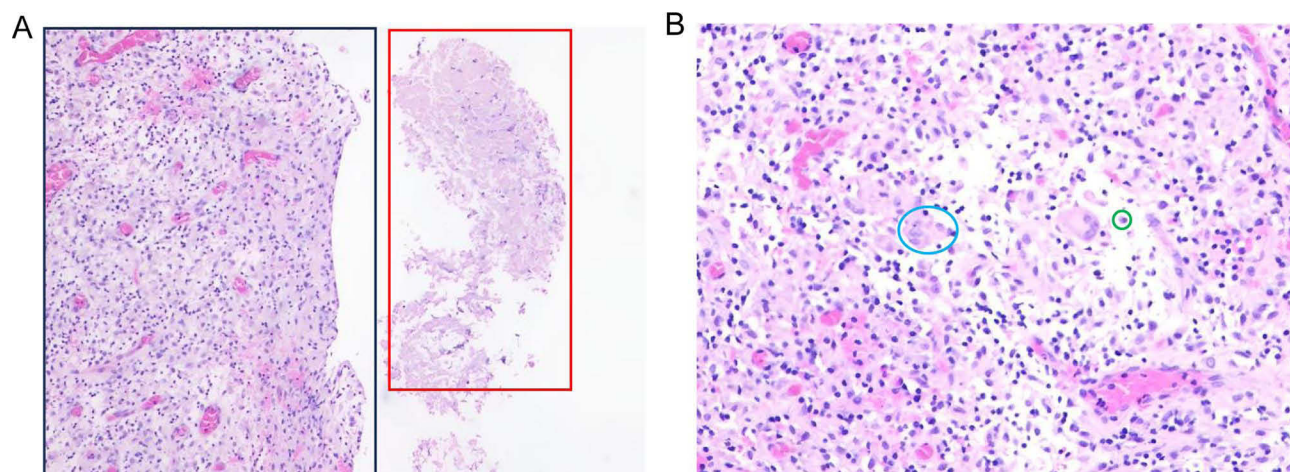




**Figure 2** Bronchoscopy findings on 10 June. (A and B) a bronchial neoplasm (black arrow) in the apical segment of the upper lobe of the right lung. (C and D) enlarged lymph nodes (red arrow) in group 10R.

neoplastic bronchial opening in the right upper lobe of the lung showed exudative necrosis around the inflammatory granulation tissue. The neoplastic biopsy of the right upper apical bronchus showed columnar epithelial cells and a small amount of necrotic-like material on smear, but no malignant tumor cells were found. The smear of the 10R group lymph node showed lymphocytes, epithelioid cells and necrosis, indicating the possibility of tuberculosis. However, the results of AFS, Grocott methenamine silver (GMS) stain, and Periodic acid-Schiff (PAS) stain, BALF GeneXpert MTB/RIF, and mycobacteria culture were negative. To identify possible infectious agents, the patient's BALF was sent for mNGS, but no pathogens were detected. The patient was discharged. On July 10, the patient came to our outpatient clinic for further consultation. After discussion, the patient decided to receive diagnostic treatment for tuberculosis. A four-drug oral regimen of isoniazid (0.3 g, qd), rifampin (0.45 g, qd), ethambutol (0.75 g, qd), and pyrazinamide (0.5 g, tid) was administered between July 10 and August 10. On August 10, chest CT scan showed that an enlarged lesion in the right upper lobe (Figure 1C).

On August 24, the patient was readmitted and underwent a CT-guided percutaneous lung needle biopsy. The biopsy revealed granulomatous inflammation with visible necrosis (Figure 3). Immunohistochemistry showed positive CD68, while the results of AFS and GMS were negative. The biopsy tissue samples were sent for mNGS. The sampling operation was carried out in a sterile environment, and the sterile requirements were strictly followed throughout the process. In this case, the puncture needle completely entered the lesion, and all the tissues taken were pathological tissues. The mNGS procedure was as follows: Tissue samples ( $\geq 3 \times 3 \times 3$  mm) were collected in special sample tube (with liquid) and transported with dry ice seal in 48 h after collection. DNA was extracted using PathoXtract® Basic Pathogen Nucleic Acid Kit (WYXM03211S, WillingMed Corp, Beijing, China) according to the manufacturer's protocol. Genomic DNA libraries were constructed using



**Figure 3** Histopathological findings of a percutaneous lung aspiration biopsy performed. (A) Coagulative necrosis (red box) and granulomatous tissue hyperplasia (black box). Scale bars, 200  $\mu$ m. (B) Massive lymphocytic plasma cell infiltration with foci of hyperplastic granuloma. Multinucleated giant cells: blue circle; plasma cells: green circle. Scale bars, 50  $\mu$ m.

**Table 1** List of Background Microorganisms Detected by Lung Tissue mNGS

| Species                            | Number of Reads | Length of Reads |
|------------------------------------|-----------------|-----------------|
| <i>Mycobacterium gordonae</i>      | 1               | 75              |
| <i>Aspergillus sydowii</i>         | 3               | 300             |
| <i>Golovinomyces cichoracearum</i> | 1               | 75              |
| <i>Pseudomonas putida</i>          | 3               | 299             |
| <i>Acinetobacter johnsonii</i>     | 1               | 150             |
| <i>Acinetobacter guillouiae</i>    | 1               | 74              |
| <i>Sphingobium limneticum</i>      | 1               | 150             |
| <i>Marinobacter fuscus</i>         | 1               | 75              |
| <i>Marinobacter vinifirmus</i>     | 1               | 75              |
| <i>Delftia tsuruhatensis</i>       | 1               | 150             |
| <i>Novosphingobium panipatense</i> | 1               | 150             |
| <i>Staphylococcus simulans</i>     | 1               | 75              |
| <i>Shewanella oneidensis</i>       | 1               | 75              |
| <i>Enterococcus casseliflavus</i>  | 1               | 75              |
| <i>Kocuria rhizophila</i>          | 1               | 74              |
| <i>Pedobacter panaciterrae</i>     | 1               | 74              |
| <i>Thauera phenylacetica</i>       | 1               | 74              |
| <i>Lactococcus plantarum</i>       | 1               | 75              |
| <i>Xanthomonas campestris</i>      | 1               | 75              |
| <i>Paracoccus aeridis</i>          | 1               | 75              |

the Illumina® DNA Prep, (M) Tagmentation (20018705, Illumina) according to the manufacturer's protocol. Libraries were sequenced on the Illumina NextSeq™ 550Dx platform with a 75 bp single-end sequencing kit. A negative control sample (containing nuclease-free water without DNA template) was processed and sequenced in parallel with experimental samples to exclude environmental and laboratory contaminants. Raw FASTQ-format data using Fastq software for quality control and evaluation. High-quality sequencing reads were aligned against the human reference genome GRCh37 (hg19) using Bowtie2 v2.4.3 to remove human host sequences. The remaining sequences were then compared against the NCBI GenBank database using Kraken2 v2.1.0 to annotate pathogen genomes and identify pathogens present in the samples. Pathogens were identified based on the specific reads per ten million (RPTM value). For virus detection, an RPTM value  $\geq 3$  was used as the threshold, while bacteria and fungi required an RPTM  $\geq 20$  for positive identification.<sup>14</sup> No positive pathogenic bacteria were detected. The testing institution was contacted to verify the background bacteria data. The results revealed the presence of several pathogens, including *Mycobacterium gordonae* (1 reads), *Aspergillus sydowii*, *Pseudomonas putida*, *Acinetobacter Johnsonii*, *Lactococcus plantarum*, *Xanthomonas campestris*, and *Kocuria rhizophila*, etc (Table 1). Based on the pathological results of multiple biopsies, it is suggested that NTM pulmonary disease caused by *M. gordonae* should be considered. Based on the previously reported treatment methods (Supplementary Table 1), the patient received oral rifampicin (0.45 g, qd), ethambutol (0.75 g, qd), clarithromycin (0.5 g, qd), and levofloxacin (0.5 g, qd) from August 29 to October 27. On October 27, the patient's chest CT showed a significant reduction in the lesion located in the right upper lobe of the lung (Figure 1D). The final diagnosis was *M. gordonae* pulmonary disease. The patient discontinued oral medication after one year. Currently, regular chest CT examinations show no abnormalities in either lung (Figure 1E).

## Discussion and Conclusion

NTM are mycobacteria other than MTB and *M. leprae*. Currently, more than 200 species have been discovered,<sup>5</sup> and only a few are common pathogenic bacteria. *M. gordonae* was first described in 1962.<sup>15</sup> Clinically, it is generally considered a contaminating bacterium and rarely causes human infections. Nevertheless, there are also reports of infections caused by *M. gordonae*, infection sites including the lung, liver, kidney, meninges, cornea, skin, soft tissue, lymphatic tissue, bone and joint, and artificial heart valves, and among them, the lungs are one of the most commonly affected organs.<sup>16</sup>

This article summarizes 32 cases of *M. gordonae* lung disease that have been published so far ([Supplementary Table 1](#)). It was found that the infection occurred in different genders and ages (18 to 76 years old). Most patients had underlying structural lung diseases, such as old tuberculosis, chronic obstructive pulmonary disease, and bronchiectasis, etc. Additionally, individuals with AIDS, malignant tumors, connective tissue diseases, diabetes, long-term use of steroid hormones, organ transplantation, smoking, and alcohol abuse may be susceptible to *M. gordonae* ([Supplementary Table 1](#)). Opportunistic infections often occur in immunosuppressed patients. However, *M. gordonae* can also infect immunocompetent individuals, including the case presented here and three cases reported previously.<sup>17–19</sup> These patients had no underlying diseases or risk factors for infection, and the infection was localized in the lungs and did not spread. The clinical presentation of *M. gordonae* lung disease is similar to those of general NTM disease and tuberculosis patients, including local lung damage, systemic toxic symptoms and manifestations of underlying disease. Most patients presented with cough, expectoration, fever, night sweats, hemoptysis, dyspnea, and weight loss. If the disease progresses slowly, some patients may be asymptomatic.<sup>19</sup> In this case, the patient only experienced transient chest pain, and the clinical symptoms were atypical. The chest CT scans findings of patients with *M. gordonae* pulmonary disease are mainly multiple cavities, nodules, bronchiectasis, fibrous cords, and small patchy consolidation, which are more common in the upper lobes of both lungs, consistent with the imaging characteristics of NTM disease ([Supplementary Table 1](#)). However, the case presented in this study was a rare right hilar mass, and no similar results have been seen so far.

*Mycobacterium gordonae* is generally non-pathogenic. When the bacterium is cultured from respiratory tract samples, it should be considered with caution. Therefore, in addition to clinical and imaging features, the diagnostic criteria should meet one of the following: 1) At least two separate sputum cultures are positive, or 2) At least one culture of BALF is positive, 3) Transbronchial or other lung biopsy has mycobacterial histological features, such as granulomatous inflammation or acid-fast bacilli, and NTM culture is positive.<sup>4</sup> Currently, the diagnosis of most cases mainly depends on culture results, but the long time required for culture makes it difficult to diagnose the pathogen in the early stage. mNGS is an emerging molecular biological technique that is suitable for diagnosing and differentiating suspected NTM diseases with negative etiology.<sup>20</sup> It was included in the diagnostic criteria of non-tuberculous mycobacterial pulmonary disease (NTM-PD) for the first time in the 2020 Guidelines for the Diagnosis and Treatment of NTM-PD in China.<sup>21</sup> The microbial sequences detected by mNGS may come from pathogenic microorganisms or normal flora. In the analysis of mNGS test results, common bacteria colonizing the skin and respiratory tract are classified as normal lung microbiota when interpreting the mNGS reports.<sup>22–25</sup> NTM can colonize the respiratory tract, and their pathogenicity varies depending on the type of NTM. For instance, *M. gordonae* is less likely to cause infection, with most cases being attributed to contamination during sample collection or detection.<sup>12,13</sup> In this study, the patient presented with atypical clinical manifestations and imaging findings, acid-fast staining and culture showed negative result, mNGS had *M. gordonae* detected, the microscopic manifestations of the patient's lung puncture tissue showed thorough coagulative necrosis, combined with immunohistochemistry, the diagnosis of mycobacteriosis was more inclined. This case was diagnosed without the gold standard of culture, this is because traditional microbiology is based on in vitro isolation and culture, but in fact many pathogenic microorganisms in the environment or in the human body are difficult to culture and may only be discovered through new technologies such as NGS. The shift from traditional culture to molecular biology diagnosis requires a change in the thinking of clinicians and microbiologists. We believe that when traditional methods cannot be clear, NGS can be used as a good supplement, but it must be combined with clinical practice and make a diagnosis carefully. It was included in the diagnostic criteria of non-tuberculous mycobacterial pulmonary disease (NTM-PD) for the first time in the 2020 Guidelines for the Diagnosis and Treatment of NTM-PD in China.<sup>21</sup> According to the result of a comprehensive analysis by clinical experts based on the patient's clinical symptoms, laboratory test results, imaging results, and mNGS results, the diagnose of NTM infection is suspected according to the 2020 Guidelines for the Diagnosis and Treatment of NTM-PD in China. Thus, *M. gordonae* was considered as a responsible pathogen. Ineffective anti-tuberculosis treatment increases the possibility of NTM infection. Finally, the validity of the final diagnosis provides the most important reference for determining the responsible pathogen. Currently, there is still a lack of reports on the extraction of pathogens from background bacteria, this study can provide clinicians with broader ideas for the diagnosis of diseases. *M. gordonae* lung disease is very rare. This case may provide some insights into the clinical features, diagnostic methods, and treatment methods of *M. gordonae* disease.

The pathology of mycobacteriosis and aspergillosis can both present as infectious granulomatous lesions. Because the results of multiple clinical etiological tests were negative, pathological tests were performed on tissue specimens. We have communicated with the pathologists of our hospital many times and sent the pathological specimens to the Guangzhou Institute of Respiratory Diseases for consultation. Although the microscopic manifestations of the patient's lung puncture tissue pathological specimens did not reach the level of caseous necrosis, the coagulative necrosis was relatively thorough, and no fungal bacterial structure was detected. Combined with immunohistochemistry, the diagnosis of mycobacteriosis was more inclined. The mNGS results of tissue samples were negative. It is generally agreed that if the mNGS result is negative, but there is still a strong suspicion of infectious disease based on clinical characteristics, it is recommended to analyze the background microorganisms, raw data list, or other pathogenic microorganism test results in the mNGS report.<sup>26</sup> In this study, during the sampling, transportation, we took care to avoid the influence of human DNA. During nucleic acid extraction processes, saponin is added to the sample to lyse human cells, and DNase is used to digest free human DNA. Hasan et al compared the efficiency of saponin, Tween-20, Triton X-100, and Chaps Cell Extract 158 Buffer (New England Biolabs) for selective lysis of human cells and used Turbo DNase for post-lysis treatment. Saponin at a concentration of 0.025% was the most effective in both cerebrospinal fluid (CSF) and nasopharyngeal aspirate (NPA) specimens, which increased approximately 30- to 100-fold of pathogen DNA to human DNA ratios. Furthermore, there was a significant enrichment of ~40- and ~170-fold compared to the unprocessed specimens in the CSF and NPA specimens, respectively. A nanopore sequencing study presented an optimized saponin-based host DNA depletion method for bacterial Lower respiratory tract infections diagnosis, which removed up to 99.99% of the human DNA from respiratory samples (Charalampous et al, 2019). The above studies show that the use of saponins to remove host DNA is very effective. During the sequencing, negative control was used to exclude environmental and laboratory contaminants. Furthermore, previous studies also demonstrated that although the sensitivity of mNGS may be affected by the multiple human gene sequences in tissue samples obtained in a sterile environment, the specificity will increase.<sup>27</sup> Based on the above premise, the *M. gordonae* identified in the sequencing background data was strongly considered to be the responsible pathogen, despite its low reads' numbers (1 read). The patient's lung lesions were completely absorbed with targeted therapy, confirmed the clinical diagnosis. The above studies suggest that mNGS plays an important role in the diagnosis of NTM. When NTM infection is suspected but mNGS results of the sterile sample is negative, the pathogenic of rare, non-pathogenic, and thought-to-be-contaminated NTM should be considered in combination with the patient's symptoms and pathological characteristics, so as to accurately determine the cause of infection as early as possible. There is currently no standard treatment for *M. gordonae* pulmonary disease, and clinical data are limited. In vitro drug susceptibility test indicate that it is sensitive to drugs such as rifampicin, ethambutol, macrolides, fluoroquinolones, linezolid, amikacin, and is resistant to isoniazid and pyrazinamide.<sup>4,18,28</sup> After targeted medication, most cases have a good prognosis ([Supplementary Table 1](#)). In this study, the patient was initially treated with isoniazid, rifampicin, ethambutol, and pyrazinamide quadruple therapy for more than 2 months without effect, after switching to rifampicin, ethambutol, clarithromycin, and levofloxacin, the lesions in the lungs were completely absorbed. The treatment was maintained for about 1 year and the drug was discontinued without recurrence. This result also ruled out the possibility of *Aspergillus* infection, although it has 3 reads detected, because the drugs are ineffective against *Aspergillus sydowii*.

In conclusion, *M. gordonae* can be a pathogen even in immunocompetent patients. Although it is often considered to be clinically contaminated, we believe that when *M. gordonae* is isolated in laboratory sample, caution should be used to judge colonization or infection in specific condition, regardless of the patient's immune status. mNGS is of great value for the diagnosis of thick-walled microorganisms such as NTM. Even if the number of reads detected is low, it is necessary to consider the possibility of it as a pathogenic pathogen in combination with the patient's clinical characteristics. For negative mNGS results, the screening of background microorganisms cannot be ignored, especially for sterile samples.

## Data Sharing Statement

The raw data supporting the conclusions of this article will be made available by the authors, without undue reservation. The raw data from the mNGS sequencing was submitted to the public database NCBI SRA database with a BioProject ID of PRJNA1185004.



## Ethics Statements

The study was conducted in accordance with the Declaration of Helsinki. All procedures performed in the study involving human participants were in conformity to the ethical standards of the Ethics Committee of the 2nd Affiliated Hospital of Wenzhou Medical University. Ethics approval was not required by the local ethics committee, as this is a case report with anonymized details. Written informed consent for publication of the clinical details and clinical images was obtained from the patient.

## Funding

This study had no funding.

## Disclosure

The authors report no conflicts of interest in this work.

## References

1. Lessnau K-D, Milanese S, Talavera W. Mycobacterium gordonae: a Treatable Disease in HIV-Positive Patients. *Chest*. 1993;104(6):1779–1785. doi:10.1378/chest.104.6.1779
2. Eckburg PB, Buadu EO, Stark P, Sarinas PSA, Chitkara RK, Kuschner WG. Clinical and Chest Radiographic Findings Among Persons With Sputum Culture Positive for Mycobacterium gordonae. *Chest*. 2000;117(1):96–102. doi:10.1378/chest.117.1.96
3. Jakopovic M, Zlojtro I, Obrovac M, et al. Nosocomial pseudo-outbreak of Mycobacterium gordonae associated with a hospital's water supply contamination: a case series of 135 patients. *J Water Health*. 2015;13(1):125–130. doi:10.2166/wh.2014.061
4. Lange C, Böttger EC, Cambau E, et al. Consensus management recommendations for less common non-tuberculous mycobacterial pulmonary diseases. *Lancet Infect Dis*. 2022;22(7):e178–e190. doi:10.1016/s1473-3099(21)00586-7
5. Pennington KM, Vu A, Challener D, et al. Approach to the diagnosis and treatment of non-tuberculous mycobacterial disease. *J Clin Tuberculosis Other Mycobacterial Dis*. 2021;24:100244. doi:10.1016/j.jctube.2021.100244
6. Ji S, Xu W, Sun J, Shi Y, Pan X. Retrospective analysis of patients with non-tuberculous mycobacteria from a primary hospital in Southeast China. *Sci Rep*. 2020;10(1):1060. doi:10.1038/s41598-020-58105-4
7. Jia H, Pan L, Wang G, et al. Assessment of Interferon-Gamma Release Assay in Patients with Non-Tuberculous Mycobacteria Pulmonary Disease. *Clin Lab*. 2019;65(10). doi:10.7754/Clin.Lab.2019.181247
8. Wang MS, Wang JL, Wang XF. The performance of interferon-gamma release assay in nontuberculous mycobacterial diseases: a retrospective study in China. *BMC Pulm Med*. 2016;16(1):163. doi:10.1186/s12890-016-0320-3
9. Yang C, Luo X, Fan L, Sha W, Xiao H, Cui H. Performance of Interferon-Gamma Release Assays in the Diagnosis of Nontuberculous Mycobacterial Diseases-A Retrospective Survey From 2011 to 2019. *Front Cell Infect Microbiol*. 2020;10:571230. doi:10.3389/fcimb.2020.571230
10. Kong L, Xie B, Liu Q, et al. Application of acid-fast staining combined with GeneXpert MTB/RIF in the diagnosis of non-tuberculous mycobacteria pulmonary disease. *Inter J Infect Dis*. 2021;104:711–717. doi:10.1016/j.ijid.2020.12.091
11. Arora D, Dhanashree B. Utility of smear microscopy and GeneXpert for the detection of Mycobacterium tuberculosis in clinical samples. *Germs*. 2020;10(2):81–87. doi:10.18683/germs.2020.1188
12. Martín-Casabona N, Bahrmand AR, Bennedsen J, et al. Non-tuberculous mycobacteria: patterns of isolation. A multi-country retrospective survey. *Int J Tubercul Lung Dis*. 2004;8(10):1186–1193.
13. Prevots DR, Marras TK. Epidemiology of Human Pulmonary Infection with Nontuberculous Mycobacteria. *Clinics Chest Med*. 2015;36(1):13–34. doi:10.1016/j.ccm.2014.10.002
14. Chen H, Zheng Y, Zhang X, et al. Clinical evaluation of cell-free and cellular metagenomic next-generation sequencing of infected body fluids. *J Adv Res*. 2023;55:119–129. doi:10.1016/j.jare.2023.02.018
15. BOJALIL LF, CERBON J, T A. Adansonian classification of mycobacteria. *J Gen Microbiol*. 1962;28(2):333–346. doi:10.1099/00221287-28-2-333
16. Chang H-Y, Tsai W-C, Lee T-F, Sheng W-H. Mycobacterium gordonae infection in immunocompromised and immunocompetent hosts: a series of seven cases and literature review. *J Formos Med Assoc*. 2021;120(1):524–532. doi:10.1016/j.jfma.2020.06.029
17. Resch B, Eber E, Beitzke A, Bauer C, Z M. Pulmonary infection due to Mycobacterium gordonae in an adolescent immunocompetent patient. *Respiration*. 1997;64(4):300–303. doi:10.1159/000196691
18. Mazumder SA, Hicks A, N J. Mycobacterium gordonae pulmonary infection in an immunocompetent adult. *N Am J Med Sci*. 2010;2(4):205–207.
19. Asija A, Prasad A, E E. Disseminated Mycobacterium gordonae infection in an immunocompetent host. *Am J Ther*. 2011;18(3):e75–7. doi:10.1097/MJT.0b013e3181e32e55
20. Sequencing CEGoh-t. Expert consensus on the application of high-throughput sequencing technology in the diagnosis of mycobacteriosis. *Chin J Infect Dis*. 2023;2023(03):175–182. doi:10.3760/cma.j.cn311365-20221203-00492
21. Society of Tuberculosis CMA. Guidelines for diagnosis and treatment of nontuberculous mycobacterial disease (2020 edition). *Chin J Tubercul Respiratory*. 2020;2020(11):918–946. doi:10.3760/cma.j.cn112147-20200508-00570.
22. Chen H, Yin Y, Gao H, et al. Clinical Utility of In-house Metagenomic Next-generation Sequencing for the Diagnosis of Lower Respiratory Tract Infections and Analysis of the Host Immune Response. *Clin Infect Dis*. 2020;71(Suppl 4):S416–S426. doi:10.1093/cid/ciaa1516
23. Xie G, Zhao B, Wang X, et al. Exploring the Clinical Utility of Metagenomic Next-Generation Sequencing in the Diagnosis of Pulmonary Infection. *Infect Dis Ther*. 2021;10(3):1419–1435. doi:10.1007/s40121-021-00476-w



24. Shi Y, Peng JM, Qin HY, Du B. Metagenomic next-generation sequencing: a promising tool for diagnosis and treatment of suspected pneumonia in rheumatic patients with acute respiratory failure: retrospective cohort study. *Front Cell Infect Microbiol*. 2022;12:941930. doi:10.3389/fcimb.2022.941930
25. Tan Y, Chen Z, Zeng Z, et al. Microbiomes Detected by Bronchoalveolar Lavage Fluid Metagenomic Next-Generation Sequencing among HIV-Infected and Uninfected Patients with Pulmonary Infection. *Microbiol Spectr*. 2023;11(4):e0000523. doi:10.1128/spectrum.00005-23
26. Society CT. Expert consensus on clinical interpretation pathway of metagenomic next-generation sequencing reports of lower respiratory tract infection. *Chin J Tubercul Respiratory*. 2023;46(4):322–335. doi:10.3760/cma.j.cn112147-20220701-00553
27. Chiu CY, Miller SA. Clinical metagenomics. *Nat Rev Genet*. 2019;20(6):341–355. doi:10.1038/s41576-019-0113-7
28. Bagarazzi ML, Watson B, Kim IK, Hogarty M, KL M. Pulmonary Mycobacterium gordonae infection in a two-year-old child: case report. *Clin Infect Dis*. 1996;22(6):1124–1125. doi:10.1093/clinids/22.6.1124

## Infection and Drug Resistance

Dovepress

### Publish your work in this journal

Infection and Drug Resistance is an international, peer-reviewed open-access journal that focuses on the optimal treatment of infection (bacterial, fungal and viral) and the development and institution of preventive strategies to minimize the development and spread of resistance. The journal is specifically concerned with the epidemiology of antibiotic resistance and the mechanisms of resistance development and diffusion in both hospitals and the community. The manuscript management system is completely online and includes a very quick and fair peer-review system, which is all easy to use. Visit <http://www.dovepress.com/testimonials.php> to read real quotes from published authors.

Submit your manuscript here: <https://www.dovepress.com/infection-and-drug-resistance-journal>