

A Lumbar Drug-Resistant Tuberculosis: A Case Report and Review of Literature

Tao Li^{1,2}, Shaohua Liu^{1,2}

¹Department of Spine Surgery and Orthopaedics, Xiangya Hospital, Central South University, Changsha, 410008, People's Republic of China;

²National Clinical Research Center for Geriatric Disorders, Xiangya Hospital, Central South University, Changsha, 410008, People's Republic of China

Correspondence: Shaohua Liu, Department of Spine Surgery and Orthopaedics, Xiangya Hospital, Central South University, Changsha, 410008, People's Republic of China, Email liushaohua@csu.edu.cn

Introduction: Tuberculosis is prevalent in high-burden countries. However, spinal multi-drug resistant tuberculosis (MDR-TB) in patients with normal immune function is a disease that is prone to misdiagnosis and even delayed diagnosis. Recently, we successfully treated one such patient.

Case Presentation: A 46-year-old male patients with lower back pain associated with recurrent fever 2 months before admission. The patient was misdiagnosed as a suppurative spinal infection and failed to respond to treatment for 2 months. The muscle strength of both lower limbs decreased progressively. We performed two operations to clear the lesion and decompress the spinal canal, during which we found a fish-like inflammatory tissue mimicking a suppurative infection. Finally, the patient was diagnosed with lumbar MDR-TB by culture, Xpert MTB/RIF and metagenomic next-generation sequencing (mNGS). The second-line anti-tuberculosis treatment (ATT) is cycloserine + para-aminosalicylic acid + ethambutol + levofloxacin + linezolid. Finally, the patient's symptoms were relieved and the muscle strength of both lower limbs recovered.

Conclusion: This case prompt MDR-TB of the spine is not a typical clinical symptoms and imaging examination is the lack of specificity, when for the diagnosis of patients with spinal bone destruction unclear or treatment is invalid, can diagnostic anti-tuberculosis treatment. For patients with spinal instability or spinal canal occupying, early surgical removal of lesions, tissue culture, Xpert MTB/RIF and mNGS to identify pathogens and drug resistance, timely diagnosis and treatment can maximize the prognosis of spinal MDR-TB.

Keywords: multi-drug resistant tuberculosis (MDR-TB), antituberculosis treatment(ATT), metagenomic next-generation sequencing (mNGS), Xpert MTB/RIF

Introduction

Tuberculosis is prevalent in high-burden countries. In 2022, an estimated 10.6 million people developed tuberculosis, and 1.3 million died from the disease. About 410,000 new cases of multi-drug resistant or rifampicin-resistant tuberculosis (MDR/RR-TB) were estimated to occur in 2022. While all of these would have been eligible for a second-line tuberculosis treatment regimen, only 175,650 enrolments on treatment were reported by countries in the same year.¹ Notably, only one-third of patients with MDR/RR-TB were detected, and late diagnosis meant higher morbidity.² Spinal tuberculosis is a disease caused by infection of the spine with *Mycobacterium tuberculosis*. In general, patients will be correctly diagnosed and receive standardized anti-tuberculosis treatment (ATT). However, there are very few patients with spinal tuberculosis who have atypical medical history and even develop to multi-drug resistant tuberculosis (MDR-TB), so they are easily missed and misdiagnosed, resulting in very difficult diagnosis and treatment.^{3,4} Spinal MDR-TB with normal immune function is a disease that is prone to misdiagnosis and even delayed diagnosis.⁵ This article describes the misdiagnosis and treatment of a case of lumbar MDR-TB.

Case Presentation

A 46-year-old man was admitted to the hospital with low back pain and fever for more than 2 months. Two months ago (June 27, 2022), he suddenly developed upper lumbar pain, accompanied by high fever, without tuberculosis poisoning symptoms, cough and sputum. There was marked tenderness and percussion pain in the T12 to L2 spinous processes. The muscle strength of both lower limbs was grade 5. On admission, the patient's white blood cells (WBC), neutrophil percentage (Neut%), lymphocyte percentage (Lymph%), procalcitonin (PCT), and erythrocyte sedimentation rate (ESR) were basically normal, while C-reactive protein (CRP) and percentage of monocytes (Mono%) were slightly higher ([Supplementary Figure 1](#)). X-rays of the patient's lungs showed no evidence of pulmonary tuberculosis ([Supplementary Figure 2](#)). Blood cultures and metagenomic next-generation sequencing (mNGS) were negative. Magnetic resonance imaging (MRI) of the lumbar spine at that time suggested possible infection of the T12 and L1 vertebrae ([Figure 1a and b](#)). The possibility of suppurative spondylitis was considered in the local hospital and anti-infective treatment was given, but the symptoms of low

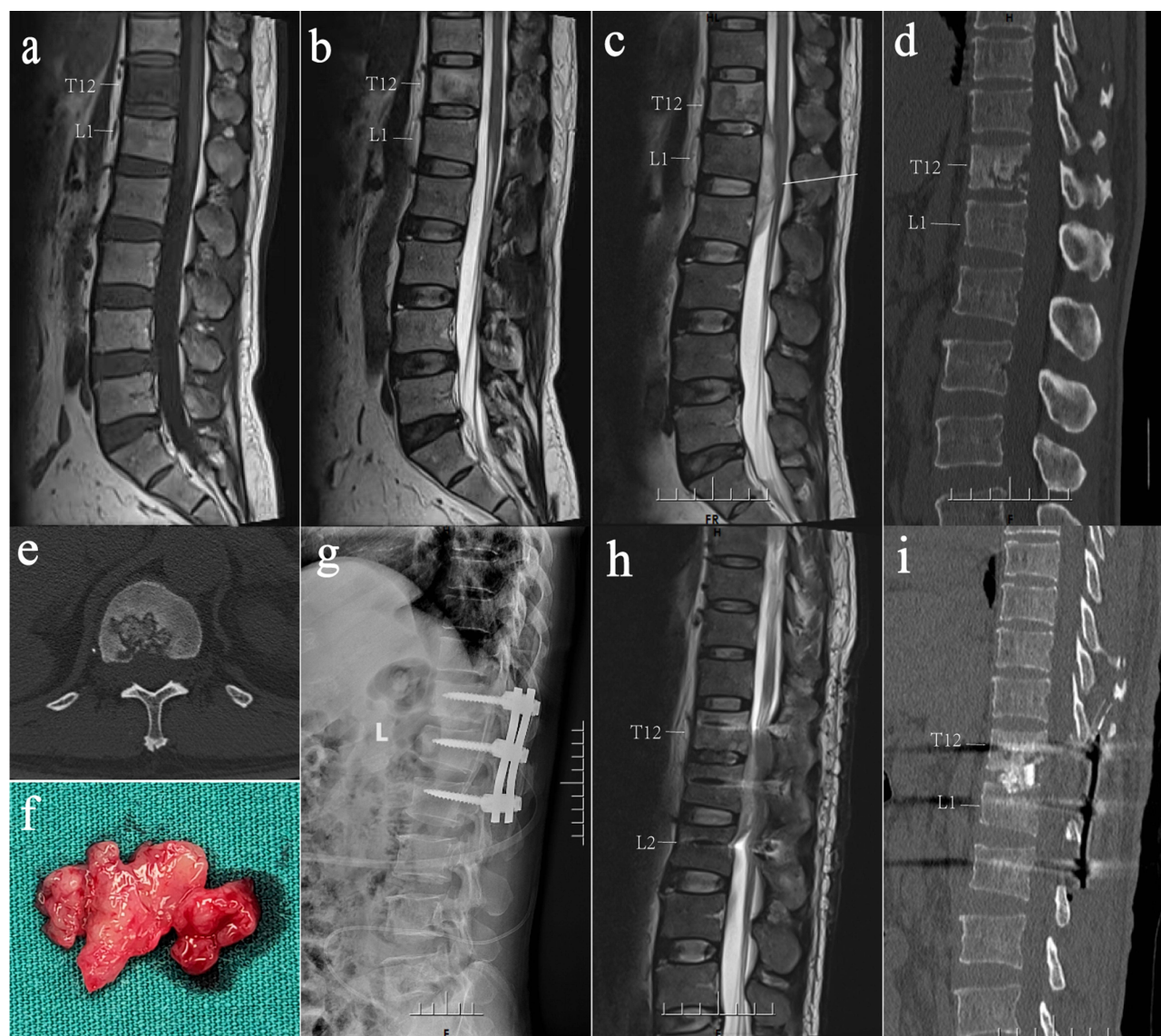


Figure 1 Patient surgery perioperative data for the first time. (a and b). In the early stage of the disease (July 4, 2022), lumbar MRI suggested the possibility of infection of the lower edge of T12 and the upper edge of L1. (c). The first preoperative lumbar MRI (August 29, 2022) showed a fusiform abnormal signal focus in the posterior of the T12-L2 vertebral body, which was considered to be a high possibility of infectious lesions. (d and e). The first preoperative lumbar CT (August 29, 2022) suggested bone destruction of T12 vertebral body and the possibility of infectious lesions. (f). The first operation technique to retrieve fish tissue specimens lesions, with necrotic tissue. (g–i). Postoperative review imaging (September 16, 2022) tip in a fixed position is good, the original T12 - L2 vertebral rear spindle focal abnormal signal have been cleared.

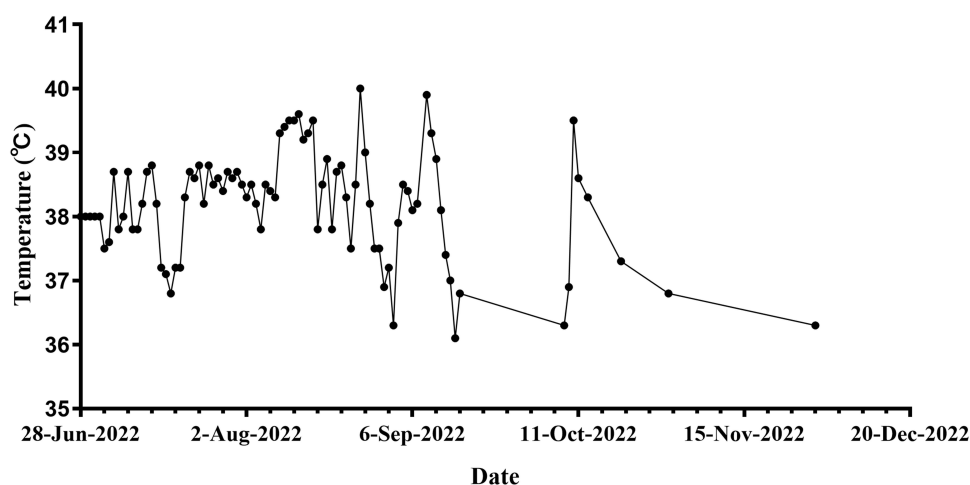


Figure 2 Trend chart of patient's body temperature.

back pain gradually increased, spreading to the lower back and sacroiliac region, and recurrent fever was observed (Figure 2). After that, in many hospitals, improving the undulant disease agglutination test negative, biopsy nor pyogenic infection and tumor evidence, lung CT not seen obvious abnormality, still thinking of pyogenic spondylitis, continued anti-infection treatment, no obvious relieve symptoms, the highest temperature of 40 °C (Figure 2).

He was admitted to our hospital on August 27, 2022, and lumbar computed tomography (CT) and MRI showed abnormal fusiform signal lesions behind the T12-L2 vertebral body, considering the possibility of infectious lesions (Figure 1c–e). The patient's WBC, Neut%, and Lymph% were basically normal, while CRP was 50mg/L and ESR was 106mm/h (Supplementary Figure 1). T-spot is positive. Based on the patient's condition, the possibility of lumbar tuberculosis infection was considered, and diagnostic ATT (isoniazid + rifampicin + ethambutol + pyrazinamide) was started on August 30, 2022. Repeated conservative treatment was ineffective, and there was a trend of further aggravation. On September 8, 2022, surgery was performed to decompressed the spinal canal and remove the lesion. The fish-like lesion tissue was removed during surgery (Fig.1f). Postoperative imaging was acceptable (Figure 1g–i). Xpert MTB/RIF detected tuberculosis DNA in the lesion and was positive for rifampin resistance genes, and the patient had a high postoperative fever (Figure 2). Ceftriaxone was added, and the antituberculosis regimen (isoniazid, levofloxacin, ethambutol, and pyrazinamide) was adjusted, and linezolid was added earlier.

More than 20 days after surgery, the muscle strength of both lower limbs progressively decreased to grade 3, and a reexamination of MRI of the lumbar spine revealed an aggravating intradural mass (Figure 3a and b). The indication for surgery was clear, and the patient underwent surgery again on October 9, 2022 for debridement of the lesion and spinal canal decompression. During the operation, fish-like tissue was found (Figure 3c and d). Postoperative culture, Xpert MTB/RIF and mNGS detected *Mycobacterium tuberculosis*, which was resistant to rifampin and isoniazid. Therefore, the patient was diagnosed as spinal MDR-TB, and the second-line ATT (cycloserine + para-aminosalicylic acid + ethambutol + levofloxacin + linezolid) was adjusted again. Postoperative imaging showed that there was no obvious space-occupying lesion in the spinal canal (Figure 3e–h).

At the time of discharge, the patient's low back pain was significantly relieved, and there was no fever. ATT and rehabilitation exercise were continued. ATT after six months in patients with double lower limbs muscle back to level 4, and radiographic review showed no relapse (Figure 3I and j). One and a half years later, the muscle strength of both lower limbs returned to normal, liver and kidney function were normal, and occasionally nausea, gastrointestinal discomfort and other symptoms were observed.

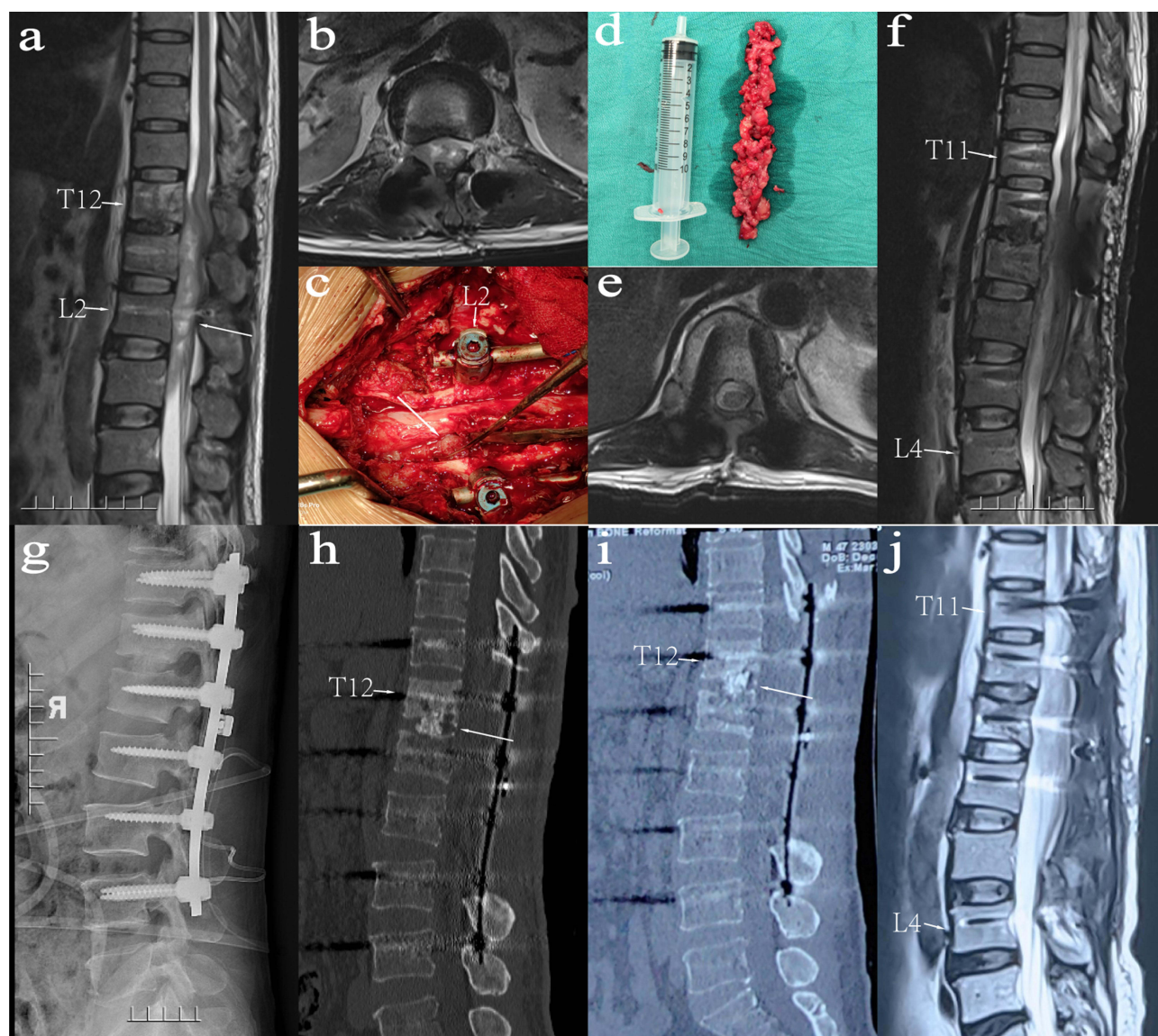


Figure 3 The second surgery and follow-up data. (a and b). Lumbar MRI before the second operation (October 8, 2022) showed fusiform abnormal signal lesions at the posterior of the T12-L4 vertebral body, spinal canal stenosis and spinal cord compression at the corresponding level. (c). During the second operation, a large amount of granulation tissue on the ventral side of the dural sac was found to be proliferated and elevated, compressing the dural sac with serious adhesion. (d). Granulation tissue and necrotic lesion tissue removed during operation. (e and f). Postoperative lumbar MRI (October 28, 2022) showed that the lesions posterior to T12-L4 were cleared, and the spinal cord compression was significantly relieved. (g and h). Postoperative lumbar X-ray and CT showed that the internal fixation position from T11 to L4 was good. (i and j). Half a year after operation, lumbar CT and MRI (March 20, 2023) showed that there was no breakage or loosening of T11-L4 internal fixation, no obvious compression of the posterior spinal cord, and T12/L1 bone graft fusion.

Discussion

Worldwide, 17% of new tuberculosis cases have drug resistance. MDR-TB is defined as resistance to Isoniazid (H) and Rifampicin (R). In addition to genetic susceptibility and co-infection with HIV, inadequate or incomplete treatment of such treatments predispose to the development of drug-resistant tuberculosis.⁶ Slow diagnostic methods hinder global tuberculosis control, especially the detection of drug-resistant forms. Drug-resistant diseases need to be identified and treated promptly.⁷ The growth of tubercular bacilli on culture used to be the standard for the diagnosis of tuberculosis, but it is difficult to diagnose spinal and other bone and joint tuberculosis because of its oligobacillus nature.^{8,9} It is necessary to synthesize multiple methods for diagnosis, and a single method cannot diagnose all STB cases.^{7,10} Molecular tests do not require mycobacterial growth and allow early detection from a small number of specimens but cannot distinguish between live/dead organisms or predict disease activity.⁷

Spinal tuberculosis has been reported to be diagnosed with an average delay of 6–8 months.⁷ Early diagnosis and treatment can effectively control the progress of spinal tuberculosis, reduce the incidence of complications, and improve the prognosis of patients with spinal tuberculosis.⁷ For uncertain spinal bone destruction, biopsy may be a preliminary diagnosis of the preferred method.⁴ Spinal tuberculosis is a kind of deep lesions, acquisition organization or pus sample is difficult, even if there is sample, growth and cultivate mycobacterium sensitivity is low, the diagnosis is difficult.¹¹ In this case, the patient in this case was a middle-aged man with good nutritional status, no cough and sputum, no low immunity and defects, and did not belong to the tuberculosis susceptible population. The patient was initially misdiagnosed as suppurative spondylitis with progressively worsening symptoms and recurrent fever, and was treated as suppurative spondylitis before surgery with poor efficacy.

Even if the spinal tuberculosis is diagnosed correctly, the treatment of spinal MDR-TB is very difficult. Spinal MDR-TB usually occurs between 15 and 30 years old. The most common lesion site is the thoracolumbar spine, and the most common symptom is local pain.¹² Yadav et al⁷ reported that the proportion of primary drug resistance in spinal tuberculosis was 25.49%. Tuberculosis control is hampered by insensitivity of drug resistance detection methods.¹³ Culture - or genotype-based drug susceptibility testing is an effective way to detect drug resistance, in which genotype testing provides faster diagnostic results.¹⁴ Spinal tuberculosis often lead to cannot repair of nerve injury, including paralysis.¹² Treatment of spinal MDR-TB requires a multidisciplinary team, complex and long course of treatment. It usually requires a combination of drug treatment, surgical treatment and rehabilitation treatment. Second-line anti-tuberculosis drugs are mainly used for medical treatment, but these drugs are often associated with adverse reactions, such as QTcF prolongation, tingling and numbness. In some cases, treatment adjustment is required. The characteristics of spinal MDR-TB include long onset time, wide range of lesions and easy recurrence. For cases with progressive neurological deficit, progressive spinal deformity or failure of conservative treatment, surgical intervention with debridement and stable internal fixation should be performed, which can not only help to obtain samples, but also reduce bacterial load.^{15,16} During the ATT, the patients should be reexamined regularly, the recurrence of tuberculosis should be monitored in time, and the adverse drug reactions should be treated. In this case, we performed spinal internal fixation surgery at an early stage to obtain suitable samples, and performed debridement and spinal canal decompression. At the same time, we carried out second-line anti-tuberculosis treatment to control the tuberculosis focus, effectively shorten the hospital stay of the patient, and improve the effect of drug treatment. There was no recurrence of tuberculosis during the follow-up, and there were some adverse reactions, but they were relieved after symptomatic treatment.

Conclusion

A 46-year-old male patient was misdiagnosed with a pyogenic spinal infection and failed to respond to treatment for 2 months. Surgical clearance of the lesion was performed, and a diagnosis of MDR-TB of the lumbar spine was confirmed. This suggests that the clinical symptoms of spinal MDR-TB are not typical, and the imaging examination is also lack of specificity. When the diagnosis of spinal bone destruction is not clear or the treatment is ineffective, diagnostic ATT can be used. For patients with spinal instability or spinal canal occupying, early surgical removal of lesions, tissue culture, Xpert MTB/RIF and mNGS to identify pathogens and drug resistance, timely diagnosis and treatment can maximize the prognosis of spinal MDR-TB.

Abbreviations

MDR-TB, multi-drug resistant tuberculosis; ATT, anti-tuberculosis treatment; mNGS, metagenomic next-generation sequencing; CT, computed tomography; MRI, magnetic resonance imaging; WBC, white blood cell; Neut%, percentage of neutrophil; Lymph%, percentage of lymphocytes; Mono%, percentage of monocytes; CRP, C-reactive protein; ESR, erythrocyte sedimentation rate; PCT, procalcitonin.

Data Sharing Statement

The datasets used and/or analyzed during the current study are available from the corresponding author on reasonable request.

Ethics Approval and Consent to Participate

This study was approved by the Ethics Committee of Xiangya Hospital, Central South University. Written informed consent was acquired from each of the patient to authorize treatment, imageology findings, and photographic documentation. The whole research process follows the Declaration of Helsinki.

Consent for Publication

The ethics committee of Xiangya Hospital, Central South University approved the publication of this case report. The patients consented to the publication of their pictures as well as their anonymous and clustered data.

Acknowledgments

We are very grateful for all the subjects who participated in the study.

Author Contributions

All authors made a significant contribution to the work reported, whether that is in the conception, study design, execution, acquisition of data, analysis and interpretation, or in all these areas; took part in drafting, revising or critically reviewing the article; gave final approval of the version to be published; have agreed on the journal to which the article has been submitted; and agree to be accountable for all aspects of the work.

Funding

This work was supported by the Natural Science Foundation of Hunan Province, China [grant numbers:2020JJ4892] and Fundamental Research Funds for the Central Universities, China [grant numbers: 2012QNZT126].

Disclosure

The authors declare that they have no competing interests.

References

1. Motta I, Boeree M, Chesov D, et al. Recent advances in the treatment of tuberculosis. *Clin Microbiol Infect.* **2024**;30(9):1107–1114. doi:10.1016/j.cmi.2023.07.013
2. Dheda K, Mirzayev F, Cirillo DM, et al. Multidrug-resistant tuberculosis. *Nat Rev Dis Primers.* **2024**;10(1):22. doi:10.1038/s41572-024-00504-2
3. Jain AK, Jain P, Jaggi K, et al. Drug-resistant bone, joint and spine tuberculosis, evolution of diagnosis and treatment. *Indian J Orthop.* **2024**;58(6):661–668. doi:10.1007/s43465-024-01138-y
4. Xiao S-T, Zhang H-Q, Wang Y-X. Isolated neural arch tuberculosis with tuberculomas, case report. *Skeletal Radiol.* **2024**;53(7):1417–1421. doi:10.1007/s00256-023-04450-0
5. Dadlani R, Dadlani R, Manam G. Isolated primary MDR tuberculosis of a lumbar spinous process, in an immunocompetent patient, mimicking a spinal tumour. *J Assoc Physicians India.* **2018**;66(6):109–110.
6. Tuli SM. General Principles of Osteoarticular Tuberculosis. *Clin Orthop Relat Res.* **2002**;398:11–19.
7. Yadav M, Jain AK, Singhal R, Chadha M, Arora VK, Bhargava A. Incidence and patterns of drug resistance in patients with spinal tuberculosis, a prospective, single-center study from a tuberculosis-endemic country. *Indian J Orthop.* **2023**;57(11):1833–1841. doi:10.1007/s43465-023-00986-4
8. Garg RK, Somvanshi DS. Spinal tuberculosis, a review. *J Spinal Cord Med.* **2011**;34(5):440–454. doi:10.1179/2045772311Y.00000000023
9. Lee JY. Diagnosis and treatment of extrapulmonary tuberculosis. *Tuberc Respir Dis.* **2015**;78(2):47–55. doi:10.4046/trd.2015.78.2.47
10. Abhimanyu S, Jain AK, Myneedu VP, Arora VK, Chadha M, Sarin R. The role of cartridge-based nucleic acid amplification test (CBNAAT), line probe assay (LPA), liquid culture, acid-fast bacilli (AFB) smear and histopathology in the diagnosis of osteoarticular tuberculosis. *Indian J Orthop.* **2021**;55(Suppl 1):157–166. doi:10.1007/s43465-020-00326-w
11. Li L, Zhang Z, Luo F, et al. Management of drug-resistant spinal tuberculosis with a combination of surgery and individualised chemotherapy, a retrospective analysis of thirty-five patients. *Int Orthop.* **2012**;36(2):277–283. doi:10.1007/s00264-011-1398-0
12. Yang S, Yu Y, Ji Y, et al. Multi-drug resistant spinal tuberculosis-epidemiological characteristics of in-patients, a multicentre retrospective study. *Epidemiol Infect.* **2020**;148:e11. doi:10.1017/S0950268820000011
13. Boehme CC, Nabeta P, Hillemann D, et al. Rapid molecular detection of tuberculosis and rifampin resistance. *N Engl J Med.* **2010**;363(11):1005–1015. doi:10.1056/NEJMoa0907847
14. WHO. Guidelines Approved by the Guidelines Review Committee. edn. In, *Xpert MTB/RIF Implementation Manual, Technical and Operational 'How-To'; Practical Considerations*. Geneva, World Health Organization Copyright © World Health Organization; **2014**.
15. Leowattana W, Leowattana P, Leowattana T. Tuberculosis of the spine. *World J Orthop.* **2023**;14(5):275–293. doi:10.5312/wjo.v14.i5.275
16. Qian J, Rijiepu A, Zhu B, Tian D, Chen L, Jing J. Outcomes of radical debridement versus no debridement for the treatment of thoracic and lumbar spinal tuberculosis. *Int Orthop.* **2016**;40(10):2081–2088. doi:10.1007/s00264-016-3234-z

Infection and Drug Resistance**Publish your work in this journal**

Infection and Drug Resistance is an international, peer-reviewed open-access journal that focuses on the optimal treatment of infection (bacterial, fungal and viral) and the development and institution of preventive strategies to minimize the development and spread of resistance. The journal is specifically concerned with the epidemiology of antibiotic resistance and the mechanisms of resistance development and diffusion in both hospitals and the community. The manuscript management system is completely online and includes a very quick and fair peer-review system, which is all easy to use. Visit <http://www.dovepress.com/testimonials.php> to read real quotes from published authors.

Submit your manuscript here: <https://www.dovepress.com/infection-and-drug-resistance-journal>

Dovepress
Taylor & Francis Group