

# Urogenital Manifestations in Mpox (Monkeypox) Infection: A Comprehensive Review of Epidemiology, Pathogenesis, and Therapeutic Approaches

Sike He\*, Jingge Zhao<sup>ID</sup>\*, Junru Chen, Jiayu Liang, Xu Hu<sup>ID</sup>, Xingming Zhang, Hao Zeng<sup>ID</sup>, Guangxi Sun

Department of Urology, Institute of Urology, West China Hospital, Sichuan University, Chengdu, People's Republic of China

\*These authors contributed equally to this work

Correspondence: Guangxi Sun; Hao Zeng, Department of Urology, Institute of Urology, West China Hospital, Sichuan University, Chengdu, People's Republic of China, Email [sungx077@126.com](mailto:sungx077@126.com); [kucaizeng@163.com](mailto:kucaizeng@163.com)

**Abstract:** Monkeypox (mpox), caused by mpox virus (MPXV) infection, reemerged in 2022 and still raises concerns globally. Abundant clinical data indicate that mpox is a sexually transmitted infection and that the urogenital system is the most frequently involved system in mpox, which deserves more attention. Penile lesions are the most common presentation, followed by urethritis. Acute urine retention and acute kidney injury are relatively rare but also highly crucial. Currently, the majority of the urogenital lesions are considered complications secondary to MPXV infection and the common immunosuppression in mpox patients. However, such viewpoints should be treated carefully due to the lack of understanding of the basic mpox pathology. Here, we briefly and comprehensively review the current evidence concerning urogenital lesions caused by mpox, including epidemiology, clinical features, pathogenesis, and therapeutic approaches to provide a preliminary reference for clinicians in future clinical practice.

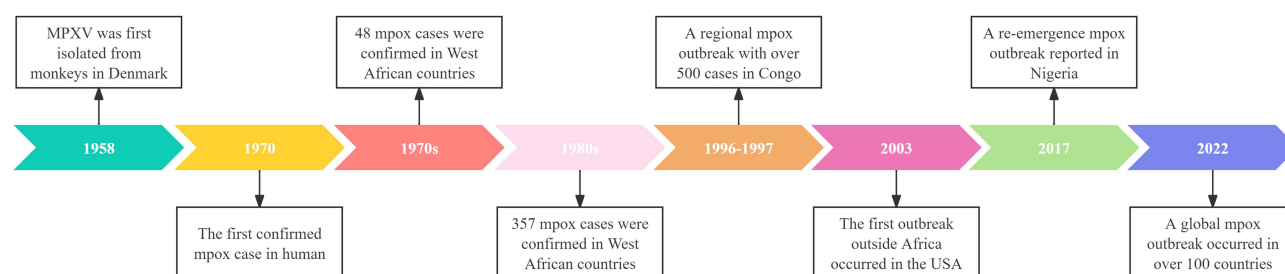
**Keywords:** mpox, mpox virus, sexually transmitted infection, urogenital lesion, urologist

## Introduction

The mpox virus (MPXV), a member of the Orthopoxvirus genus, is the cause of mpox (formerly known as monkeypox), a zoonotic illness. The virus was first identified in humans in the Democratic Republic of the Congo in 1970 after it was discovered in monkeys transported from Singapore to Denmark in 1958.<sup>1</sup> Due to its sporadic outbreaks related to contact with wildlife reservoirs (particularly rodents), mpox was subsequently considered a rare infectious zoonotic disease until 2022.<sup>1,2</sup>

The World Health Organization (WHO) declared mpox an “evolving threat of moderate public health concern” on June 23, 2022, after more than 3000 cases were reported in more than 50 countries across five regions since early May 2022.<sup>2</sup> During the past decades, mpox has undergone a rapid evolution and worldwide transmission and ended up being a global pandemic (Figure 1).<sup>1,3,4</sup> The disease has become a new threat to the world's health systems, which are still slowly recovering from the significant shocks caused by the COVID-19 epidemic.<sup>5</sup>

Similar to most virus infections, mpox is self-limited and can recover after the immune clearance of MPXV.<sup>6</sup> However, numerous reports have shown that the course of mpox infection in humans typically resolves on its own with mild symptoms lasting for 2–4 weeks, including fever, chills, headache, muscle soreness, and lymphadenectasis, a small percentage of patients exhibit signs of severe illness that can result in hospitalization or even death.<sup>1,4,7–9</sup> Recently, a meta-analysis including 1958 patients revealed that 35% of mpox-infected patients were admitted to hospitals and that 4% (95% CI: 1%–9%) of the inpatients had fatal outcomes.<sup>8</sup>



**Figure 1** The timeline of major milestones in mpox.

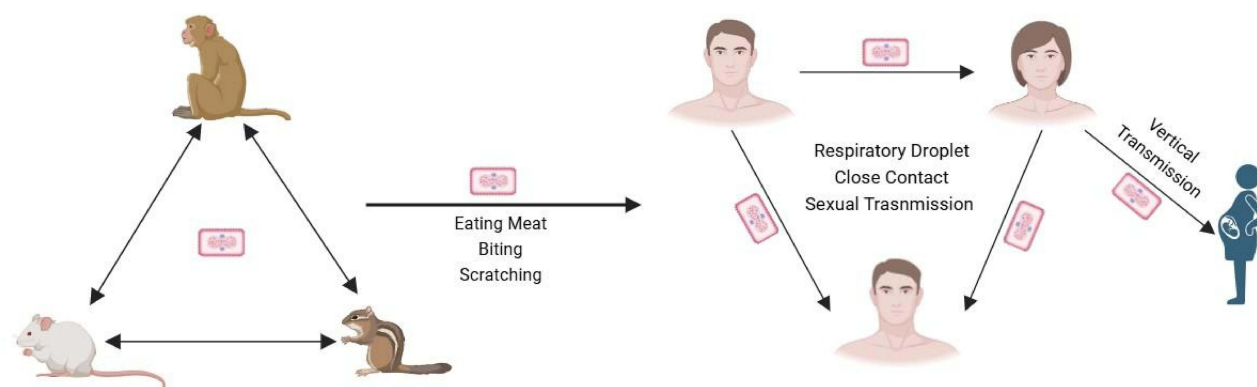
According to several cohort and case-series investigations, the great majority of cases in the 2022–2023 outbreak were suspected to have been spread by close physical contact, mostly sexual behaviors, especially among men who have sex with men (MSM).<sup>2,10–13</sup> MPXV can be detected in genitourinary fluids (urine, seminal fluid, and vaginal fluid),<sup>2,14–17</sup> and virus replication has also been reported.<sup>16,18</sup> Urogenital manifestations, including penile skin lesions, penile edema, acute urine retention, and urethritis, are frequent among mpox cases and are often the reason for consultation visits.<sup>19</sup> More importantly, kidney injury caused by mpox, especially in hospitalized patients and kidney transplant recipients, should receive increased attention.<sup>2,17</sup> All the evidence emphasized that urogenital lesions in mpox have diverse features and deserve further consideration. Therefore, this review aims to summarize the current studies on urogenital system manifestations in mpox and urge clinicians to pay more attention to urogenital disorders and timely medical intervention.

## Virology of MPXV

MPXV belongs to the same genus as cowpox virus, vaccinia virus, and variola virus, which are all orthopoxviruses (double-stranded DNA viruses) and smallpox pathogens, respectively. A brick-like virion, 200–250 nm in size, is found by electron microscopy (EM) to be identical to the virions of vaccinia or variola viruses.<sup>4,20</sup> With over 200 kilobase pairs, the MPXV genome is large and encodes about 190 proteins used to construct viral particles and alter host functions. Two clades (clades 1 and 2) were previously found in various African regions and showed genomic sequence variations of approximately 0.5%. While clade 2 (with low case-fatality rates of less than 0.1%) was discovered in West Africa, clade 1 (with high case-fatality rates of 1–12%) was the cause of sickness in Central Africa.<sup>20–22</sup> The genetic variations between them that take place in areas that encode crucial virulence genes may account for the variations in clinical severity. Clade 2b, a novel lineage B.1, was found to be the cause of the epidemic in 2022.<sup>4,20,23</sup> This lineage exhibits multiple gene mutations related to host recognition, virulence, and immune evasion. Compared with previously obtained genome sequences of MPXV isolated in Nigeria in 2018, the MPXV strains that emerged recently exhibited more single nucleotide polymorphisms (SNPs).<sup>20,21</sup> Isidro et al conducted an in-depth mutational analysis and suggested that the function of host APOBEC3,<sup>24</sup> which serves as a cellular defense mechanism by introducing errors into the viral genome, is vital in MPXV evolution as well as signs of potential MPXV human adaptation in ongoing microevolution, which has been validated in other large-scale genomic investigations.<sup>25–27</sup> The significance of such mutations is underexplored, but they may trigger a sudden appearance large amount of human-to-human transmission (HHT) and increase the transmissibility in non-endemic regions, and emphasize the importance of both genomic surveillance in tracking spatiotemporal dynamics of MPXV clades.

## Transmission of MPXV

Monkeys were not the most frequent reservoir, despite the term “monkeypox”. In central Africa, several rodents (eg, African pouched rat, squirrel, and dormouse) and primates (eg, chimpanzee, sooty mangabey, and baboon) are the natural hosts of MPXV.<sup>20,28,29</sup> Early reports generally associated MPXV infections with interactions with infected animals, such as eating raw meat or coming into contact with mucosal membranes, bodily fluids, and tissues.<sup>20,30</sup> Additionally, scratches or bites from infected animals can spread the infection. Direct contact with respiratory secretions from infected people is considered the cause of HHT.<sup>1,20,31</sup> Then, vertical transmission (VT) was also described.<sup>32</sup> Both HHT and VT



**Figure 2** The transmission pattern of MPXV.

used to be rare in historical events, however, in the current outbreak in 2022, the consistent existence of MPXV in genital fluid, the successful culture of MPXV from the anal and urethral swabs, and the various occurrences of lesions observed lesions occurred in the anal and genital regions strongly supported that the frequent and rapid transmission of mpox could be associated with sexual contact between individuals, especially among MSM,<sup>2,33</sup> and that mpox should be considered a sexually transmitted infection (STI).<sup>2,15,33</sup> A schematic of the mpox transmission route is shown in Figure 2.

## Pathogenesis of MPXV

Data on various orthopoxviruses and primate models are widely used to extrapolate current views on the pathogenesis of mpox in humans.<sup>1</sup> The infection and replication of MPXV within keratinocytes, fibroblasts, antigen-presenting cells, or airway epithelial cells allow MPXV to enter adjacent tissues through mucous membranes, including ocular, respiratory, oral, urethral, rectal, or broken skin when exposed to the respiratory secretions or bodily fluids of infected patients.<sup>1,20</sup> During historical outbreaks, the mean incubation period of MPXV infection was 5–13 days, while in the 2022 outbreak, the mean incubation period was commonly 7–10 days after exposure. The shorter incubation period could be caused by direct viral inoculation through sexual transmission.<sup>4,34</sup> The latent period for MPXV then occurs as a result of the virus spreading throughout the body through tissue-resident immune cells and draining lymph nodes.<sup>20</sup> Lesions are distributed according to lymphatic spread, and the virus then spreads systemically to the liver, spleen, and other large organs. There, it amplifies and causes a second major viremia wave, which may then enable the virus to spread to other distant organs, including the skin, lungs, kidneys, intestines, cerebrospinal fluid, and mediastinal lymph nodes.<sup>4,20,35</sup> Primate models of subcutaneous injection exhibit modest, localized illness following clade 2 MPXV infection, with viral replication limited to the skin and lymphatic system. Following skin injection with clade 1 MPXV, the genitourinary, gastrointestinal, and respiratory systems may be impacted. The only data available on human skin inoculation come from immunization with the variola or vaccinia viruses, which cause minor lesions near the site of entry. Similarly, mpox was likely to be transmitted through sexual contact and genital secretions during the latest outbreak, resulting in some odd clinical symptoms.<sup>2,4,8,36</sup>

Both humoral and cellular immune responses are stimulated to block MPXV replication and induce long-term immunity after recovery.<sup>37,38</sup> Humoral immune response to MPXV infection compromises MPXV-specific immunoglobulin M (IgM) and IgG against antigens with long-term persistence of residual IgG-memory B cells that protect hosts from reinfection and developing severe illness.<sup>39</sup> Then, cellular immune response to MPXV infection is mainly Th1 biased and is characterized by a rapid expansion of activated effector CD4<sup>+</sup> and CD8<sup>+</sup> T cells.<sup>37,40</sup> Most patients have specific T cells to produce Th1-related inflammatory cytokines (eg, IL-1 $\beta$ , IL-6, IL-8, IFN- $\gamma$ , and TNF).<sup>41</sup> Functionally, effector CD4<sup>+</sup> T cells enhance recall and differentiation of B cells into antibody-secreting cells, whereas CD8<sup>+</sup> T cells can kill infected macrophages to prevent MPXV spread. In nonhuman primate models, neutralizing antibodies produced by B cells are especially important for avoiding fatal infection, while CD4<sup>+</sup> or CD8<sup>+</sup> T cell depletion only slightly affects disease protection.<sup>4,42</sup> However, such protective B-cell responses and antibodies was reduced due to CD4<sup>+</sup> T cell depletion before

immunization, and the severity of the infection was markedly increased.<sup>42</sup> Additionally, MPXV can evade antiviral CD4<sup>+</sup> and CD8<sup>+</sup> T cell responses by suppressing cognate T cell activation.<sup>40</sup> A deeper understanding of T cells in mpox may provide more insight into disease management.

## Risk Factors

In the past, living in wooded regions (particularly close to squirrel-habitable locations), residing with mpox patients, being male, and being under 15 years old were all recognized risk factors for mpox in African nations.<sup>4,43,44</sup> In the recent outbreak, the majority of mpox patients (98%, 519/528) were identified as MSM,<sup>2</sup> and high-risk sex behaviors were the most reported potential risk factors.<sup>2,10,13</sup> A large percentage of people with HIV (PWH) are mpox patients (36–42%), and a significant portion (33–42%) are on pre-exposure prophylaxis to avoid contracting HIV.<sup>4,45–47</sup> Children, pregnant women, immunocompromised patients, especially those untreated PWH infection, and solid organ transplant recipients (SOTRs) are among the groups most at risk of developing severe disease.<sup>4,34,48,49</sup> However, the role of HIV infection in mpox severity remains obscure. A meta-analysis by de Oliveira et al revealed that the hospitalization rates were comparable between PWH and patients without HIV (odds ratio [OR] = 1.13, 95% CI: 0.28–4.46,  $p = 0.87$ ).<sup>50</sup> Other clinical features, illness severity, and clinical outcomes are comparable between patients with HIV positive and negative, although the former are more likely to have skin rash.<sup>2,12,13,51</sup> Therefore, it is suggested that immunological status be used to determine the severity of mpox. According to previous reports, untreated PWH with low CD4<sup>+</sup> T cell counts ( $<200/\mu\text{L}$ ) may be more susceptible to severe, widespread, or protracted mpox.<sup>4,49</sup> The mechanism of the interaction between HIV and MPXV is still unclear, and researchers tend to assume that the function and load of T cells plays a central role. Following recovery from MPXV infection, virus-specific T-cell responses are detected in PWH, suggesting that T-cell responses play a role in MPXV infection recovery.<sup>52</sup> This viewpoint can also indirectly support the severe mpox features in SOTRs.<sup>48,53</sup> Some common pathogenesis and candidate hub genes (eg, *MX2*, *ADAR*, and *POLR2H*) and related pathways (eg, regulation of viral infection, inflammation, and activation of innate immunity) in MPXV-HIV coinfection have been explored and are still needed to be validated.<sup>54</sup> Moreover, evidence that patients living with autoimmune diseases (AIDs) receiving special treatment (eg, glucocorticoids, monoclonal antibodies) are at increased risk of severe mpox is extremely limited. Few cases and historical experiences from recent COVID-19 cases indicate that AIDs are likely to be risk factors for severe illness.<sup>10,55</sup> The assessment of immunological status may provide insights into this hypothesis.

## Clinical Presentations

Historically and classically, mpox induced prodromal systemic symptoms that caused by viremia. These symptoms usually appear prior to the skin rash and last for 1–5 days, including general discomfort, fever, myalgias, sore throat, and lymphadenectasis.<sup>1,4</sup> Rashes start on the head and face and eventually spread to the entire body following the fever and lymphadenectasis. From papules to vesicles and pustules, the rash eventually develops into crusts that cure and leave scars (more details about skin rash will be discussed in [*Penile lesions*] below). This progressive phase of rash often lasts around 2–4 weeks. The median time from the onset of skin lesions to the dry crust formation is approximately 10 days (interquartile range: 7–13).<sup>1,13</sup> The number of skin lesions can vary widely, with over 100 lesions noted in almost 20–50% of patients.<sup>4</sup> In the recent 2022 outbreak, several novel and unusual presentations have been observed. These presentations include lesions involving anogenital, oropharyngeal, and vaginal mucosal surfaces, with a significant proportion of patients presenting with anogenital lesions alone; proctitis; anorectal pain; and odynophagia. These manifestations, particularly the anogenital lesions, are highly prevalent in MSM.<sup>4,20</sup> According to a large international case series of mpox in MSM, the most frequent locations of skin lesions were the anogenital area, followed by the trunk, arms, legs, face, and the palms and soles.<sup>14</sup> Such lesion distribution could potentially be explained by the main infected populations and the transmission pattern of this outbreak.

## Diagnosis

The combination of suspected epidemiological data, clinical observations, and laboratory tests can be used to determine the diagnosis of mpox. Preliminary diagnosis is made based on clinical manifestations, which are typically acute skin

rashes, including mucosal lesions in the mouth, conjunctiva, penis, vagina, or anorectal area; proctitis or lymphadenopathy in patients; and influenza-like symptoms in patients following high-risk exposure.<sup>4,56,57</sup> Final confirmation is achieved through laboratory examinations such as polymerase chain reaction (PCR) tests, virus isolation, and serological testing, which detect specific antibodies against MPXV. The WHO recommends PCR for early diagnosis based on its high sensitivity and specificity.<sup>56,58</sup> Skin lesion material, such as swabs of the lesion surface or exudate and lesion crusts, is the best specimen for laboratory confirmation of mpox. In some situations, biopsies can also be carried out.<sup>4</sup> Based on the time course of MPXV infection, a higher positive rate can be obtained by testing the sample collected during the first three weeks after symptoms onset.<sup>59</sup> As for blood samples, routine PCR is recommended since viremia occurs in the early stage of MPXV infection when the symptoms are nonspecific.<sup>60</sup> Although they still work, the conventional methods of viral isolation, EM detection, and immunohistochemistry require highly developed techniques and an advanced laboratory.<sup>57</sup> The cause of cases that are discovered after the fact can be ascertained via antibody-based diagnostics. Serologically measuring anti-MPXV IgM is more helpful for diagnosing recent infections, including in people who have already received a vaccination, than measuring anti-MPXV IgG alone is more useful for retrospective patients who have been exposed to MPXV, including through vaccination.<sup>57,61</sup> Detection of IgM from patients with acute illness (4–56 days after rash onset) or IgG in paired serum samples (collected at least 21 days apart, with the first being collected during the first week of ill) can augment diagnostic accuracy.<sup>4,62</sup>

Differential diagnosis for mpox includes consideration of other viral illnesses with similar clinical presentations, such as smallpox, chickenpox, and other poxvirus infections. The distribution of lesions in clade 1 mpox resembles smallpox.<sup>56</sup> In contrast, clade 2 mpox often manifests genital, perianal, and oral regions. Oral or perioral lesions can be mistaken for syphilis (chancriform papules), oral candidiasis (pseudomembranous plaques), and herpes simplex virus (HSV) (ulcers).<sup>63</sup> Since genital ulcers are common in clade 2 mpox, syphilis, HSV, and chancroid should all be taken into consideration. People who have vaginal and oral ulcers should be evaluated for certain inflammatory conditions, such as Behcet's illness. Several STIs have become more common in recent years, and mpox frequently coexists with other STIs such as syphilis, chlamydia, gonorrhea, lymphogranuloma venereum, and HIV. This should be taken into account for all patients who present with genital lesions.<sup>63,64</sup> For a detailed differential diagnosis of infection caused by different MPXV subtypes and of mpox and other diseases, please refer to the review by Cowen et al (Ref<sup>63</sup>). Notably, in practice, clinical differentiation of mpox from similar clinical conditions can be difficult without laboratory diagnosis.<sup>18</sup>

## Urogenital Lesions in Mpox

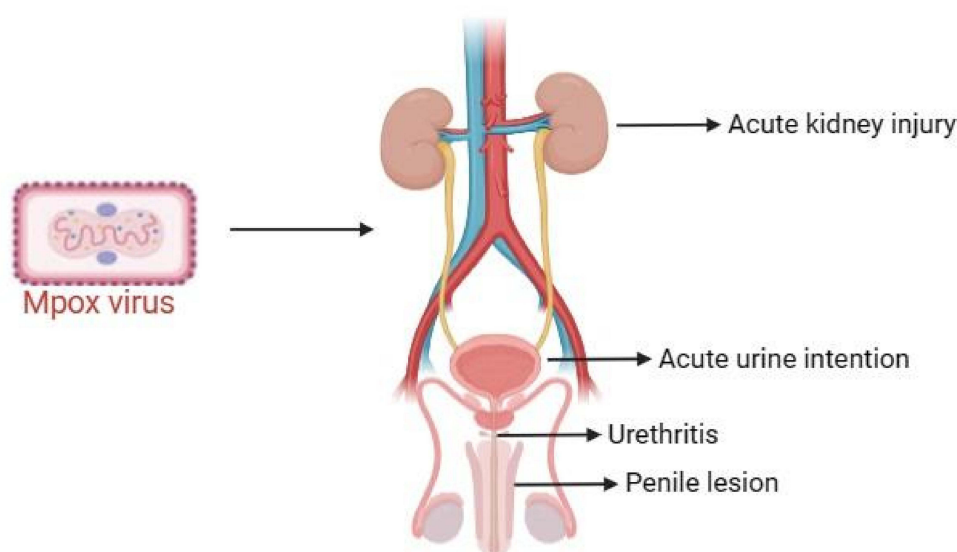
Numerous urogenital lesions significantly increase the number of visits to urology and andrology clinics.<sup>19,36,65,66</sup> Although lesions of the male external genitalia are consistent with STIs, some complications in the upper urinary tract make it important for clinicians to consider the more complex pathogenicity of MPXV, rather than just an STI, although the data are limited. We briefly summarize cases of urogenital lesions and related key findings reported in previous studies in [Table S1](#). The urogenital system involvement in mpox, including its clinical features, pathogenesis, and management, is discussed in the following parts of this review ([Figure 3](#)).

## Acute Kidney Injury

### Epidemiology Data

Data from historical mpox outbreaks revealed no cases of acute kidney injury (AKI), which is characterized by a rapid decline in renal function (defined as an increase in serum creatine [sCr] of  $\geq 50\%$  within 7 days or an increase in sCr of  $\geq 0.3$  mg/dl (26.5  $\mu$ mol/l) within 2 days or oliguria for  $\geq 6$  hours) associated with poor outcomes.<sup>67</sup> A multi-national case series, enrolling 528 mpox cases, reported two AKI cases.<sup>2</sup> Another cohort focused on the clinical features of mpox in SOTRs and found one AKI case.<sup>48</sup> All of the 3 AKI patients were ultimately survived. Additionally, due to the high incidence of MPXV-HIV co-infection, the challenge of AKI is magnified since PWH with multiple comorbidities, co-infections, and nephrotoxic drugs complicate its management.<sup>68</sup> Although only a few studies have reported kidney complications, the occurrence of AKI in these patients should raise concerns.

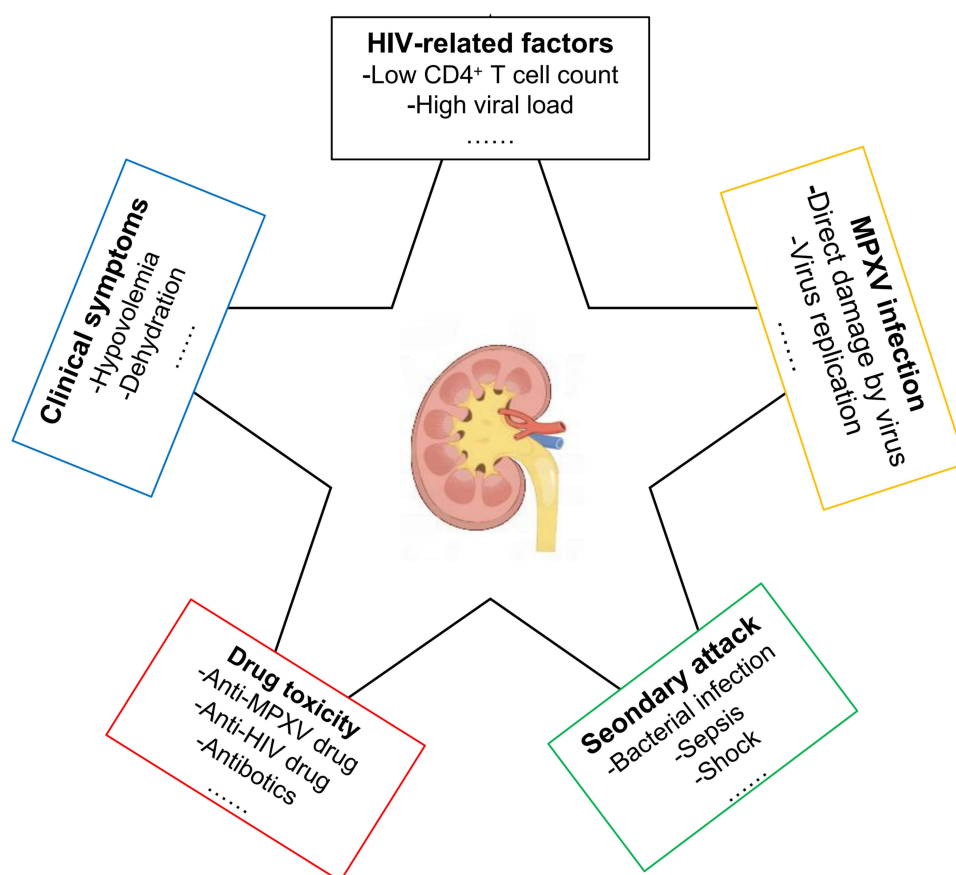




**Figure 3** The overview of urogenital manifestations in mpox.

## Potential Mechanism

Some mechanisms have shown to be responsible for AKI. The etiology of AKI is conceptually classified into three categories: prerenal, intrarenal, and postrenal.<sup>69</sup> In mpox-related AKI, prerenal and intrarenal AKI were observed in patients and in in vitro models, respectively. First, tiredness, painful oral lesions, fever, and widespread cutaneous rashes are common symptoms of mpox. These symptoms lead to a decrease in oral intake and an increase in insensible fluid loss, which can lead to hypovolemia and dehydration.<sup>7,70</sup> The detection of MPXV in urine supported that MPXV directly infects the kidney.<sup>71</sup> MPXV is an orthopoxvirus that can replicate in a variety of mammalian kidney cell lineages, including human kidney, pig embryo kidney, and baby hamster kidney. Human kidney tropism is therefore possible.<sup>72</sup> With the aid of human pluripotent stem cell-derived kidney organoids (HKOs), virus infection, kidney disease, and antiviral drug development can be simulated.<sup>71,73</sup> Li et al inoculated HKO with MPXV, finding a large increase of intracellular viral DNA and the HKO can stably excrete MPXV. Almost all cells were infected after 96 h, and on day 7, the HKO structures were disrupted. EM visualized the intracellular MPXV particles and captured the complete process of virus synthesis which demonstrated that HKO can support the full life cycle of MPXV.<sup>71</sup> Third, the drug-induced AKI has been explored in depth, especially in immunosuppressed hosts, such as SOTRs and patients with HIV.<sup>7,48,53</sup> Recent literature shows that mpox patients are treated with antiviral therapy empirically, including cidofovir, which can cause apoptosis in the proximal tubular cells, leading to AKI and dose-dependent tubular injury (Fanconi syndrome).<sup>2,74,75</sup> A multicenter retrospective study of hematopoietic cell transplant recipients treated with cidofovir presented that more than 25% of patients developed nephrotoxicity with an increased sCr and a decreased estimated glomerular filtration rate.<sup>76</sup> Additionally, tecovirimat, a new drug for mpox, potentially causes AKI, although no severe adverse events were reported.<sup>48,77</sup> However, injectable tecovirimat is formulated with hydroxypropyl- $\beta$ -cyclodextrin, which is nephrotoxic and is eliminated in the urine.<sup>7</sup> Some HIV-related factors, such as low CD4<sup>+</sup> T cell count, and high viral loads, can significantly increase the AKI risk, and the mechanisms were reviewed previously, however, some divergences exist.<sup>78–81</sup> In contrast to the above two factors, the AKI related to antiretroviral therapy (ART) was more clarified. Many ART agents are secreted or cleared by the kidney, so nephrotoxicity is inevitable.<sup>82</sup> For example, tenofovir, the most common drug ART, is related to a 5% increased AKI risk. The main mechanism of tenofovir nephrotoxicity is cellular accumulation by increased entrance from human organic anion transporters and decreased efflux into the tubular lumen.<sup>78,82,83</sup> Other ART drugs have also been proven to have nephrotoxicity, including zidovudine, atazanavir, and rilpivirine.<sup>78,82</sup> Finally, secondary infections, sepsis, and shock might be reasons because of multiple organ failure (MOF).<sup>84</sup> However, the description of AKI in mpox only focuses on the outcomes without more information about the



**Figure 4** The mechanism of AKI in mpox.

clinical background (ie, renal function measurements, HIV status, and medication use), which hinders the identification of AKI etiology. The mechanism of AKI in mpox is graphically displayed in [Figure 4](#).

## Management

Although AKI is a rare complication of mpox, it should still be carefully considered by clinicians because of the poor prognosis. Prevention and management are closely related to the pathophysiology of AKI and the anti-viral therapy. AKI prevention usually starts with circulatory volume support and the early beginning of anti-MPXV medication. Regular fluid status assessment and quick fluid expansion are advised in cases of hypovolemia to achieve euvolemia, in addition to the standard renal function examination and subsequent dynamic monitoring.<sup>7,85</sup> Concerning mpox-related kidney injury, anti-viral therapy in the early stage is the key point. A preclinical experiment proved that MPXV-infected HKOs can respond to tecovirimat, with a significant reduction in the viral DNA load and even undetectable viral titers.<sup>71</sup> These medications, such as cidofovir and tecovirimat, should be considered for patients who present severe disease and well-functioning kidneys. Continuous renal function monitoring is vital during the anti-viral therapy, although the nephrotoxicity is still blurred. For PWH, normative ART can decrease the AIDS-dependent AKI risk, and medication adaptation is an applicable approach to prevent ART-related AKI. For instance, tenofovir alafenamide has been recently approved as an alternative tenofovir prodrug with a promising decrease in nephrotoxicity.<sup>78,86,87</sup> Additionally, human recombinant alkaline phosphatase (an endogenous enzyme that provides renal protection via the dephosphorylation of compounds, including endotoxins and proinflammatory mediators), blood purification, broad-spectrum antibiotics, and inotropic agents (eg, angiotensin II) are helpful in cases of MOF caused by sepsis and shock.<sup>84,88</sup> Finally, renal replacement therapy is vital for patients with severe renal impairment, especially those with obvious internal environment disorders and excessive volume loads. When a patient is in good condition, regular hemodialysis can be performed. Bedside

continuous renal replacement therapy is required if the patient is severely ill and cannot be transported or tolerate normal hemodialysis.<sup>89</sup>

## Acute Urine Retention

### Epidemiology Data

Acute urinary retention (AUR) is the most common urological emergency and is defined as the sudden and painful inability to voluntarily pass urine.<sup>90</sup> Regrettably, only five mpox cases (four male, one female) with AUR were reported so limited evidence can be provided, especially for the pathophysiology process of AUR.<sup>48,91–93</sup> Except for the cases who developed AUR secondary to penile lesions, including severe penile swelling and unretractable foreskin, as observed by Hackett et al,<sup>92</sup> the other patients were all admitted to the emergency department due to noninducible urination difficulty. AUR is among multiple complications in 3 kidney transplantation recipients, indicating severe disease in STORs.<sup>48,91</sup>

### Potential Mechanism

The primary etiology for AUR mainly consists of obstruction, infection, inflammation, pharmacologic, and neurogenic effects.<sup>94,95</sup> The mechanism of AUR in mpox patients remains under-recognized and under-researched. First, obstruction caused by penile morphological abnormalities is believed to be the most common trigger. Second, AIDS in mpox cases is another risk factor for AUR, which was widely reported for more than 30 years ago.<sup>96–102</sup> AUR is usually caused by secondary urinary tract infection (UTI) (eg, cystitis or prostatitis) and neurologic disorders due to AIDS (eg, HIV encephalitis, herpetic ascending myelitis, transverse myelitis (TM), central nervous system lymphoma, cerebral toxoplasmosis, and acute idiopathic polyneuritis) in AIDS patients.<sup>97,98,102–106</sup> Current evidence also shows that MPXV can lead to multiple neurological complications that may indirectly cause AUR, such as encephalitis, encephalomyelitis, and TM.<sup>7,84,107,108</sup> The reasons for these complications remain obscure because of inadequate data and poor understanding of mpox. These results imply that viral persistence and invasiveness may be noteworthy causes, especially in immunocompromised patients. The HIV-MPXV coinfection could further aggravate neurological damage to cause AUR and improve the understanding of MPXV-related neurological disorders. However, another hypothesis is that the neurological disorders are mainly attributed to postinfectious autoimmunity rather than direct viral invasion.<sup>47,107</sup> In summary, the lower urinary tract damage caused by infection and inflammation, the acquired lesions related to AIDS and immunosuppression, and the neurological invasion by MPVX are the major pathogenesis of AUR, but the mechanism needs further exploration.

### Management

The principle for AUR treatment in mpox patients is nonspecific. Bladder decompression, usually by indwelling urinary catheterization, is a fundamental approach to rapidly drain the bladder and relieve symptoms.<sup>90,94</sup> Notably, long-term indwelling catheterization should be avoided since it is positively associated with a greater risk of UTI, sepsis, trauma, urolithiasis, urethral strictures or erosions, prostatitis, and even cancer.<sup>109</sup> Typically, catheterization is done in a hospital, and if the patient is released with a catheter in place, an appointment is made for a trial without a catheter.<sup>94</sup> For infection-induced AUR, identifying the pathogen is vital after primary bladder decompression. Considering the wide immunosuppression and frequent antibiotic use in mpox patients, pathogens can be hardly detected by conventional methods (eg, culture, smear), and metagenomic next-generation sequencing is a useful alternative.<sup>110,111</sup> Anti-pathogen therapy after unraveling the pathogens can significantly improve the prognosis and decrease AUR recurrence risk.<sup>112</sup> AUR related to penile lesions, the combination of anti-viral medication, antibiotics, and anti-inflammatory drugs (regular non-steroidal anti-inflammatory drugs [NSAIDs]) are effective.<sup>92</sup> Despite its inability to penetrate the blood–brain barrier (BBB), cidofovir may then be taken into consideration for neurogenic AUR.<sup>113</sup> Because tecovirimat can pass through the blood–brain barrier in animal models, it was utilized to treat encephalitis.<sup>114</sup> Although tecovirimat and brincidofovir, the lipid prodrug of cidofovir, have been shown to work in concert in animal models, human trials are still required to corroborate these findings. Furthermore, longitudinally extensive TM responded well to therapy regimens that included methylprednisolone and plasmapheresis, with a favorable prognosis. There is no doubt that ART is necessary in



HIV-MPXV coinfection patients. Furthermore, appropriate rehabilitation intervention after recovery is pivotal for the long-term prognosis.<sup>115</sup> Finally, medication or surgical intervention for benign prostate hyperplasia (BPH) is the recommended therapy for BPH-related AUR,<sup>90,94</sup> however, since the age distribution of mpox patients is mostly young, this condition is rare in clinical practice.

## Urethritis

### Epidemiology Data

Urethritis, an inflammation (swelling and irritation) of the urethra typically caused by infection, especially STIs, is an important urological syndrome but is usually overlooked in mpox patients.<sup>116</sup> Liesenborghs et al indicated a considerable incidence of urethritis among mpox cases in Belgium (7.7%, 12/155), which is consistent with other case series and case reports.<sup>12,117,118</sup> A country-wide study in Mexico investigated a total of 3291 mpox patients, among whom 10 patients with urethritis. Another regional observational study investigated 56 mpox cases (23 HIV infected and 33 non-HIV infected), and urethritis was reported in 4 cases (3 in HIV infected group, 1 in non-HIV infected group).<sup>51</sup> In addition, HIV infection is likely to be a risk factor for urethritis (OR = 2.08, 95% CI: 1.88–2.29).<sup>119</sup> Zhao et al also observed a higher incidence of urethritis in the HIV-infected group than in the non-HIV-infected group, although the difference did not reach a statistical significance (3/23 vs 1/33,  $p = 0.295$ ).<sup>51</sup>

### Potential Mechanism

STI is almost the single cause of urethritis, and the pathogens are clarified in half of the cases, including *Chlamydia trachomatis* (CT), *Neisseria gonorrhoeae* (NG), *Mycoplasma genitalium* (MG), *Ureaplasma urealyticum* (UU), and rarely pathogens such as HSV, adenovirus, and *Trichomonas vaginalis* (TV).<sup>120,121</sup> The findings of a PCR test for NG, CT, MG, TV, and HSV, as well as a Gram stain and culture for NG from a urethral swab, were surprisingly negative when a urine sample from 1 HIV-negative subject was sent for testing. According to PCR revealed that an anal swab and a urine sample were positive for MPXV, suggesting that the urogenital tract has the highest viral load and that MPXV may be the direct cause of urethritis.<sup>116</sup> This viewpoint needs further validation by analyzing the pathogen spectrum from the urogenital tract in more patients.

## Management

Urethritis symptoms are not exclusive to mpox patients and can occasionally even appear before dermatological symptoms. Even in the absence of skin lesions, mpox should be taken into consideration in patients at risk of mpox who exhibit urethritis during an epidemic, and painful inguinal lymph node is a crucial sign of mpox.<sup>116,117</sup> The majority of the common pathogens can be easily identified via traditional methods (eg, culture, stain, etc.). Gonococcal urethritis is recommended to be treated with ceftriaxone plus azithromycin in single doses or ceftriaxone monotherapy in a single dose in cases of unknown antimicrobial susceptibility.<sup>122</sup> Nongonococcal urethritis (NGU) accounts for around 80%–95% of the total cases caused by a variety of microorganisms with emerging drug resistance, and the NGU treatment should ideally be guided by etiologic diagnosis. The primary treatment is azithromycin or doxycycline. For patients with macrolide-resistant MG infections, moxifloxacin is the only treatment option.<sup>123</sup> Unfortunately, AIDS is a risk factor for urethritis, and urethritis could act as a local source of HIV that can be reversibly activated to increase HIV transmission.<sup>104,124,125</sup> This interaction significantly increases the difficulty of treating urethritis in MPXV-HIV coinfecting patients, highlighting that ART and antibiotic therapy must be performed simultaneously.

## Penile Lesions

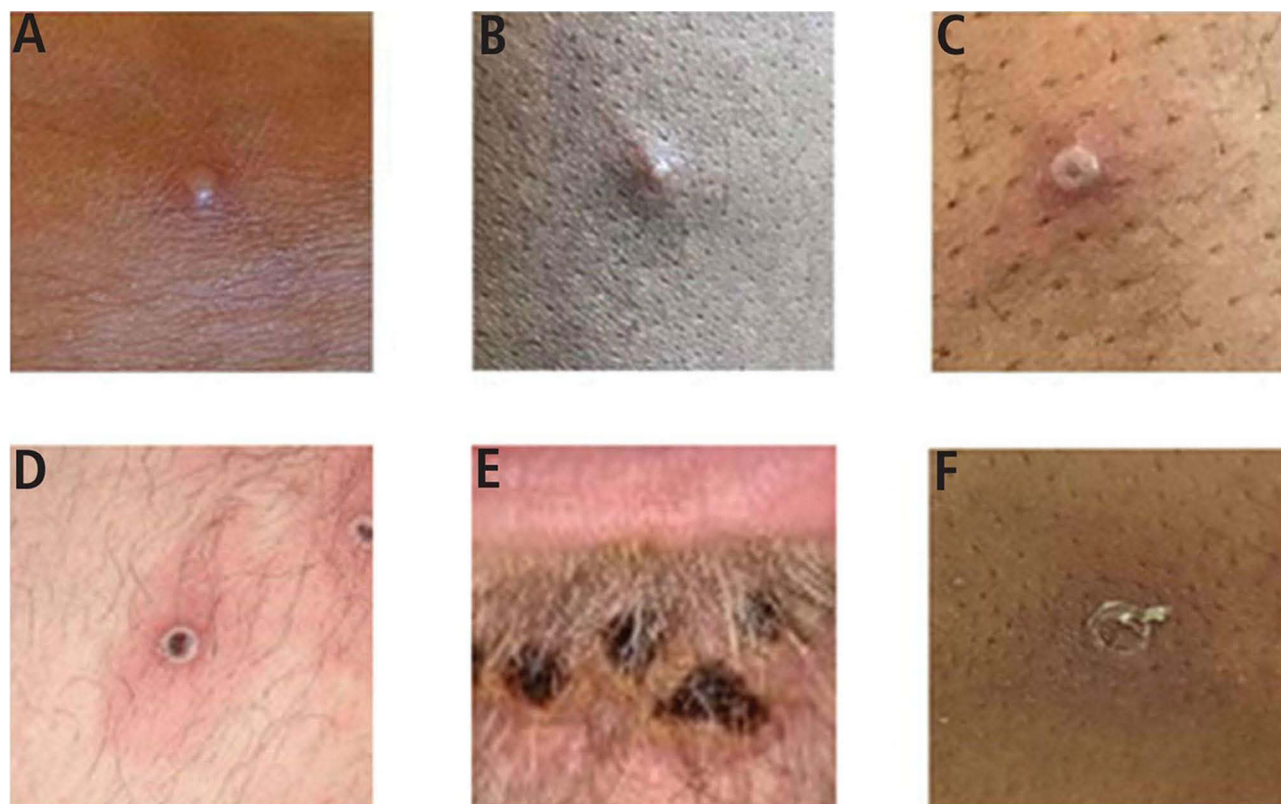
### Epidemiology Data

Unlike the other three urogenital complications mentioned above, penile lesions (PLs) are quite common. Skin lesions in the anogenital area occurred in more than 70% (383/582) of the included cases in the multi-center cohort,<sup>2</sup> which echoes the results from other case-series.<sup>10,66,126</sup> In a retrospective case-control study, MPXV infection was associated with a greater risk of genital rash compared to healthy individuals (OR = 5.38, 95% CI: 2.57–11.23). A descriptive case series

in Spain of 14 patients described the natural course of PLs, 43% (6/14) sought consultation for urogenital symptomatology due to penile edema (PE) as the initial presentation.<sup>19</sup> Another large-scale study in Brazil included 10,169 cases, and 22.4% (2280/10169) had PLs, mainly PE.<sup>127</sup> Lee et al investigated the clinical features with intermediate follow-up with PLs and reported that a large portion of (16/68) patients experienced significant penile skin changes at the final follow-up.<sup>36</sup> A meta-analysis indicated that the pooled prevalence of PE or scrotal edema was 10.7% (95% CI: 6.3%–17.7%), accounting for the majority of genital lesions.<sup>128</sup> Moreover, penile ulcers (PUs) have been reported by various case reports but lack data from cohort studies or case series.<sup>66,129–132</sup> Additionally, penile lymphoedema was found in two cases, which added mpox as a cause of multiple PLs.<sup>133</sup>

## Potential Mechanism

The definition of PLs is mainly based on gross images and symptoms since PLs have a characteristic appearance with umbilicated lesions that are often ulcerated and painful (see the typical images in<sup>134</sup>), but it could lead to a poor understanding of pathogenesis and significant uncertainty of pathological heterogeneity.<sup>36,65</sup> PLs are widely considered to be caused by a single skin rash, the most representative manifestation in mpox, and are usually accompanied by bacterial superinfection.<sup>10</sup> The skin rash is divided into six stages: macule, papule, vesicle, pustule, crust, and scab<sup>1,18,135</sup> (Figure 5). In the vesicular stage, histopathological examination showed significant spongiosis, cutaneous edema, acute inflammation, and ballooning keratinocyte degeneration. Apoptotic keratinocyte debris and inflammatory cells predominate at the pustule stage, with a small number of viable keratinocytes being present. Both multinucleation and cytopathic damage, characterized by eosinophilic inclusion bodies, conspicuous nucleoli, and so-called ground glass chromatin, are possible in viable keratinocytes.<sup>4,136</sup> In addition, the deeper involvement of the dermal layers markedly increases the severity of infection and the risk of bacterial superinfection.<sup>36</sup> Moreover, penile lymphoedema is possibly caused by lymphatic congestion because of pronounced lymphadenopathy, which is consistent with the dispersal process



**Figure 5** The six stages of skin lesions in Mpox (A) early vesicle, (B) small pustule, (C) umbilicated pustule, (D) ulcerated lesion, (E) crusted mature lesions under the lower lip, and (F) partially removed scab.

of MPXV in the body.<sup>20,133</sup> The pathological test showed the same histological alterations in the PUs from the case of penile lymphoedema, implicating that penile lymphoedema is an accompanying symptom of common PLs rather than a new disorder.<sup>133</sup> Surprisingly, the influence of AIDS on PLs remains controversial. Lee et al found that the PL rates were not significantly different between those with and without AIDS ( $p = 0.12$ ), which contrasts to other cohorts.<sup>36,137</sup> The role of AIDS in PLs warrants further research in larger cohorts.

**Note:** SOURCE: Photo credit: UK Health Security Agency.

## Management

Urologists and andrologists must understand the presentation, diagnosis, and management of PLs, as many patients first visit a urology or andrology specialist clinic for their penile concern. PLs are usually not life-threatening but are a warning sign of small-scale transmission of mpox, which means that clinicians should comprehensively inquire about their history, including sexual contact, vaccination, and AIDS status, and complete differential diagnosis with other STIs exhibiting similar skin lesions by cooperating with dermatologists and infectious disease specialists, and report a public health emergency.<sup>36,127,138</sup> Most management of PLs is symptomatic treatment. Pain in PLs is frequently reported in patients. Acetaminophen, NSAIDs, and topical lidocaine were the most common analgesia regimens. When treating individuals with severe refractory pain, opioid medications should be administered sparingly.<sup>1</sup> When cellulitis or subsequent bacterial infections are suspected or verified by local lesion cultures, oral and topical antibiotic therapies are used.<sup>1,36,129</sup> The effectiveness of antibiotic regimens containing levofloxacin, trimethoprim-sulfamethoxazole, and cephalosporins has been confirmed.<sup>11,36</sup> Griffiths et al reported a remarkable improvement in 1 case with genital ulcers after antibiotherapy with doxycycline, with resolution of fever and lymphadenopathy reduction.<sup>139</sup> Similar success was also achieved in a case treated with doxycycline for suspected rickettsial infection, and the patient presented fever resolution within the first 24 h of treatment.<sup>140</sup> The natural evolution of mpox, the anti-inflammatory effects of doxycycline, or an unidentified mechanism could all account for this clinical improvement. Additionally, topical corticosteroids, primarily medium-potency corticosteroids such as betamethasone or methylprednisolone, were given to ulcerated lesions with a notable inflammatory component.<sup>138</sup> Sepsis is rare but critical in mpox patients with only one record to date.<sup>36</sup> Early clearance of infected lesions and the use of effective antibiotics constitute the core, and supportive therapy aimed at maintaining organ functions, including circulatory resuscitation, mechanical ventilation, renal replacement, and immunomodulatory therapy targeting therapeutic modalities affecting the immune-inflammatory response, can lead to a more favorable prognosis. The participation of the intensive care unit is important.<sup>36,141,142</sup> Patients with deep or necrotic skin lesions should receive medical debridement therapy via collagenase.<sup>36</sup> Surgical intervention should be used only for purulent collections incised and drained or for penile surgical exploration, and only a very small number of cases receive a surgical approach.<sup>10,19,36</sup> In addition to symptomatic supportive treatment, tecovirimat has been applied in mpox patients with PLs and has shown satisfactory efficacy.<sup>19,130,143</sup> Referrals to infectious disease specialists should be made to assess therapeutic eligibility for tecovirimat.<sup>36</sup> PLs can recover without specific treatment such as tecovirimat, which implies that the need for tecovirimat use requires repeated consideration.<sup>129</sup> However, the limited availability of tecovirimat is another concern for mpox management, and alternatives are urgently needed. A prospective cohort showed that patients treated with topical cidofovir obtained faster resolution of lesions than those not treated with cidofovir ( $p = 0.019$ ), recommending topical cidofovir as a potential treatment for PLs.<sup>144</sup> Treatment strategies for PLs are now well established and effective but still lack standardization. Hence, experience derived from successful treatment cases still needs to be validated.

## Future Challenges, Perspectives, and Public Implications

On 11 May 2023, the WHO declared that the 2022–2023 mpox epidemic was no longer an international public health emergency. However, the end of emergence does not mean the end of the recognition and exploration of this reemergent disease.<sup>145</sup> In contrast, scientists have put more effort into mpox research. First, the early diagnosis of mpox is essential for patient therapy and rapidly blocks further mpox transmission. Clinical definitions may not distinguish between other viral rashes, such as varicella, and have shown low specificity for mpox.<sup>146</sup> Case definitions were revised in response to case series detailing the changing clinical presentation after it became clear during the worldwide outbreak that they did

not identify modern mpox presentations.<sup>1</sup> This fact continued emphasis on laboratory-based diagnostics is much warranted.<sup>146</sup> However, even though PCR tests are now the mainstay for confirming mpox in high- and middle-income countries, false negative results, time, and economic cost maintain the value of the clinical presentation-based diagnosis of mpox, particularly in low-income countries.<sup>61,147,148</sup> Standard guidelines for tentative mpox diagnosis are much needed for urologists and dermatologists.<sup>64,65</sup> Some key features used to distinguish mpox have been published in *European Urology*, and advice for protecting against possible occupational exposure was also proposed, which can serve as a preliminary guideline, but improvements are urgently needed.<sup>65</sup> Using the combinations of personal information and clinical presentations to detect mpox is promising with the development of artificial intelligence, deep learning, and machine learning.<sup>149–151</sup> Second, although mpox is a self-limiting disease and organ complications are considered secondary to mpox, the model by Li et al reveals this potentially enormous risk by the direct organ invasion by MPXV, especially for the urogenital system, which is the most common route of infection.<sup>71</sup> The basic mechanism is worth researching further. It is not advisable to rely exclusively on antiviral medications, even though some of them, such as tecovirimat, have been clinically shown to be effective with few side effects.<sup>1,20</sup> Even though MPXV is a member of the DNA virus family, its elevated SNPs cause it to show noticeably greater genomic diversity. Raised worldwide travel and rapid population movement have made it easier for mpox to spread continuously, which has increased the mutation possibility. The increased variability, drug resistance, and the emergence of multidrug-resistant MPXV are all caused by these factors.<sup>1,5,20,152</sup> Furthermore, some restrictions on existing medications prevent them from being used in clinical settings. For instance, tecovirimat is not widely available in some areas, cidofovir has a low bioavailability and might cause renal damage, and both cidofovir and brincidofovir may harm hematological and hepatic functions. These factors all call for the creation of new drugs.<sup>20,138</sup> Fortunately, some emerging technologies, such as artificial intelligence, high-throughput screening, and multi-omics strategy, greatly increase confidence in drug development.<sup>153–155</sup> Existing drug targets and their mechanisms have been reviewed in.<sup>20</sup> For the therapeutic drugs in PWH, some potential targets have been discovered by bioinformatic analysis.<sup>54</sup> Moreover, although the anti-viral drugs are the crux of mpox management, the treatment for complications and the integrative management for patients are of importance for the long-term prognosis.<sup>36,138,142</sup> Guerrero et al proposed a multidisciplinary team (MDT) approach for mpox, which included dermatologists and experts in infectious diseases, emergency medicine, and preventive medicine, is encouraging because it enhances the capacity to identify and treat the condition early with supportive, topical, and systemic treatment.<sup>138</sup> In adequately staffed hospitals, such MDTs deserve consideration, and urologists are strongly encouraged to join the team. Furthermore, psychological and social support is imperative but usually ignored, especially for patients suffering from PLs, since PLs are usually considered taboo.<sup>36,142,156,157</sup> Appropriate and sufficient cosmic and psychological care can significantly reduce the psychological burden of patients after they have recovered. The elimination of the stigma and discrimination against mpox patients is also a great task, which requires the combined efforts of clinicians and social advocates.<sup>158,159</sup> Finally, prevention is critical, particularly in high-risk groups such as MSM with HIV and in locations where mpox transmission is active. Immunization is a successful method of preventing mpox. The vaccinia vaccination may provide some protection against MPXV infection, according to studies. However, because of the possible hazards to immunocompromised patients, especially PWH and SOTRs, the use of smallpox vaccines for MPXV prophylaxis in epidemic locations is restricted.<sup>20,48,160</sup> Live replicating vaccinia virus vaccinations, such as the first-generation Dryvax and second-generation ACAM-2000 vaccines, can result in serious diseases such as progressive vaccinia.<sup>161,162</sup> PWH are safe for the third-generation vaccination, JYNNEOS, a non-replicating vaccinia vaccine that can prevent mpox cases and reduce the severity of sickness.<sup>163,164</sup> Some newly designed vaccines, including mRNA vaccines and immunogen-based vaccines, have demonstrated better virus neutralization than conventional live attenuated vaccines in mouse models and are waiting to be tested in clinical trials.<sup>165–167</sup> However, the availability of effective vaccines is the next problem that must be faced.

Although the number of mpox cases has declined drastically, the global mpox outbreak underscores the lack of surveillance, investment, and research into this emerging infection. According to the 2022 outbreak, mpox occupied an ecological niche allowing for quick spread through dense sexual networks. International travel, participating in large events, immune system dysfunction, and close physical or sexual contact with a large number of sexual partners may have contributed to the mpox transmission in MSM. The quick containment of the subsequent outbreak was potentially facilitated

by identifying of these risk factors and the public health propaganda and education, vaccination, immunoregulation, and behavior modification.<sup>1</sup> The precise detection of the population at risk can achieve better medical resource allocation and patients' management. In fact, the epidemiology evidence and behind mechanisms have powerfully illustrated that mpox will no longer be a regional disease, the globalized transmission is inevitable.<sup>27</sup> With the advent of globalization, collaborations are essential in mpox management both nationally and internationally, including supporting disease response (eg, disease surveillance, drug and vaccine accessibility, and crisis communication), enhancing laboratory capacity (eg, effective diagnostic approaches, the establishment of laboratory networks), and scientific research (eg, exploring mpox epidemiology, transmission dynamics, and pathogenesis, drug and vaccine design, and the international sharing of research advances).<sup>1,58</sup>

## Conclusion

Mpox can lead to various urogenital lesions, most of which are self-limiting with a good prognosis. However, until more research has been released, it might be too soon to make such recommendations. Current researches on mpox focus primarily on clinical descriptions and lack a deeper understanding of the fundamental mechanisms, which disables us from being optimistic about another potential reemergence in the future, even though mpox is usually not life-threatening. Such a pandemic still poses a substantial threat that cannot be neglected; instead, it is supposed to be a “mystery”, especially after learning the lessons from the COVID-19 havoc. The fact that mpox is often characterized by urogenital manifestations as the first symptom emphasizes the important role of urologists and andrologists in the management of mpox epidemics. To respond in cases of severe disease, clinicians should regularly monitor patients and be aware of the possibility of developing these urogenital events.

## Abbreviations

MPXV, Mpox virus; WHO, World Health Organization; MSM, Men who have sex with men; EM, Electron microscopy; SNP, Single nucleotide polymorphism; HHT, Human-to-human transmission; VT, Vertical transmission; STI, Sexually transmitted infection; IgM/G, Immunoglobulin M/G; PWH, People with HIV; SOTR, Solid organ transplant recipient; OR, Odds ratio; AID, Autoimmune disease; PCR, Polymerase chain reaction; AKI, Acute kidney injury; sCr, Serum creatine; HKO, Human kidney organoid; ART, Antiretroviral therapy; MOF, Multiple organ failure; AUR, Acute urine retention; UTI, Urinary tract infection; BPH, Benign prostate hyperplasia; PL, Penile lesion; PE, Penile edema.

## Data Sharing Statement

All information obtained by the authors in this manuscript can be found in the references.

## Acknowledgment

We thank all authors in this manuscript.

## Author Contributions

All authors made a significant contribution to the work reported, whether that is in the conception, study design, execution, acquisition of data, analysis and interpretation, or in all these areas; took part in drafting, revising or critically reviewing the article; gave final approval of the version to be published; have agreed on the journal to which the article has been submitted; and agree to be accountable for all aspects of the work.

## Funding

There is no funding to report.

## Disclosure

The authors declare that they have no competing interests.



## References

1. Thornhill JP, Gandhi M, Orkin CM. The Reemergence of an Old Disease and Inequities. *Annu Rev Med*. 2024;75(1):159–175. doi:10.1146/annurev-med-080122-030714
2. Thornhill JP, Barkati S, Walmsley S, et al. Monkeypox Virus Infection in Humans across 16 Countries — April–June 2022. *N Engl J Med*. 2022;387(8):679–691. doi:10.1056/NEJMoa2207323
3. Sabeena S. The changing epidemiology of monkeypox and preventive measures: an update. *Arch Virol*. 2023;168(1):31. doi:10.1007/s00705-022-05677-3
4. Mitjà O, Ogoina D, Titanji BK, et al. Monkeypox. *Lancet*. 2023;401(10370):60–74. doi:10.1016/S0140-6736(22)02075-X
5. Hirani R, Noruzi K, Iqbal A, et al. A Review of the Past, Present, and Future of the Monkeypox Virus: challenges, Opportunities, and Lessons from COVID-19 for Global Health Security. *Microorganisms*. 2023;11(11):2713. doi:10.3390/microorganisms11112713
6. Kane M, Golovkina T. Common threads in persistent viral infections. *J Virol*. 2010;84(9):4116–4123. doi:10.1128/JVI.01905-09
7. Reda A, Dhama K. Mpox impact on different organ systems: complications, mechanisms, and management. *Rev Med Virol*. 2023;33(4):e2443. doi:10.1002/rmv.2443
8. Benites-Zapata VA, Ulloque-Badaracco JR, Alarcon-Braga EA, et al. Clinical features, hospitalisation and deaths associated with monkeypox: a systematic review and meta-analysis. *Ann Clin Microbiol Antimicrob*. 2022;21(1):36. doi:10.1186/s12941-022-00527-1
9. Okoli GN, Van Caeselele P, Askin N, Abou-Setta AM. Comparative evaluation of the clinical presentation and epidemiology of the 2022 and previous Mpox outbreaks: a rapid review and meta-analysis. *Infect Dis (Lond)*. 2023;55(7):490–508. doi:10.1080/23744235.2023.2214609
10. Patel A, Bilinska J, Tam JCH, et al. Clinical features and novel presentations of human monkeypox in a central London centre during the 2022 outbreak: descriptive case series. *BMJ*. 2022;378:e072410. doi:10.1136/bmj-2022-072410
11. Girometti N, Byrne R, Bracchi M, et al. Demographic and clinical characteristics of confirmed human monkeypox virus cases in individuals attending a sexual health centre in London, UK: an observational analysis. *Lancet Infect Dis*. 2022;22(9):1321–1328. doi:10.1016/S1473-3099(22)00411-X
12. Angelo KM, Smith T, Camprubi-Ferrer D, et al. Epidemiological and clinical characteristics of patients with monkeypox in the GeoSentinel Network: a cross-sectional study. *Lancet Infect Dis*. 2023;23(2):196–206. doi:10.1016/S1473-3099(22)00651-X
13. Tarin-Vicente EJ, Alemany A, Agud-Dios M, et al. Clinical presentation and virological assessment of confirmed human monkeypox virus cases in Spain: a prospective observational cohort study. *Lancet*. 2022;400(10353):661–669. doi:10.1016/S0140-6736(22)01436-2
14. Thornhill JP, Palich R, Ghosn J, et al. Human monkeypox virus infection in women and non-binary individuals during the 2022 outbreaks: a global case series. *Lancet*. 2022;400(10367):1953–1965. doi:10.1016/S0140-6736(22)02187-0
15. Palich R, Burrell S, Monsel G, et al. Viral loads in clinical samples of men with monkeypox virus infection: a French case series. *Lancet Infect Dis*. 2023;23(1):74–80. doi:10.1016/S1473-3099(22)00586-2
16. Lapa D, Carletti F, Mazzotta V, et al. Monkeypox virus isolation from a semen sample collected in the early phase of infection in a patient with prolonged seminal viral shedding. *Lancet Infect Dis*. 2022;22(9):1267–1269. doi:10.1016/S1473-3099(22)00513-8
17. Peiró-Mestres A, Fuertes I, Camprubi-Ferrer D, et al. Frequent detection of monkeypox virus DNA in saliva, semen, and other clinical samples from 12 patients. *Euro Surveill*. 2022;27(28):2200503. doi:10.2807/1560-7917.ES.2022.27.28.2200503
18. Ogoina D, Damon I, Nakoune E. Clinical review of human mpox. *Clin Microbiol Infect*. 2023;29(12):1493–1501. doi:10.1016/j.cmi.2023.09.004
19. Gomez-Garberi M, Sarrio-Sanz P, Martinez-Cayuelas L, et al. Genitourinary Lesions Due to Monkeypox. *Europ urol*. 2022;82(6):625–630. doi:10.1016/j.eururo.2022.08.034
20. Lu J, Xing H, Wang C, et al. Mpox (formerly monkeypox): pathogenesis, prevention, and treatment. *Sig Transduct Target Ther*. 2023;8(1):458. doi:10.1038/s41392-023-01675-2
21. Andrei G, Snoeck R. Differences in pathogenicity among the mpox virus clades: impact on drug discovery and vaccine development. *Trends Pharmacol Sci*. 2023;44(10):719–739. doi:10.1016/j.tips.2023.08.003
22. Americo JL, Earl PL, Moss B. Virulence differences of mpox (monkeypox) virus clades I, IIa, and IIb.1 in a small animal model. *Proc Natl Acad Sci U S A*. 2023;120(8):e2220415120. doi:10.1073/pnas.2220415120
23. Orassay A, Berdigiyliev A, Sadvokassova D, et al. Recent advances on human mpox. *New Microbes and New Infections*. 2023;51:101066. doi:10.1016/j.nmni.2022.101066
24. Isidro J, Borges V, Pinto M, et al. Phylogenomic characterization and signs of microevolution in the 2022 multi-country outbreak of monkeypox virus. *Nat Med*. 2022;28(8):1569–1572. doi:10.1038/s41591-022-01907-y
25. Ndodo N, Ashcroft J, Lewandowski K, et al. Distinct monkeypox virus lineages co-circulating in humans before 2022. *Nat Med*. 2023;29(9):2317–2324. doi:10.1038/s41591-023-02456-8
26. Gigante CM, Korber B, Seabolt MH, et al. Multiple lineages of monkeypox virus detected in the United States, 2021–2022. *Science*. 2022;378(6619):560–565. doi:10.1126/science.add4153
27. O'Toole Á, Neher RA, Ndodo N, et al. APOBEC3 deaminase editing in mpox virus as evidence for sustained human transmission since at least 2016. *Science*. 2023;382(6670):595–600. doi:10.1126/science.adg8116
28. Li K, Yuan Y, Jiang L, Liu Y, Liu Y, Zhang L. Animal host range of mpox virus. *J Med Virol*. 2023;95(2):e28513. doi:10.1002/jmv.28513
29. Moss B. Understanding the biology of monkeypox virus to prevent future outbreaks. *Nat Microbiol*. 2024;9(6):1408–1416. doi:10.1038/s41564-024-01690-1
30. Venkatesan P. Monkeypox transmission-what we know so far. *Lancet Respir Med*. 2022;10(11):e101. doi:10.1016/S2213-2600(22)00386-1
31. Beeson A, Styczynski A, Hutson CL, et al. Mpox respiratory transmission: the state of the evidence. *Lancet Microbe*. 2023;4(4):e277–e283. doi:10.1016/S2666-5247(23)00034-4
32. Dashraath P, Nielsen-Saines K, Mattar C, Musso D, Tambyah P, Baud D. Guidelines for pregnant individuals with monkeypox virus exposure. *Lancet*. 2022;400(10345):21–22. doi:10.1016/S0140-6736(22)01063-7
33. Allan-Blitz LT, Gandhi M, Adamson P, Park I, Bolan G, Klausner JD. A Position Statement on Mpox as a Sexually Transmitted Disease. *Clin Infect Dis*. 2023;76(8):1508–1512. doi:10.1093/cid/ciac960

34. Huhn GD, Bauer AM, Yorita K, et al. Clinical characteristics of human monkeypox, and risk factors for severe disease. *Clin Infect Dis.* 2005;41(12):1742–1751. doi:10.1086/498115
35. Tree JA, Hall G, Pearson G, et al. Sequence of pathogenic events in cynomolgus macaques infected with aerosolized monkeypox virus. *J Virol.* 2015;89(8):4335–4344. doi:10.1128/JVI.03029-14
36. Lee J, McLean J, Zucker J, Brandes S, Joice G. Mpox Genital Lesions: a Large Single-center Experience With Intermediate Follow-up. *J Urol.* 2023;210(3):510–516. doi:10.1097/JU.0000000000003579
37. Agrati C, Cossarizza A, Mazzotta V, et al. Immunological signature in human cases of monkeypox infection in 2022 outbreak: an observational study. *Lancet Infect Dis.* 2023;23(3):320–330. doi:10.1016/S1473-3099(22)00662-4
38. Li H, Huang QZ, Zhang H, et al. The land-scape of immune response to monkeypox virus. *EBioMedicine.* 2023;87:104424. doi:10.1016/j.ebiom.2022.104424
39. Karem KL, Reynolds M, Hughes C, et al. Monkeypox-induced immunity and failure of childhood smallpox vaccination to provide complete protection. *Clin Vaccine Immunol.* 2007;14(10):1318–1327. doi:10.1128/CDVI.00148-07
40. Hammarlund E, Dasgupta A, Pinilla C, Norori P, Früh K, Slifka MK. Monkeypox virus evades antiviral CD4+ and CD8+ T cell responses by suppressing cognate T cell activation. *Proc Natl Acad Sci U S A.* 2008;105(38):14567–14572. doi:10.1073/pnas.0800589105
41. Johnston SC, Johnson JC, Stonier SW, et al. Cytokine modulation correlates with severity of monkeypox disease in humans. *J Clin Virol.* 2015;63:42–45. doi:10.1016/j.jcv.2014.12.001
42. Edghill-Smith Y, Golding H, Manischewitz J, et al. Smallpox vaccine-induced antibodies are necessary and sufficient for protection against monkeypox virus. *Nat Med.* 2005;11(7):740–747. doi:10.1038/nm1261
43. Rimoin AW, Mulembakani PM, Johnston SC, et al. Major increase in human monkeypox incidence 30 years after smallpox vaccination campaigns cease in the Democratic Republic of Congo. *Proc Natl Acad Sci U S A.* 2010;107(37):16262–16267. doi:10.1073/pnas.1005769107
44. Fuller T, Thomassen HA, Mulembakani PM, et al. Using remote sensing to map the risk of human monkeypox virus in the Congo Basin. *Ecohealth.* 2011;8(1):14–25. doi:10.1007/s10393-010-0355-5
45. Copen CE, Delaney KP, Agnew-Brune C, et al. Modifications to Sexual Behaviors Associated With Mpox (Monkeypox) Virus Transmission Among Persons Presenting for mpox Vaccination, 2022. *Sex Transm Dis.* 2024;51(1):54–60. doi:10.1097/OLQ.0000000000001889
46. Hoffmann C, Jessen H, Wyen C, et al. Clinical characteristics of monkeypox virus infections among men with and without HIV: a large outbreak cohort in Germany. *HIV Med.* 2023;24(4):389–397. doi:10.1111/hiv.13378
47. Maan I, Kohli M, Gilson R. Mpox in people living with HIV. *Curr Opin Infect Dis.* 2024;37(1):1–7. doi:10.1097/QCO.0000000000000994
48. Higgins E, Ranganath N, Mehkri O, et al. Clinical features, treatment, and outcomes of mpox in solid organ transplant recipients: a multicenter case series and literature review. *Am J Transplant.* 2023;23(12):1972–1979. doi:10.1016/j.ajt.2023.07.016
49. Yinka-Ogunleye A, Aruna O, Dalhat M, et al. Outbreak of human monkeypox in Nigeria in 2017–18: a clinical and epidemiological report. *Lancet Infect Dis.* 2019;19(8):872–879. doi:10.1016/S1473-3099(19)30294-4
50. de Oliveira-Júnior JM, Tenório MDL, Santos Caduda S D, Santana RRR, Martins-Filho PR. Reasons for hospitalization of patients with monkeypox: a quantitative evidence synthesis. *Infection.* 2023;51(3):789–791. doi:10.1007/s15010-022-01937-1
51. Zhao B, Liu Q, Du Q, et al. Characteristics and Differences in Mpox Patients with and without HIV Infection: a Retrospective Cross-Sectional Study in Chengdu, China. *IJGM.* 2024;17:1381–1393. doi:10.2147/IJGM.S456198
52. Traut CC, Jones JL, Sanders RA, et al. Orthopoxvirus-Specific T-Cell Responses in Convalescent Mpox Patients. *J Infect Dis.* 2024;229(1):54–58. doi:10.1093/infdis/jiad245
53. Sigler R, Haidar G. Mpox in immunocompromised patients: with more data, more questions. *Transplant Infectious Dis.* 2023;25(1):e14023. doi:10.1111/tid.14023
54. Li J, Hao Y, Wu L, et al. Exploration of common pathogenesis and candidate hub genes between HIV and monkeypox co-infection using bioinformatics and machine learning. *Sci Rep.* 2024;14(1):26701. doi:10.1038/s41598-024-78540-x
55. Boldrini VO, Damasceno A, Yasuda CL. Monkeypox in Multiple Sclerosis patients: should we be alert? *Mult Scler Relat Disord.* 2022;67:104228. doi:10.1016/j.msard.2022.104228
56. Alissa M, Alghamdi A, Alghamdi SA. Overview of reemerging mpox infection with a focus on neurological manifestations. *Rev Med Virol.* 2024;34(2):e2527. doi:10.1002/rmv.2527
57. Patel M, Adnan M, Aldarhami A, et al. Current Insights into Diagnosis, Prevention Strategies, Treatment, Therapeutic Targets, and Challenges of Monkeypox (Mpox) Infections in Human Populations. *Life.* 2023;13(1):249. doi:10.3390/life13010249
58. Branda F, Romano C, Ciccozzi M, et al. Mpox: an Overview of Pathogenesis, Diagnosis, and Public Health Implications. *JCM.* 2024;13(8):2234. doi:10.3390/jcm13082234
59. Zhou Y, Chen Z. Mpox: a review of laboratory detection techniques. *Arch Virol.* 2023;168(8):221. doi:10.1007/s00705-023-05848-w
60. Hong KH, Kim GJ, Roh KH, et al. Guidelines for the Laboratory Diagnosis of Monkeypox in Korea. *Ann Lab Med.* 2023;43(2):137–144. doi:10.3343/alm.2023.43.2.137
61. da SSJR, Kohl A, Pena L, Pardee K. Clinical and laboratory diagnosis of monkeypox (mpox): current status and future directions. *iScience.* 2023;26(6):106759. doi:10.1016/j.isci.2023.106759
62. Dubois ME, Hammarlund E, Slifka MK. Optimization of peptide-based ELISA for serological diagnostics: a retrospective study of human monkeypox infection. *Vector Borne Zoonotic Dis.* 2012;12(5):400–409. doi:10.1089/vbz.2011.0779
63. Cowen EW, Tkaczyk ER, Norton SA, Leslie KS. Mpox-A Rapidly Evolving Disease. *JAMA Dermatol.* 2023;159(4):424–431. doi:10.1001/jamadermatol.2023.0041
64. Gupta AK, Talukder M, Rosen T, Differential Diagnosis PV. Prevention, and Treatment of mpox (Monkeypox): a Review for Dermatologists. *Am J Clin Dermatol.* 2023;24(4):541–556. doi:10.1007/s40257-023-00778-4
65. Yu Z, Zhu B, Qiu Q, Ding N, Wu H, Shen Z. Genitourinary Symptoms Caused by Monkeypox Virus: what Urologists Should Know. *Europ urol.* 2023;83(2):180–182. doi:10.1016/j.eururo.2022.11.005
66. Hamid TA, Elmekresh A, Parkar AZ, Al Masri MM, Saeedi Y. Male genital lesions in monkeypox virus infection: a case series. *Can J Urol.* 2023;30(3):11562–11567.
67. Kellum JA, Romagnani P, Ashuntantang G, Ronco C, Zarbock A, Anders HJ. Acute kidney injury. *Nat Rev Dis Primers.* 2021;7(1):52. doi:10.1038/s41572-021-00284-z

68. Kalim S, Szczech LA, Wyatt CM Acute Kidney Injury in HIV-Infected Patients.
69. Turgut F, Awad AS, Abdel-Rahman EM. Acute Kidney Injury: medical Causes and Pathogenesis. *J Clin Med.* **2023**;12(1):375. doi:10.3390/jcm12010375
70. Reis T, de Assis Rocha Neves F, Fagundes A, et al. Monkeypox-Associated Acute Kidney Injury and Foreseeable Impacts on Nephrology and Kidney Transplantation Services. *Blood Purif.* **2023**;52(4):319–322. doi:10.1159/000528041
71. Li P, Du Z, Lamers MM, et al. Mpox virus infects and injures human kidney organoids, but responding to antiviral treatment. *Cell Discov.* **2023**;9(1):34. doi:10.1038/s41421-023-00545-z
72. McFadden G. Poxvirus tropism. *Nat Rev Microbiol.* **2005**;3(3):201–213. doi:10.1038/nrmicro1099
73. Taguchi A, Nishinakamura R. Higher-Order Kidney Organogenesis from Pluripotent Stem Cells. *Cell Stem Cell.* **2017**;21(6):730–746.e6. doi:10.1016/j.stem.2017.10.011
74. Kwiatkowska E, Domański L, Dziedzicko V, Kajdy A, Stefańska K, Kwiatkowski S. The Mechanism of Drug Nephrotoxicity and the Methods for Preventing Kidney Damage. *Int J Mol Sci.* **2021**;22(11):6109. doi:10.3390/ijms22116109
75. Bruno G, Buccoliero GB. Antivirals against Monkeypox (Mpox) in Humans: an Updated Narrative Review. *Life.* **2023**;13(10):1969. doi:10.3390/life13101969
76. Stern A, Alonso CD, Garcia-Vidal C, et al. Safety and efficacy of intravenously administered cidofovir in adult haematopoietic cell transplant recipients: a retrospective multicentre cohort study. *J Antimicrob Chemother.* **2021**;76(11):3020–3028. doi:10.1093/jac/dkab259
77. Vo C, Zomorodi R, Silvera R, et al. Clinical Characteristics and Outcomes of Patients With Mpox Who Received Tecovirimat in a New York City Health System. *Open Forum Infect Dis.* **2023**;10(11):ofad552. doi:10.1093/ofid/ofad552
78. Gameiro J, Agapito Fonseca J, Jorge S, Lopes J. Acute kidney injury in HIV -infected patients: a critical review. *HIV Medicine.* **2019**;20(2):77–87. doi:10.1111/hiv.12685
79. Cohen SD, Chawla LS, Kimmel PL. Acute kidney injury in patients with human immunodeficiency virus infection. *Current Opinion in Critical Care.* **2008**;14(6):647–653. doi:10.1097/MCC.0b013e3283186f43
80. Dellepiane S, Leventhal JS, Cravedi P. T Cells and Acute Kidney Injury: a Two-Way Relationship. *Front Immunol.* **2020**;11:1546. doi:10.3389/fimmu.2020.01546
81. Li Y, Shlipak MG, Grunfeld C, Choi AI. Incidence and risk factors for acute kidney injury in HIV Infection. *Am J Nephrol.* **2012**;35(4):327–334. doi:10.1159/000337151
82. Atta MG, De Seigneux S, Lucas GM. Clinical Pharmacology in HIV Therapy. *CJASN.* **2019**;14(3):435–444. doi:10.2215/CJN.02240218
83. Jafari A, Khalili H, Dashti-Khavidaki S. Tenofovir-induced nephrotoxicity: incidence, mechanism, risk factors, prognosis and proposed agents for prevention. *Eur J Clin Pharmacol.* **2014**;70(9):1029–1040. doi:10.1007/s00228-014-1712-z
84. Mitjå O, Alemany A, Marks M, et al. Mpox in people with advanced HIV infection: a global case series. *Lancet.* **2023**;401(10380):939–949. doi:10.1016/S0140-6736(23)00273-8
85. Ostermann M, Zarbock A, Goldstein S, et al. Recommendations on Acute Kidney Injury Biomarkers From the Acute Disease Quality Initiative Consensus Conference: a Consensus Statement. *JAMA Network Open.* **2020**;3(10):e2019209. doi:10.1001/jamanetworkopen.2020.19209
86. Gupta SK, Post FA, Arribas JR, et al. Renal safety of tenofovir alafenamide vs. tenofovir disoproxil fumarate: a pooled analysis of 26 clinical trials. *AIDS.* **2019**;33(9):1455–1465. doi:10.1097/QAD.0000000000002223
87. Hill A, Hughes SL, Gotham D, Pozniak AL. Tenofovir alafenamide versus tenofovir disoproxil fumarate: is there a true difference in efficacy and safety? *J Virus Erad.* **2018**;4(2):72–79.
88. Peerapornratana S, Manrique-Caballero CL, Gómez H, Kellum JA. Acute kidney injury from sepsis: current concepts, epidemiology, pathophysiology, prevention and treatment. *Kidney Int.* **2019**;96(5):1083–1099. doi:10.1016/j.kint.2019.05.026
89. Wang AY, Bellomo R. Renal replacement therapy in the ICU: intermittent hemodialysis, sustained low-efficiency dialysis or continuous renal replacement therapy? *Curr Opin Crit Care.* **2018**;24(6):437–442. doi:10.1097/MCC.0000000000000541
90. Fitzpatrick JM, Kirby RS. Management of acute urinary retention. *BJU Int.* **2006**;97(2):16–20. doi:10.1111/j.1464-410X.2006.06100.x
91. Attieh RM, Brumble L, Elwasila SM, Wade HM. Disseminated Monkeypox Infection in a Kidney Transplant Recipient: a Case Report. *Transplant Proc.* **2023**;55(3):667–671. doi:10.1016/j.transproceed.2023.02.031
92. Hackett N, Narayan P, Huf S. Mpox (monkeypox) causing penile lesions and acute urinary retention. *BMJ Case Rep.* **2023**;15(12):e252696. doi:10.1136/bcr-2022-252696
93. Onukak AE, Nga CN, Ubani BC, Umoinek E, Umoette N. Mpox and Chicken Pox Coinfection Complicated by Acute Urinary Retention: a Case Report. *West Afr J Med.* **2023**;40(8):873–876.
94. Nazarko L. Acute urinary retention: patient investigations and treatments. *Br J Nurs.* **2021**;30(9):S4–S7. doi:10.12968/bjon.2021.30.9.S4
95. Selius BA, Subedi R. Urinary retention in adults: diagnosis and initial management. *Am Fam Physician.* **2008**;77(5):643–650.
96. Abbass K, Qazi A, Markert RJ, Gul W. Primary HIV Infection Associated with Acute Urinary Retention. *J Int Assoc Phys AIDS Care.* **2011**;10(3):133–134. doi:10.1177/1545109710397771
97. Kenyon LC, Goldberg HI, Kolson DL, Collman RG, Lavi E. Case of the month: may 1998--a patient with HIV infection and multiple cranial neuritis. *Brain Pathol.* **1998**;8(4):815–816.
98. Ketonen L, Kiebertz KD, Tuite MJ, Eskin T, Simon J. CNS lymphoma in an AIDS patient involving the posterior fornix case report. *J NeuroAIDS.* **1997**;1(3):43–49. doi:10.1300/j128v01n03\_03
99. Miller RG, Storey JR, Greco CM. Ganciclovir in the treatment of progressive AIDS-related polyradiculopathy. *Neurology.* **1990**;40(4):569–574. doi:10.1212/wnl.40.4.569
100. Khan Z, Singh VK, Yang WC. Neurogenic bladder in acquired immune deficiency syndrome (AIDS). *Urology.* **1992**;40(3):289–291. doi:10.1016/0090-4295(92)90496-j
101. Gyrtup HJ, Kristiansen VB, Zachariae CO, Krogsgaard K, Colstrup H, Jensen KM. Voiding problems in patients with HIV infection and AIDS. *Scand J Urol Nephrol.* **1995**;29(3):295–298. doi:10.3109/00365599509180579
102. Hermieu JF, Delmas V, Boccon-Gibod L. Micturition disturbances and human immunodeficiency virus infection. *J Urol.* **1996**;156(1):157–159.
103. Xu L, Tao R, Zhao Q, Cheng J, Zhu B. An AIDS patient with urine retention. *BMC Infect Dis.* **2019**;19(1):1051. doi:10.1186/s12879-019-4641-8
104. Heyns CF, Groeneveld AE, Sgarroa NB. Urologic complications of HIV and AIDS. *Nat Rev Urol.* **2009**;6(1):32–43. doi:10.1038/ncpuro1273

105. Andrade P, Figueiredo C, Carvalho C, Santos L, Sarmento A. Transverse myelitis and acute HIV infection: a case report. *BMC Infect Dis.* **2014**;14:149. doi:10.1186/1471-2334-14-149
106. Meier PA, Stephan KT, Blatt SP. Cytomegalovirus polyradiculopathy in HIV-infected patients. *J Gen Intern Med.* **1996**;11(1):47–49. doi:10.1007/BF02603486
107. Cole J, Choudry S, Kular S, et al. Monkeypox encephalitis with transverse myelitis in a female patient. *Lancet Infect Dis.* **2023**;23(3):e115–e120. doi:10.1016/S1473-3099(22)00741-1
108. Billioux BJ, Mbaya OT, Sejvar J, Nath A. Potential complications of monkeypox. *Lancet Neurol.* **2022**;21(10):872. doi:10.1016/S1474-4422(22)00340-4
109. Drinka PJ. Complications of chronic indwelling urinary catheters. *J Am Med Dir Assoc.* **2006**;7(6):388–392. doi:10.1016/j.jamda.2006.01.020
110. Han D, Li Z, Li R, Tan P, Zhang R, Li J. mNGS in clinical microbiology laboratories: on the road to maturity. *Crit Rev Microbiol.* **2019**;45(5–6):668–685. doi:10.1080/1040841X.2019.1681933
111. Chiu CY, Miller SA. Clinical metagenomics. *Nat Rev Genet.* **2019**;20(6):341–355. doi:10.1038/s41576-019-0113-7
112. Coker TJ, Dierfeldt DM. Acute Bacterial Prostatitis: diagnosis and Management. *Am Fam Physician.* **2016**;93(2):114–120.
113. Siegrist EA, Sassine J. Antivirals With Activity Against Mpox: a Clinically Oriented Review. *Clin Infect Dis.* **2023**;76(1):155–164. doi:10.1093/cid/ciac622
114. Russo AT, Grosenbach DW, Chinsangaram J, et al. An overview of tecovirimat for smallpox treatment and expanded anti-orthopoxvirus applications. *Expert Rev Anti Infect Ther.* **2021**;19(3):331–344. doi:10.1080/14787210.2020.1819791
115. Christie S, Chan V, Mollayeva T, Colantonio A. Systematic review of rehabilitation intervention outcomes of adult and paediatric patients with infectious encephalitis. *BMJ Open.* **2018**;8(5):e015928. doi:10.1136/bmjopen-2017-015928
116. Liesenborghs L, Huyst V, Van Dijk C, et al. Urethritis Without Skin Lesions as the Primary Manifestation of Mpox Virus Infection. *Europ urol.* **2023**;83(4):378–379. doi:10.1016/j.eururo.2022.12.022
117. Hochedez P, Consigny PH, Durand A, Buffet P. A 19-year-old male migrant with urethritis and vesicular rash. *Med Trop Sante Int.* **2023**;3(3). doi:10.48327/mtsi.v3i3.2023.376
118. Orviz E, Negredo A, Ayerdi O, et al. Monkeypox outbreak in Madrid (Spain): clinical and virological aspects. *J Infect.* **2022**;85(4):412–417. doi:10.1016/j.jinf.2022.07.005
119. Núñez I, Ceballos-Liceaga SE, de la TA, et al. Clinical features and outcomes of mpox in people with and without HIV: a national comparative study. *J Acquir Immune Defic Syndr.* doi:10.1097/QAI.0000000000003407
120. Sarier M, Kukul E. Classification of non-gonococcal urethritis: a review. *Int Urol Nephrol.* **2019**;51(6):901–907. doi:10.1007/s11255-019-02140-2
121. Sadoghi B, Kränke B, Komericki P, Hutterer G. Sexually transmitted pathogens causing urethritis: a mini-review and proposal of a clinically based diagnostic and therapeutic algorithm. *Front Med.* **2022**;9:931765. doi:10.3389/fmed.2022.931765
122. Unemo M, Ross J, Serwin AB, Gomberg M, Cusini M, Jensen JS. European guideline for the diagnosis and treatment of gonorrhoea in adults. *Int J STD AIDS.* **2020**. doi:10.1177/0959646242094126
123. Bachmann LH, Manhart LE, Martin DH, et al. Advances in the Understanding and Treatment of Male Urethritis. *Clin Infect Dis.* **2015**;61(suppl 8):S763–S769. doi:10.1093/cid/civ755
124. Matoga M, Chen JS, Massa C, et al. HIV and urethritis: time required for antiretroviral therapy to suppress HIV in semen. *AIDS.* **2023**;37(14):2233–2238. doi:10.1097/QAD.0000000000003679
125. Chen JS, Matoga M, Massa C, et al. Effects of Urethritis on Human Immunodeficiency Virus (HIV) in Semen: implications for HIV Prevention and Cure. *Clin Infect Dis.* **2021**;73(7):e2000–e2004. doi:10.1093/cid/ciaa1529
126. Philpott D, Hughes CM, Alroy KA, et al. Epidemiologic and Clinical Characteristics of Monkeypox Cases - United States, May 17–July 22, 2022. *MMWR Morb Mortal Wkly Rep.* **2022**;71(32):1018–1022. doi:10.15585/mmwr.mm7132e3
127. de SIN, Pascom ARP, Spinelli MF, Dias GB, Barreira D, Miranda AE. Demographic and clinical characteristics of people diagnosed with active sexually transmitted infections among monkeypox cases in Brazil: the 2022 outbreak. *Rev Inst Med Trop Sao Paulo.* **2024**;66:e20. doi:10.1590/S1678-9946202466020
128. Yon H, Shin H, Shin JI, et al. Clinical manifestations of human Mpox infection: a systematic review and meta-analysis. *Rev Med Virol.* **2023**;33(4):e2446. doi:10.1002/rmv.2446
129. Miyazaki Y, Adachi T. Human mpox presenting with penile edema and ulcer: a case report. *J Infect Chemother.* doi:10.1016/j.jiac.2024.01.004
130. Koh SS, Youssef SM, Baghchechi M, et al. Disseminated and penile mpox with histopathologic correlation: two separate case reports. *J Cutan Pathol.* **2023**;50(10):873–877. doi:10.1111/cup.14499
131. Derin O, Öztürk EN, Demirbaş ND, Sevgi DY, İ D. A Patient Presented with Genital Eruptions: the Second Case of Monkeypox from Türkiye. *Mikrobiyol Bul.* **2023**;57(1):134–140. doi:10.5578/mb.20239911
132. Chen TC. Monkeypox presenting with unusual sign of penis ulcer in a newly diagnosed human immunodeficiency virus infected patient. *J Formos Med Assoc.* **2024**;123(2):293–294. doi:10.1016/j.jfma.2023.09.007
133. Kreuter A, Grossmann M, Müller VL, et al. Monkeypox infection with concomitant penile lymphoedema. *J Eur Acad Dermatol Venereol.* **2023**;37(3):e431–e432. doi:10.1111/jdv.18502
134. Patrocinio-Jesus R, Peruzzo F. Monkeypox Genital Lesions. *N Engl J Med.* **2022**;387(1):66. doi:10.1056/NEJMicm2206893
135. Clemens SL, Isaacs SN. Mpox: keep it on the differential. *Cleve Clin J Med.* **2023**;90(9):565–575. doi:10.3949/ccjm.90a.23020
136. Bayer-Garner IB. Monkeypox virus: histologic, immunohistochemical and electron-microscopic findings. *J Cutan Pathol.* **2005**;32(1):28–34. doi:10.1111/j.0303-6987.2005.00254.x
137. Iñigo Martínez J, Gil Montalbán E, Jiménez Bueno S, et al. Monkeypox outbreak predominantly affecting men who have sex with men 2022. *Euro Surveill.* **2022**;27(27):2200471. doi:10.2807/1560-7917.ES.2022.27.27.2200471
138. Gamo Guerrero M, Simón Gosalbo A, Martín Díaz M, et al. Interdisciplinary management of mpox-related local complications: report on a series of cases. *Front Med Lausanne.* **2023**;10:1184924. doi:10.3389/fmed.2023.1184924
139. Griffiths-Acha J, Vela-Ganuza M, Sarró-Fuente C, López-Esteban JL. Monkeypox: a new differential diagnosis when addressing genital ulcer disease. *Br J Dermatol.* **2022**;187(6):1050–1052. doi:10.1111/bjd.21834



140. Erez N, Achdout H, Milrot E, et al. Diagnosis of Imported Monkeypox, Israel, 2018. *Emerg Infect Dis.* **2019**;25(5):980–983. doi:10.3201/eid2505.190076
141. Cecconi M, Evans L, Levy M, Rhodes A. Sepsis and septic shock. *Lancet.* **2018**;392(10141):75–87. doi:10.1016/S0140-6736(18)30696-2
142. Zeyen C, Kinberger M, Kriedemann H, et al. Clinical spectrum and long-term outcomes of mpox: a cohort study spanning from acute infection to six-month follow-up. *BMC Infect Dis.* **2024**;24(1):317. doi:10.1186/s12879-024-09191-6
143. Wegrzyn GH, Kilianek M, Yallapragada S, Vidal P, Dobbs RW. Genitourinary Mpox: a case report & primer for urologists. *Urology Case Reports.* **2023**;51:102559. doi:10.1016/j.eucr.2023.102559
144. Sobral-Costas TG, Escudero-Tornero R, Servera-Negre G, et al. Human monkeypox outbreak: epidemiological data and therapeutic potential of topical cidofovir in a prospective cohort study. *J Am Acad Dermatol.* **2023**;88(5):1074–1082. doi:10.1016/j.jaad.2022.10.043
145. Carlson C, Katz R. WHO ends public health emergency designation for mpox. *BMJ.* **2023**;381:1190. doi:10.1136/bmj.p1190
146. Osadebe L, Hughes CM, Shongo Lushima R, et al. Enhancing case definitions for surveillance of human monkeypox in the Democratic Republic of Congo. *PLoS Negl Trop Dis.* **2017**;11(9):e0005857. doi:10.1371/journal.pntd.0005857
147. Bustin SA. How to speed up the polymerase chain reaction. *Biomol Detect Quantif.* **2017**;12:10–14. doi:10.1016/j.bdq.2017.05.002
148. Dolatshahi Z, Nargesi S, Sadeghifar J, et al. Economic evaluation of laboratory diagnostic test types in Covid-19 epidemic: a systematic review. *Int J Surg.* **2022**;105:106820. doi:10.1016/j.ijsu.2022.106820
149. Soe NN, Yu Z, Latt PM, et al. Using AI to Differentiate Mpox From Common Skin Lesions in a Sexual Health Clinic: algorithm Development and Validation Study. *J Med Internet Res.* **2024**;26:e52490. doi:10.2196/52490
150. Thieme AH, Zheng Y, Machiraju G, et al. A deep-learning algorithm to classify skin lesions from mpox virus infection. *Nat Med.* **2023**;29(3):738–747. doi:10.1038/s41591-023-02225-7
151. Bansal M, Arora R, Keshari S, Panchal S Monkeypox Prediction using Machine Learning. In: *2023 14th International Conference on Computing Communication and Networking Technologies (ICCCNT)*. IEEE; **2023**:1–10. doi:10.1109/ICCCNT56998.2023.10306370.
152. Kmiec D, Kirchhoff F. Monkeypox: a New Threat? *Int J Mol Sci.* **2022**;23(14):7866. doi:10.3390/ijms23147866
153. Guo M, Xiong M, Peng J, et al. Multi-omics for COVID-19: driving development of therapeutics and vaccines. *Natl Sci Rev.* **2023**;10(9):nwad161. doi:10.1093/nsr/nwad161
154. Dueñas ME, Peltier-Heap RE, Leveridge M, Annan RS, Büttner FH, Trost M. Advances in high-throughput mass spectrometry in drug discovery. *EMBO Mol Med.* **2023**;15(1):e14850. doi:10.15252/emmm.202114850
155. Sadybekov AV, Katritch V. Computational approaches streamlining drug discovery. *Nature.* **2023**;616(7958):673–685. doi:10.1038/s41586-023-05905-z
156. Ogoina D, Mohammed A, Yinka-Ogunleye A, Ihekweazu C. A case of suicide during the 2017 monkeypox outbreak in Nigeria. *IJID Reg.* **2022**;3:226–227. doi:10.1016/j.ijregi.2022.04.004
157. Ogoina D, Izbewule JH, Ogunleye A, et al. The 2017 human monkeypox outbreak in Nigeria-Report of outbreak experience and response in the Niger Delta University Teaching Hospital, Bayelsa State, Nigeria. *PLoS One.* **2019**;14(4):e0214229. doi:10.1371/journal.pone.0214229
158. Irshad U. Overcoming stigma-contracting mpox as a minoritised trainee. *Lancet Infect Dis.* **2023**;23(4):400. doi:10.1016/S1473-3099(23)00064-6
159. Orsini D, Sartini M, Spagnolo AM, Cristina ML, Martini MM. “the stigma is as dangerous as the virus”. Historical, social, ethical issues and future forthcoming. *J Prev Med Hyg.* **2023**;64(4):E398–E404. doi:10.15167/2421-4248/jpmh2023.64.4.3144
160. Alhasan K, Sallam M, Aljamaan F, et al. Mpox Perceptions and Vaccine Advocacy among the Healthcare Workers of Solid Organ Transplant Centers: a Multicenter, Cross-Sectional Survey in Saudi Arabia. *Healthcare.* **2023**;11(4):603. doi:10.3390/healthcare11040603
161. Lozano JM, Muller S. Monkeypox: potential vaccine development strategies. *Trends Pharmacol Sci.* **2023**;44(1):15–19. doi:10.1016/j.tips.2022.10.005
162. Saadh MJ, Ghadimkhani T, Soltani N, et al. Progress and prospects on vaccine development against monkeypox infection. *Microb Pathog.* **2023**;180:106156. doi:10.1016/j.micpath.2023.106156
163. Deputy NP, Deckert J, Chard AN, et al. Vaccine Effectiveness of JYNNEOS against Mpox Disease in the United States. *N Engl J Med.* **2023**;388(26):2434–2443. doi:10.1056/NEJMoa2215201
164. Cohn H, Bloom N, Cai GY, et al. Mpox vaccine and infection-driven human immune signatures: an immunological analysis of an observational study. *Lancet Infect Dis.* **2023**;23(11):1302–1312. doi:10.1016/S1473-3099(23)00352-3
165. Wang H, Yin P, Zheng T, et al. Rational design of a “two-in-one” immunogen DAM drives potent immune response against mpox virus. *Nat Immunol.* **2024**;25(2):307–315. doi:10.1038/s41590-023-01715-7
166. Xia H, He YR, Zhan XY, Zha GF. Mpox virus mRNA-lipid nanoparticle vaccine candidates evoke antibody responses and drive protection against the Vaccinia virus challenge in mice. *Antiviral Res.* **2023**;216:105668. doi:10.1016/j.antiviral.2023.105668
167. Hou F, Zhang Y, Liu X, et al. mRNA vaccines encoding fusion proteins of monkeypox virus antigens protect mice from vaccinia virus challenge. *Nat Commun.* **2023**;14(1):5925. doi:10.1038/s41467-023-41628-5

## Infection and Drug Resistance

### Publish your work in this journal

Infection and Drug Resistance is an international, peer-reviewed open-access journal that focuses on the optimal treatment of infection (bacterial, fungal and viral) and the development and institution of preventive strategies to minimize the development and spread of resistance. The journal is specifically concerned with the epidemiology of antibiotic resistance and the mechanisms of resistance development and diffusion in both hospitals and the community. The manuscript management system is completely online and includes a very quick and fair peer-review system, which is all easy to use. Visit <http://www.dovepress.com/testimonials.php> to read real quotes from published authors.

Submit your manuscript here: <https://www.dovepress.com/infection-and-drug-resistance-journal>

**Dovepress**  
Taylor & Francis Group