

# *Escherichia coli* in the T11–12 Thoracic Vertebrae: A Case Report

Dandan Weng<sup>1</sup>\*, Hongyuan Zhou<sup>1</sup>\*, Guancheng Huang<sup>1</sup>, Qingren Cao<sup>2</sup>, Huafeng Wang<sup>3</sup>, Zhujun Cao<sup>2</sup>, Qing Xie<sup>2</sup>

<sup>1</sup>Department of Infectious Diseases, Yuyao People's Hospital, Ningbo, Zhejiang, People's Republic of China; <sup>2</sup>Department of Infectious Diseases, Ruijin Hospital, Shanghai Jiao Tong University School of Medicine, Shanghai, People's Republic of China; <sup>3</sup>Department of Pathology, Ruijin Hospital, Shanghai Jiao Tong University School of Medicine, Shanghai, People's Republic of China

\*These authors contributed equally to this work

Correspondence: Qing Xie; Zhujun Cao, Department of Infectious Diseases, Ruijin Hospital, Shanghai Jiao Tong University School of Medicine, 197 Ruijin Er Road, Shanghai, 200025, People's Republic of China, Email xieqingrjh@163.com; estherlucifer@163.com

**Background:** Pyogenic thoracic spondylitis is a rare but severe infection, particularly when complicated by sepsis and acute kidney injury (AKI). Early diagnosis and precise management are essential for improving outcomes, given the limitations of traditional microbiology detection methods in identifying the causative pathogens.

**Case Presentation:** A 68-year-old immunocompetent male presented with recurrent fever, fatigue, loss of appetite and initial evidence of sepsis and AKI upon admission. With the prompt computed tomography (CT)-guided percutaneous biopsy of the thoracic vertebrae, *Escherichia coli* was identified as the causative pathogen using metagenomic next-generation sequencing (mNGS). A diagnosis of pyogenic thoracic spondylitis was then made followed by the treatment of antibiotics optimized by therapeutic drug monitoring (TDM) techniques. With a total effective antibiotic treatment period of 7 weeks, the patient recovered without resorting to surgical interventions.

**Conclusion:** This is a rare case of acute thoracic spondylitis caused by *E. coli*, successfully treated without surgery. This case highlights the significant challenges in diagnosis and treatment. It underscores the value of mNGS in identifying rare infections and emphasizes the role of TDM in optimizing antibiotic therapy, providing a reference for future cases of rare and critical infections with fever of unknown origin.

**Keywords:** pyogenic thoracic spondylitis, metagenomic next-generation sequencing, mNGS, therapeutic drug monitoring, TDM, antibiotic therapy, fever of unknown origin

## Introduction

Acute pyogenic spondylitis, though rare, has seen a rising incidence in recent years.<sup>1–3</sup> The lumbar spine is most often affected, followed by the thoracic spine.<sup>4,5</sup> *Staphylococcus aureus* is the primary pathogen, though infections from Gram-negative bacteria are also on the rise.<sup>6–8</sup> Early diagnosis is challenging due to non-specific symptoms,<sup>9</sup> yet the consequences of delayed treatment—such as neurological damage and spinal deformity—can be severe.<sup>5</sup> Conservative management of pyogenic spondylitis primarily relies on antibiotic therapy, making early diagnosis and pathogen identification essential.<sup>8,10,11</sup> Advanced diagnostic methods, such as metagenomic next-generation sequencing (mNGS) and therapeutic drug monitoring (TDM), can overcome the limitations of traditional approaches, demonstrating clear advantages in severe infections like pyogenic spondylitis. mNGS allows for broad-spectrum pathogen identification in a single test, which is particularly useful when conventional cultures fail or the pathogen is unknown, with rapid results that support early and accurate diagnosis.<sup>12</sup> Meanwhile, TDM optimizes antibiotic therapy by maintaining drug concentrations within therapeutic ranges, tailoring doses based on individual pharmacokinetics to ensure both efficacy and safety.<sup>13</sup>

*Escherichia coli* is commonly associated with urinary and gastrointestinal tract infections,<sup>14,15</sup> while infections of the thoracic spine caused by *E. coli* are extremely rare, especially in immunocompetent patients, with only a few reported cases.<sup>16</sup>

This case describes a 68-year-old male with normal immune function who experienced such an infection. His onset was very subtle; initially, he presented with fever, fatigue, and loss of appetite, without typical symptoms like urinary frequency or back pain. As the disease progressed, he developed mild lower back discomfort, which was also non-specific. During diagnosis and treatment, we employed advanced techniques such as mNGS, CT-guided percutaneous thoracic vertebral biopsy, and TDM, ultimately achieving a satisfactory clinical outcome. The successful management of this rare and critical case provides valuable insights for the diagnosis and treatment of similar conditions in the future.

## Case Presentation

### Medical History

An elderly male patient was admitted to Ruijin Hospital, Shanghai Jiao Tong University School of Medicine, on March 1, 2024, with a 20-day history of recurrent fever.

The patient developed a fever (maximum temperature of 39°C) 20 days prior to admission, accompanied by chills, fatigue, and mild loss of appetite. Inflammatory markers, including white blood cell count (WBC), C-reactive protein (CRP), and procalcitonin (PCT) were elevated (Figure 1A–C). Interestingly, *E. coli* cultured on February 19 showed no antibiotic resistance. Despite receiving various antibiotics for anti-infective treatment (Figure 1D), the urinary tract infection improved (Figure 1E); however, the patient continued to experience recurrent fever (Figure 1F), and creatinine levels further increased (Figure 1G). As a result, the patient was transferred to Ruijin Hospital for further evaluation and treatment.

His medical history included hypertension, premature ventricular contractions, and thrombocytosis. He denied any history of diabetes, cancer, tuberculosis exposure, or raw food or livestock contact. The patient was a former smoker who quit 10 years ago. Physical examination revealed no positive findings, and there was no renal percussion pain.

### Treatment and Prognosis

From March 1 to 4, the patient was treated with meropenem, and his body temperature remained normal. From March 5 to 7, fever recurred (Tmax 40°C, Figure 2A). Laboratory tests showed elevated WBC, CRP and PCT (Figure 2B–D). Linezolid was added to cover potential G-positive bacteria (Figure 2E). Blood cultures were negative. From March 8 to 10, blood mNGS was performed on the MGISEQ-200 platform, manufactured by Beijing Genomics Institute (BGI), which detected *E. coli* (Table 1). Linezolid was discontinued, and the meropenem dosage was adjusted (Figure 2E). On March 11, chest CT revealed lung consolidation. Moxifloxacin was added to broaden coverage for potential atypical pathogens, and the meropenem dosage was increased to enhance activity against G-negative bacteria. Serum creatinine slightly decreased from the highest level of 360 µmol/L upon admission, with a small increase thereafter, but it has consistently remained above 300 µmol/L (Figure 2F). On March 16, the patient developed lumbar pain. MRI revealed a soft tissue infection at T11–T12 (Figure 3a), which showed a reduction in the lesion after the anti-infective treatment on April 9 (Figure 3b). Levofloxacin and tigecycline were added. On March 19, a CT-guided biopsy was performed. The next day, mNGS confirmed acute pyogenic spondylitis caused by *E. coli* (Table 2), with resistance to third-generation cephalosporins (Table 3). On March 22, tigecycline dosage was reduced due to gastrointestinal discomfort, and meropenem dosage was increased following TDM results, which were obtained using High-Performance Liquid Chromatography (HPLC) (Table 4). On March 26, biopsy results confirmed acute pyogenic spondylitis (Figure 4). From March 29 to April 8, the patient's temperature remained normal, gastrointestinal symptoms resolved, and mental status and appetite improved. Creatinine levels steadily decreased (Figure 2F), while WBC declined slowly (Figure 2B).

On April 8, tigecycline was discontinued, while meropenem and levofloxacin were continued. The patient was discharged on April 15 in stable condition.

### Follow-Up

From April 15 to May 12, the patient took minocycline (100 mg PO q12h) and faropenem (0.2 g PO TID) for four weeks, with no fever or discomfort reported. At the August follow-up, the patient had fully recovered, with normal lab results

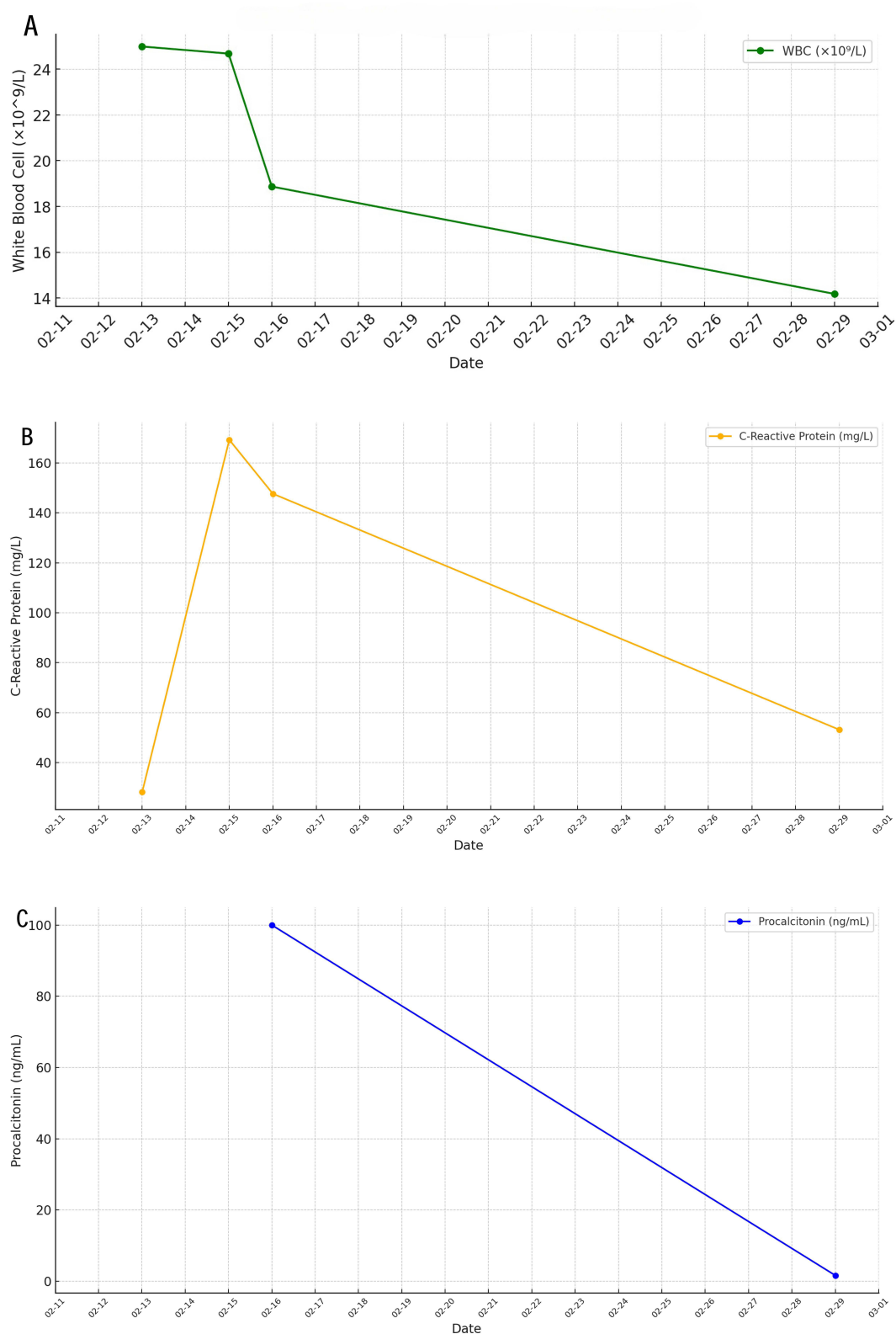
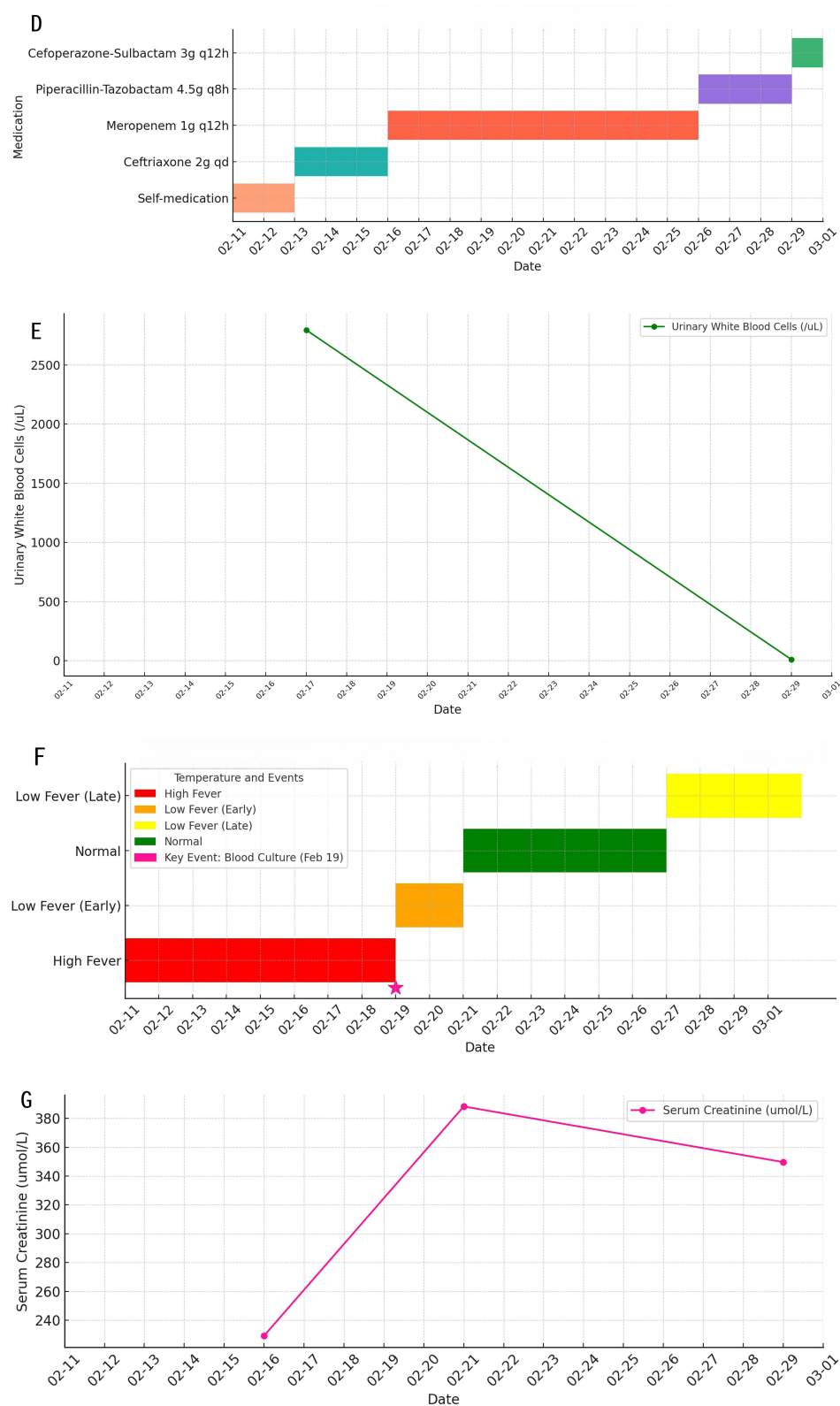

Figure 1 Continued.



**Figure 1** Pre-Admission Data (A). Timeline of White Blood Cell Count (WBC) (B). Timeline of C-Reactive Protein (CRP) (C). Timeline of Procalcitonin (PCT) (D). Timeline of Anti-Infective Treatment (E). Timeline of Urinary White Blood Cells (F). Timeline of Recurrent Fever with Key Events (G). Timeline of Serum Creatinine.

and resumed daily activities. A follow-up MRI of the thoracic spine was scheduled for six months to monitor for any residual lesions.

## Discussion

Pyogenic spondylitis is an infection of the vertebrae and surrounding tissues, potentially leading to spinal instability, bacteremia, and sepsis, with mortality rates reported between 3% and 24%.<sup>17–19</sup> Common risk factors include advanced age, immunosuppression, diabetes, and prior spinal surgery.<sup>20</sup> Hematogenous spread is the primary route of infection, with *S. aureus* as the most frequently implicated pathogen, followed by *E. coli*,<sup>8</sup> primarily in lumbar. However, *E. coli* involvement in thoracic spondylitis remains rare. This case report provides valuable insights into this unique clinical entity, addressing a gap in the current body of evidence.

We conducted a thorough history-taking and noted that the patient performed sit-ups the day before symptom onset, possibly triggering spinal injury. Initially, we suspected that a UTI caused by *E. coli* progressed to septicemia due to poor infection control, allowing the bacteria to disseminate to the affected thoracic spine through the bloodstream.<sup>6</sup> However, the exact route of *E. coli* transmission to the thoracic spine remains unclear and speculative. The severe infection led to a systemic inflammatory response syndrome (SIRS), resulting in reduced renal blood flow, the release of inflammatory

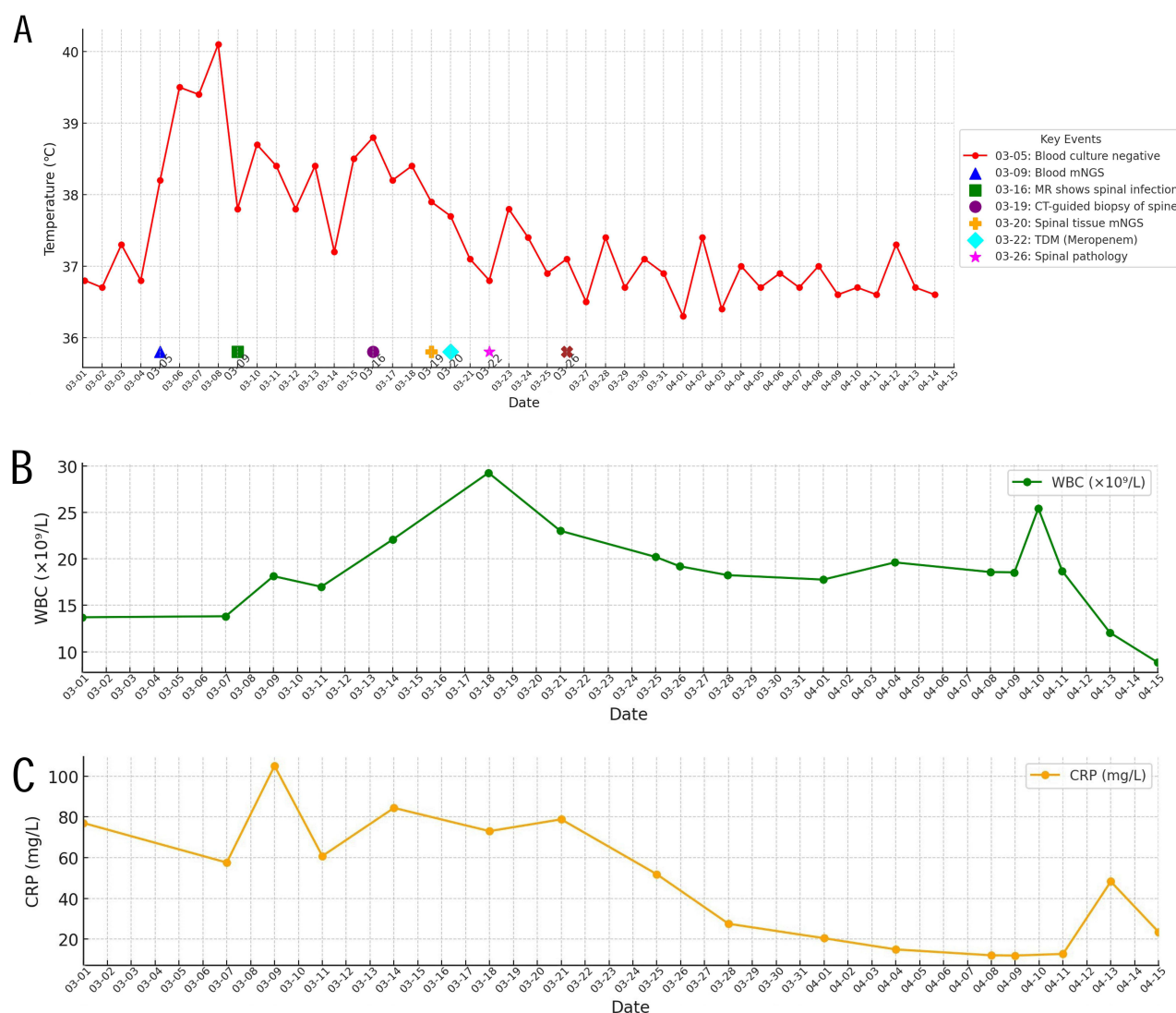
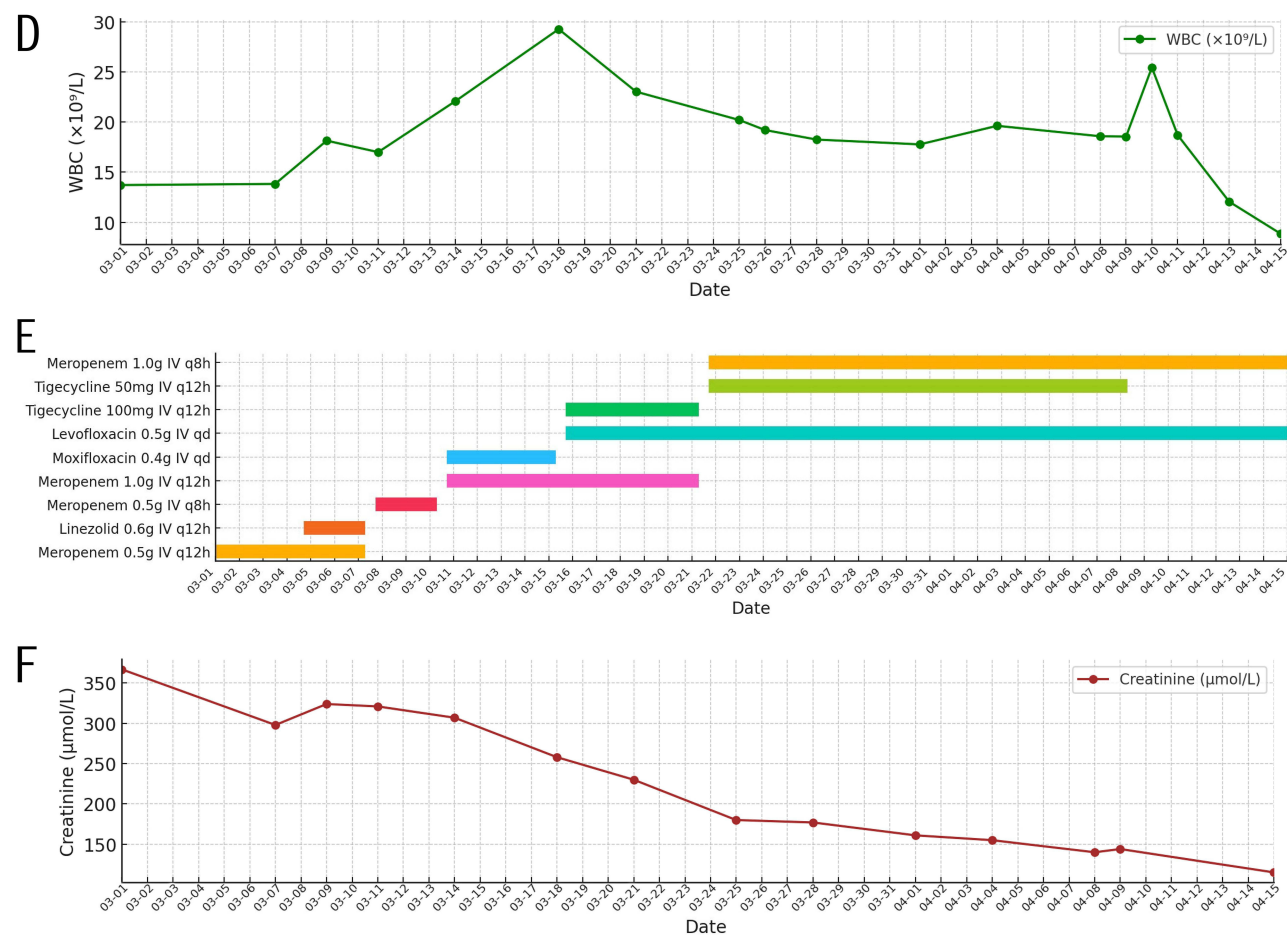


Figure 2 Continued.



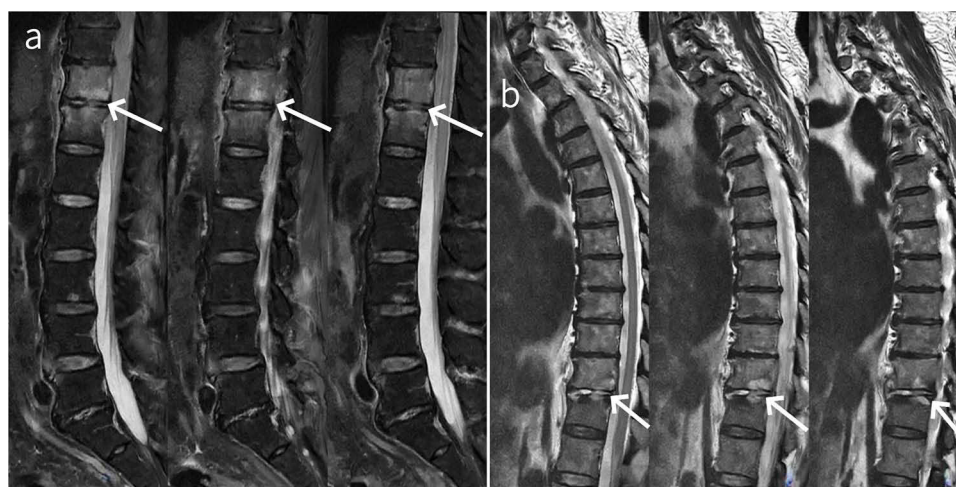**Figure 2** In-Hospital Data (A). Timeline of Body Temperature with Key Events (B). Timeline of White Blood Cell Count (WBC) (C). Timeline of C-Reactive Protein (CRP) (D). Timeline of Procalcitonin (PCT) (E). Timeline of Antibiotic Therapy (F). Timeline of Serum Creatinine.

mediators, and tubular damage, ultimately causing acute kidney injury (AKI).<sup>21</sup> However, the patient only presented with fever and mild appetite loss—non-specific symptoms—and did not exhibit symptoms such as urinary frequency, urgency, or low back pain, which delayed our recognition of a potential spinal infection. As the condition evolved, the decrease in white blood cells in the urine suggested that the urinary tract infection was improving. Yet, the persistent fever and progressively rising creatinine levels remained unexplained. A blood mNGS test identified *E. coli*, even when traditional blood cultures remained negative, suggesting the potential utility of mNGS in overcoming limitations of standard culture methods. On March 16, lumbar MRI confirmed a thoracic spine infection as the cause of the fever, with the diagnosis

**Table 1** Blood mNGS Results (March 9, 2024)

Category	Pathogen	Type	Sequence Number	Relative Abundance (%)
Bacteria	<i>Escherichia coli</i>	G-	59	15.638
Microecology	<i>Oslo Moraxella</i>	G-	12	1.646
	<i>Staphylococcus warneri</i>	G+	4	1.176
	<i>Staphylococcus epidermidis</i>	G+	3	0.9
	<i>Candida parapsilosis</i>	–	1	0.581





**Figure 3** Imaging Examination of Thoracic Vertebral Lesions Over Time (a) Lumbar MRI (March 16) showing abnormal signals at T11 and T12 thoracic vertebrae and paravertebral soft tissue swelling (arrow), suggesting possible infection. (b) Thoracic MRI (April 9) indicating lesion size reduction at T11 and T12, with persistent paravertebral soft tissue swelling (arrow).

occurring earlier than the 1–3 months typically reported in the literature.<sup>9</sup> Subsequently, CT-guided sampling of the affected thoracic spine tissue was performed, followed by direct mNGS, which offers faster results and precise pathogen identification compared to traditional methods. Due to the cost of conducting multiple tests simultaneously and the

**Table 2** mNGS Results for Thoracic Paravertebral Tissue (March 20, 2024)

Category	Pathogen	Type	Sequence Number	Relative Abundance (%)
Bacteria	<i>Escherichia coli</i>	G-	13613	17.9%
Viruses	<i>Torque teno virus</i>	DNA	423	27.9%
	<i>Epstein-Barr virus</i>	DNA	31	0.1%

**Table 3** List of Antibiotic Resistance Genes From mNGS of Thoracic Paravertebral Tissue (March 20, 2024)

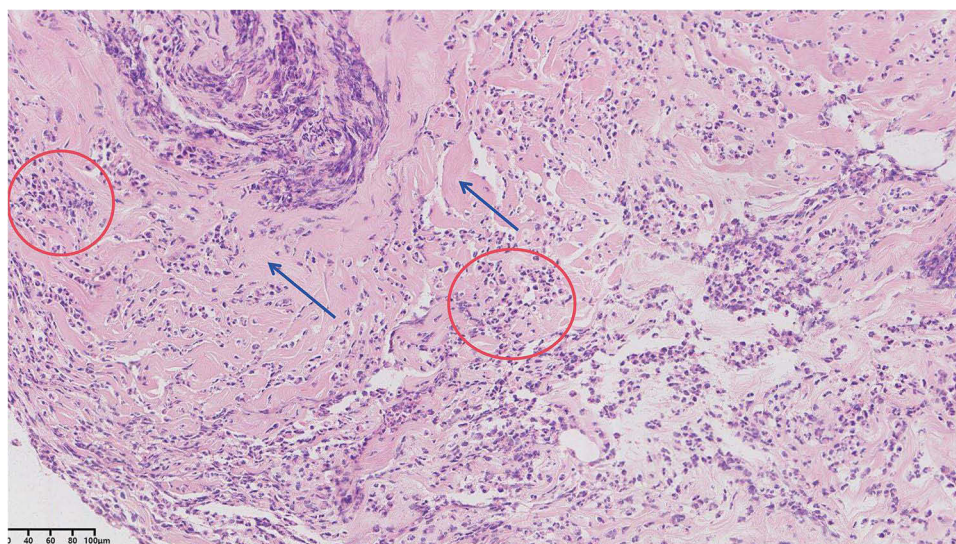
Name	Sequence Count	Resistance Type	Suspected Species	Association Confidence	Suspected Resistance List
<i>blaCTX-M</i>	11	Penicillin 3rd, generation cephalosporin	<i>Escherichia coli</i>	>95%	Amoxicillin, Cefotaxime

**Notes:** *BlaCTX-M*, referring to the beta-lactamase cefotaximase-Munich genes, specifically corresponds to the drug resistance genes *blaCTX-M14*, *blaCTX-M15*, and *blaCTX-M27*.

**Table 4** Meropenem Blood Drug Concentration Results (March 22, 2024)

Item	Result	Reference Range
Meropenem Blood Drug Concentration	4.7	mg/L

**Notes:** The meropenem blood concentration is relatively low. Clinical adjustment of the dose may be required. For critically ill patients, a higher PK/PD target attainment (100% fT > MIC) is required, meaning that the trough concentration should be  $\geq$  MIC. However, it is not recommended for the trough concentration to exceed 64 mg/L, as this increases the risk of adverse effects.



**Figure 4** Pathology of Thoracic Spine Tissue March 26: The tissue sample shows neutrophil and lymphocyte infiltration, abscess formation, and stromal hyaline degeneration, indicating acute pyogenic inflammation. Red circles mark neutrophil infiltration, and blue arrows show hyaline degeneration.

limited availability of samples, we opted for mNGS and pathology, rather than performing routine cultures. This approach is particularly valuable for rapidly detecting uncommon pathogens and antibiotic resistance genes, enabling precise therapy (Table 3).

Despite a clear diagnosis, the patient continued to experience persistent fever and elevated infection markers, posing significant challenges to treatment. Observing the poor efficacy of meropenem monotherapy (initially, we did not realize the need for TDM) and the presence of resistant genes, we aimed to increase antibiotic concentrations in the thoracic spine tissue. To prevent severe complications such as paralysis due to inadequate infection control, we added tigecycline and levofloxacin alongside meropenem, while closely monitoring renal function.

When selecting the antibiotics, we considered factors such as drug availability. Levofloxacin was chosen for its excellent bioavailability in bone tissue and its recommendation in clinical guidelines.<sup>22</sup> Tigecycline was included due to its broad-spectrum efficacy against multidrug-resistant pathogens, including *E. coli*, and its strong penetration into soft tissues and infected areas.<sup>23</sup> However, it should be noted that *E. coli* can develop resistance to both meropenem and tigecycline, depending on the specific resistance mechanisms. On March 22, the patient developed gastrointestinal side effects from tigecycline, necessitating a dose reduction. This prompted a reassessment of the meropenem dosing. Given the patient's impaired kidney function and the traditional treatment plan, we had initially administered an adequate dose of meropenem. To ensure both safety and efficacy, we consulted with clinical pharmacists, who recommended using TDM for meropenem to optimize the dosing. TDM is a crucial tool for antibiotic management in critically ill patients enabling precise dosage adjustments to optimize treatment and minimize adverse effects.<sup>24,25</sup> Achieving a higher PK/PD target (100% fT > MIC) is essential,<sup>26</sup> which means that the trough concentration of meropenem should meet or exceed the MIC (minimum inhibitory concentration). Since *E. coli* resistant to third-generation cephalosporins may have elevated MIC values (for example,  $\geq 4$   $\mu\text{g/mL}$  or even  $\geq 8$   $\mu\text{g/mL}$ ),<sup>27,28</sup> increased meropenem doses were necessary to ensure sufficient drug penetration into the thoracic spine, where levels are lower than in plasma.<sup>29</sup> The dosage was adjusted accordingly to enhance infection control. As a result, the patient's kidney function gradually improved and ultimately returned to normal.

Although there is currently no standardized guideline in the literature for the duration of antibiotic use in spondylitis, a minimum of six weeks is generally recommended.<sup>22</sup> In this case, after 46 days of hospitalization, the patient had received over three weeks of effective treatment with meropenem, during which their temperature remained stable for over two weeks, leading to a successful discharge on April 15. After discharge, the patient continued oral antibiotics for four weeks, completing a total of 7 weeks of effective antibiotic treatment and achieving a satisfactory clinical outcome without the need for surgical intervention.



## Conclusion

This case highlights the value of mNGS and TDM in managing acute pyogenic spondylitis caused by *E. coli* with AKI. As *E. coli* is rare in bone and soft tissue infections, mNGS enabled rapid pathogen identification and targeted therapy, improving outcomes. TDM optimized meropenem dosing, ensuring precise and safe treatment. This case underscores the potential of mNGS and TDM for personalized, effective infection management.

Looking forward, there is significant potential to develop personalized treatment protocols using the combined strengths of mNGS and TDM. Future research could focus on tailoring precision-based therapeutic strategies that address individual needs, especially for critically ill patients, by incorporating factors like pathophysiology, infection type, and drug metabolism.

## Abbreviations

AKI, Acute Kidney Injury; mNGS, Metagenomic Next-Generation Sequencing; TDM, Therapeutic Drug Monitoring; CT, Computed Tomography; WBC, White Blood Cell; CRP, C-Reactive Protein; PCT, Procalcitonin; RBC, Red Blood Cell; UTI, Urinary Tract Infection; Hb, Hemoglobin; Tmax, Maximum Temperature; HPLC, High-Performance Liquid Chromatography; MRI, Magnetic Resonance Imaging; SIRS, Systemic Inflammatory Response Syndrome; *E. coli*, *Escherichia coli*; PO, Per O (Orally); TID, Ter In Die (Three times a day); PK/PD, Pharmacokinetic / Pharmacodynamic.

## Ethics Approval and Consent to Participate

Informed consent for the publication of medical histories and photographs was obtained from the patient. Additionally, approval for case publication was granted by the Ethics Committee of Ruijin Hospital, affiliated with Shanghai Jiao Tong University School of Medicine.

## Acknowledgments

The authors express their sincere gratitude to the patient who participated in this study for his invaluable support.

## Funding

This research received no external funding.

## Disclosure

The authors report no conflicts of interest in this work.

## References

- Kramer A, Thavarajasingam SG, Neuhoff J, et al. Epidemiological trends of pyogenic spondylodiscitis in Germany: an EANS Spine Section Study. *Sci Rep*. 2023;13(1):20225. doi:10.1038/s41598-023-47341-z
- Conan Y, Laurent E, Belin Y, et al. Large increase of vertebral osteomyelitis in France: a 2010-2019 cross-sectional study. *Epidemiol Infect*. 2021;149:e227. doi:10.1017/s0950268821002181
- Issa K, Diebo BG, Faloon M, et al. The epidemiology of vertebral osteomyelitis in the United States From 1998 to 2013. *Clin Spine Surg*. 2018;31(2):E102-E108. doi:10.1097/bsd.0000000000000597
- Zimmerli W. Vertebral Osteomyelitis. *N Engl J Med*. 2010;362:1022-1029. doi:10.1056/NEJMc0910753
- Marathe NA, Tedesco G, Chiesa AM, et al. Pyogenic and non-pyogenic spinal infections: diagnosis and treatment. *Curr Med Imaging*. 2022;18(2):231-241. doi:10.2174/1573405617666211117143203
- Kang SJ, Jang HC, Jung SI, et al. Clinical characteristics and risk factors of pyogenic spondylitis caused by gram-negative bacteria. *PLoS One*. 2015;10(5):e0127126. doi:10.1371/journal.pone.0127126
- Berbari EF, Kanj SS, Kowalski TJ, et al. 2015 Infectious Diseases Society of America (IDSA) clinical practice guidelines for the diagnosis and treatment of native vertebral osteomyelitis in adults. *Clin Infect Dis*. 2015;61(6):e26-46. doi:10.1093/cid/civ482
- Kim NJ. Microbiologic diagnosis of pyogenic spondylitis. *Infect Chemother*. 2021;53(2):238-246. doi:10.3947/ic.2021.0054
- Babic M, Simpfendorfer CS. Infections of the Spine. *Infect Dis Clin North Am*. 2017;31(2):279-297. doi:10.1016/j.idc.2017.01.003
- Aljawadi A, Jahangir N, Jeelani A, et al. Management of pyogenic spinal infection, review of literature. *J Orthop*. 2019;16(6):508-512. doi:10.1016/j.jor.2019.08.014
- Sato K, Yamada K, Yokosuka K, et al. Pyogenic spondylitis: clinical features, diagnosis and treatment. *Kurume Med J*. 2019;65(3):83-89. doi:10.2739/kurumemedj.MS653001
- Gu W, Deng X, Lee M, et al. Rapid pathogen detection by metagenomic next-generation sequencing of infected body fluids. *Nat Med*. 2021;27(1):115-124. doi:10.1038/s41591-020-1105-z

13. Martin-Loeches I. Therapeutic drug monitoring (TDM) in real-time: a need for the present future. *Expert Rev Anti Infect Ther.* **2022**;20(10):1245–1247. doi:10.1080/14787210.2022.2110070
14. Kong H, Hong X, Li X. Current perspectives in pathogenesis and antimicrobial resistance of enteroaggregative *Escherichia coli*. *Microb Pathog.* **2015**;85:44–49. doi:10.1016/j.micpath.2015.06.002
15. Lee DS, Lee SJ, Choe HS. Community-acquired urinary tract infection by *Escherichia coli* in the era of antibiotic resistance. *Biomed Res Int.* **2018**;2018:7656752. doi:10.1155/2018/7656752
16. Jiang N, Ma YF, Jiang Y, et al. Clinical characteristics and treatment of extremity chronic osteomyelitis in Southern China: a retrospective analysis of 394 consecutive patients. *Medicine.* **2015**;94(42):e1874. doi:10.1097/md.0000000000001874
17. Aagaard T, Roed C, Dahl B, Obel N. Long-term prognosis and causes of death after spondylodiscitis: a Danish nationwide cohort study. *Infect Dis.* **2016**;48(3):201–208. doi:10.3109/23744235.2015.1103897
18. Lang S, Walter N, Schindler M, et al. The Epidemiology of Spondylodiscitis in Germany: a descriptive report of incidence rates, pathogens, in-hospital mortality, and hospital stays between 2010 and 2020. *J Clin Med.* **2023**;12(10):3373. doi:10.3390/jcm12103373
19. Thavarajasingam SG, Vemulapalli KV, Vishnu KS, et al. Conservative versus early surgical treatment in the management of pyogenic spondylodiscitis: a systematic review and meta-analysis. *Sci Rep.* **2023**;13(1):15647. doi:10.1038/s41598-023-41381-1
20. Ziarko TP, Walter N, Schindler M, Alt V, Rupp M, Lang S. Risk factors for the in-hospital mortality in pyogenic vertebral osteomyelitis: a cross-sectional study on 9753 patients. *J Clin Med.* **2023**;12(14):4805. doi:10.3390/jcm12144805
21. Hoste EAJ, Kellum JA, Selby NM, et al. Global epidemiology and outcomes of acute kidney injury. *Nat Rev Nephrol.* **2018**;14(10):607–625. doi:10.1038/s41581-018-0052-0
22. Lacasse M, Derolez S, Bonnet E, et al. 2022 SPILF - clinical practice guidelines for the diagnosis and treatment of disco-vertebral infection in adults. *Infect Dis Now Apr.* **2023**;53(3):104647. doi:10.1016/j.idnow.2023.01.007
23. Kasbekar N. Tigecycline: a new glycylcycline antimicrobial agent. *Am J Health Syst Pharm.* **2006**;63(13):1235–1243. doi:10.2146/ajhp050487
24. Ozdemir M, Kul A, Ozilhan S, Sagirli O. Determination of acamprosate in human plasma by UPLC-MS/MS: application to therapeutic drug monitoring. *Biomed Chromatogr.* **2020**;34(11):e4936. doi:10.1002/bmc.4936
25. Roberts JA, Abdul-Aziz MH, Lipman J, et al. Individualised antibiotic dosing for patients who are critically ill: challenges and potential solutions. *Lancet Infect Dis.* **2014**;14(6):498–509. doi:10.1016/s1473-3099(14)70036-2
26. Angelini J, Giuliano S, Flammini S, et al. Meropenem PK/PD variability and renal function: “we go together”. *Pharmaceutics.* **2023**;15(9):2238. doi:10.3390/pharmaceutics15092238
27. Johnston BD, Thuras P, Porter SB, Castanheira M, Johnson JR. Activity of meropenem/vaborbactam against international carbapenem-resistant *Escherichia coli* isolates in relation to clonal background, resistance genes, resistance to comparators and region. *J Glob Antimicrob Resist.* **2021**;24:190–197. doi:10.1016/j.jgar.2020.12.017
28. Kim HR, Eom YB. Synergistic activity of equol and meropenem against carbapenem-resistant *Escherichia coli*. *Antibiotics.* **2021**;10(2):161. doi:10.3390/antibiotics10020161
29. Slater J, Stilling M, Hanberg P, et al. Concentrations of co-administered meropenem and vancomycin in spinal tissues relevant for the treatment of pyogenic spondylodiscitis—an experimental microdialysis study. *Antibiotics.* **2023**;12(5):907. doi:10.3390/antibiotics12050907
30. Lazzeri E, Bozzao A, Cataldo MA, et al. Joint EANM/ESNR and ESCMID-endorsed consensus document for the diagnosis of spine infection (spondylodiscitis) in adults. *Eur J Nucl Med Mol Imaging.* **2019**;46(12):2464–2487. doi:10.1007/s00259-019-04393-6
31. Tali ET, Oner AY, Koc AM. Pyogenic spinal infections. *Neuroimaging Clin N Am.* **2015**;25(2):193–208. doi:10.1016/j.nic.2015.01.003

## Infection and Drug Resistance

### Publish your work in this journal

Infection and Drug Resistance is an international, peer-reviewed open-access journal that focuses on the optimal treatment of infection (bacterial, fungal and viral) and the development and institution of preventive strategies to minimize the development and spread of resistance. The journal is specifically concerned with the epidemiology of antibiotic resistance and the mechanisms of resistance development and diffusion in both hospitals and the community. The manuscript management system is completely online and includes a very quick and fair peer-review system, which is all easy to use. Visit <http://www.dovepress.com/testimonials.php> to read real quotes from published authors.

Submit your manuscript here: <https://www.dovepress.com/infection-and-drug-resistance-journal>

**Dovepress**  
Taylor & Francis Group